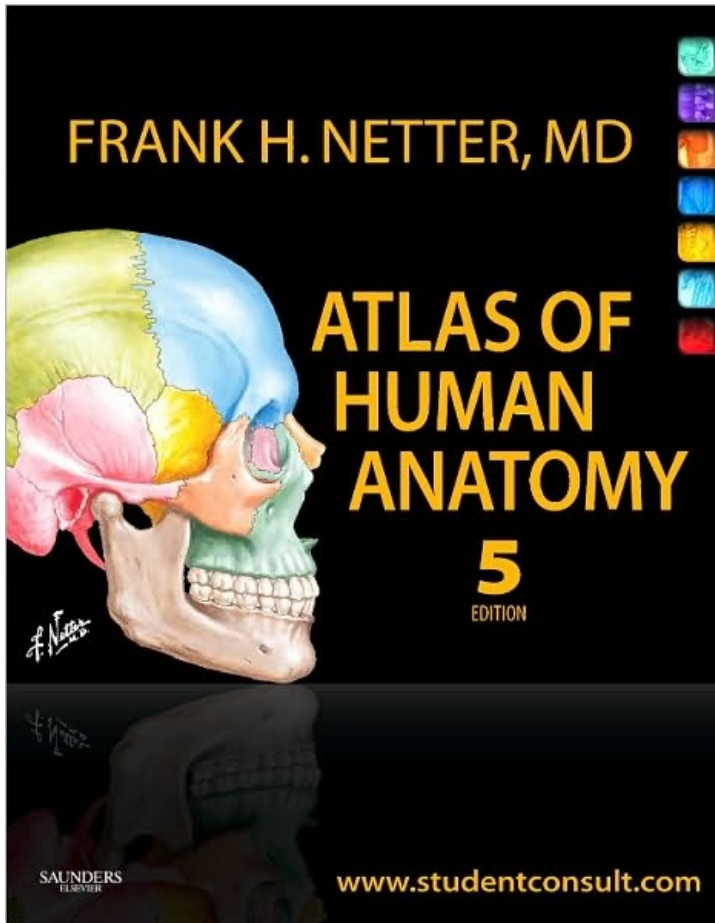

Head and Neck

page 1

1 Topographic Surface Anatomy

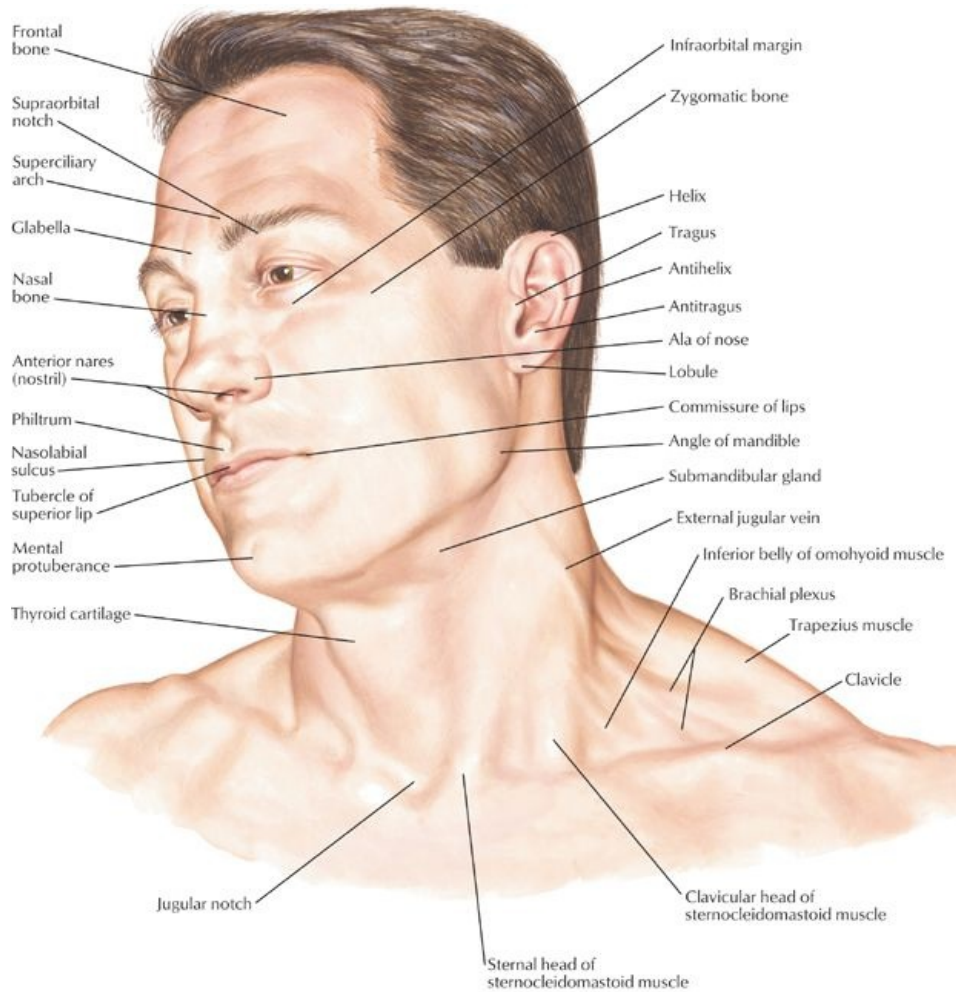
STUDY AIMS

At the end of your study, you should be able to:

- Identify the key landmarks in the midline of the neck and their significance
- State the structures that are situated at the level of C6
- Outline the boundaries of the triangles of the neck
- Describe the landmarks for palpation of the main arteries, which can be palpated in the face and neck
- Identify prominent features of the face

GUIDE

Head and Neck: Topographic Anatomy



[Plate 1, Head and Neck]

C. Machado

Key Landmarks Midline of Neck

page 1
page 2

There are a number of landmarks visible on the body's surface that correspond to deeper structures.

- Hyoid bone
 - Lies at level of C3 vertebra
 - U-shaped bone
 - Does not articulate with any other bone
 - Is suspended by muscles from
 - Mandible
 - Styloid processes of temporal bones
 - Thyroid cartilage
 - Manubrium of sternum
 - Scapulae
- Thyroid cartilage
 - Formed from anterior, midline fusion of two laminae plates = laryngeal prominence (Adam's apple)
 - Laminae diverge superiorly
 - Form V-shaped thyroid notch
 - Lie at the level of C4 vertebra
- C4 vertebral level
 - Bifurcation of common carotid artery into external and internal carotid arteries
 - Site of carotid sinus (baroreceptor) and carotid body (chemoreceptor)
- Carotid pulse can be palpated at anterior border sternocleidomastoid (level of C5 vertebra)
- Cricoid cartilage
 - Only complete ring cartilage in respiratory tract
 - Shaped like signet ring with band anteriorly
 - Lower border corresponds to level of C6 vertebra

- C6 vertebral level
 - Junction of larynx and trachea
 - Junction of pharynx and esophagus
 - Level at which inferior and middle thyroid arteries enter the thyroid gland
 - Vertebral artery (first branch subclavian artery) enters foramen transversarium of C6 transverse process to ascend to brain through successively higher foramina
 - Superior belly of omohyoid muscle crosses carotid sheath
 - Level of middle cervical sympathetic ganglion
 - Carotid artery can be compressed and palpated against transverse process C6
- Isthmus of thyroid gland overlies second and third tracheal cartilages
- Jugular (suprasternal) notch
 - Concave center of superior border of manubrium
 - Between medial ends of clavicles

Other Landmarks in the Neck

- Platysma
 - Thin, broad sheet of muscle within superficial fascia of the neck
 - A muscle of facial expression, tensing the skin
 - Draws corners of mouth down, as in a grimace, and depresses mandible
- External jugular vein
 - Deep to platysma, descends from angle to mandible to midpoint of clavicle
 - Useful for assessment of venous filling with patient sitting at 45 degrees
- Sternocleidomastoid (SCM)
 - Key landmark of neck
 - Divides neck into anterior and posterior triangles (*Section 1-4: Head and Neck - Neck*)
 - Sternal head attaches to manubrium of sternum
 - Clavicular head attaches to superior middle third of clavicle
 - Can be seen and palpated when acting unilaterally to flex and rotate head and neck to one side, so that ear approaches shoulder and chin turns in the opposite direction

Landmarks of the Face

- Glabella
 - Smooth midline prominence on the frontal bone
 - Located above the root of the nose, between supraorbital margins
- Zygomatic arch
 - Forms prominence of cheek
 - Can palpate superficial temporal artery at lateral end
 - Prone to fractures in facial trauma
- Mastoid process
 - Bony prominence behind external acoustic meatus
 - Site of proximal attachment sternocleidomastoid muscle
- Inion-prominent point of external occipital protuberance at back of head
- Auricle-part of external ear
 - Skin-covered cartilage, except for lobule
 - Features include: pinna; tragus; antitragus and helix
- External nose
 - Skeleton mainly cartilaginous
 - Dorsum extends from root to apex
 - Inferior surface has two openings or nares (nostrils)
 - Bounded laterally by alae of nose
 - Separated by skin over nasal septum
- Philtrum-midline infranasal depression of upper lip
- Masseter muscle
 - Felt over ramus of mandible when teeth are clenched
 - Parotid duct can be palpated at medial border (duct opens over second molar inside cheek)
- Temporalis muscle can be felt above zygomatic arch when teeth clenched
- Facial artery can be palpated over lower margin body of mandible in line with a point one fingerbreadth lateral to the angle of the mouth

FACTS & HINTS

High-Yield Facts

Clinical Points

Tracheostomy

- Transverse incision through skin of neck and anterior wall of trachea
- Method for achieving a definitive airway
- Transverse incision made through skin, at midpoint between suprasternal notch and thyroid cartilage
- Platysma and pretracheal fascia divided
- Strap muscles retracted
- Thyroid isthmus divided or retracted
- Opening made between first and second tracheal rings or through second through fourth tracheal rings
- Tracheostomy tube inserted

Clinical Points

Needle Cricothyrotomy

- Done in extreme emergency
- Performed if proximal airway is obstructed, to temporarily oxygenate the patient
- Large-bore needle inserted into the cricothyroid membrane and connected to an oxygen supply

Clinical Points

Central venous line

- Large veins such as the subclavian have relatively constant relationships to easily identifiable anatomic landmarks
- Placement of large-bore venous catheter in an emergent situation to deliver high flow of fluid or blood products
- Used for administration of chemotherapeutic agents, hyperalimentation fluids, and so on
- Used for assessing right heart (venous) pressures
- Vein located in an area bounded by the sternal and clavicular attachments of sternocleidomastoid and the clavicle-just deep to middle third of clavicle
- Subclavian vein is inferior and anterior to subclavian artery and separated from it by anterior scalene muscle

2 Bones and Ligaments

STUDY AIMS

At the end of your study, you should be able to:

- Describe the anatomic division of the head into a neuro- and viscerocranium
- Describe the function of the neuro- and viscerocranium
- Outline the bones that form the neurocranium
- Know the major sutures of the skull
- Describe the division of the base of skull into anterior, middle, and posterior cranial fossae and the contents of each
- List the foramina and key structures that pass through them
- Identify the prominent features of the mandible
- Describe the structure of the temporomandibular joint and the ligaments that stabilize it

GUIDE

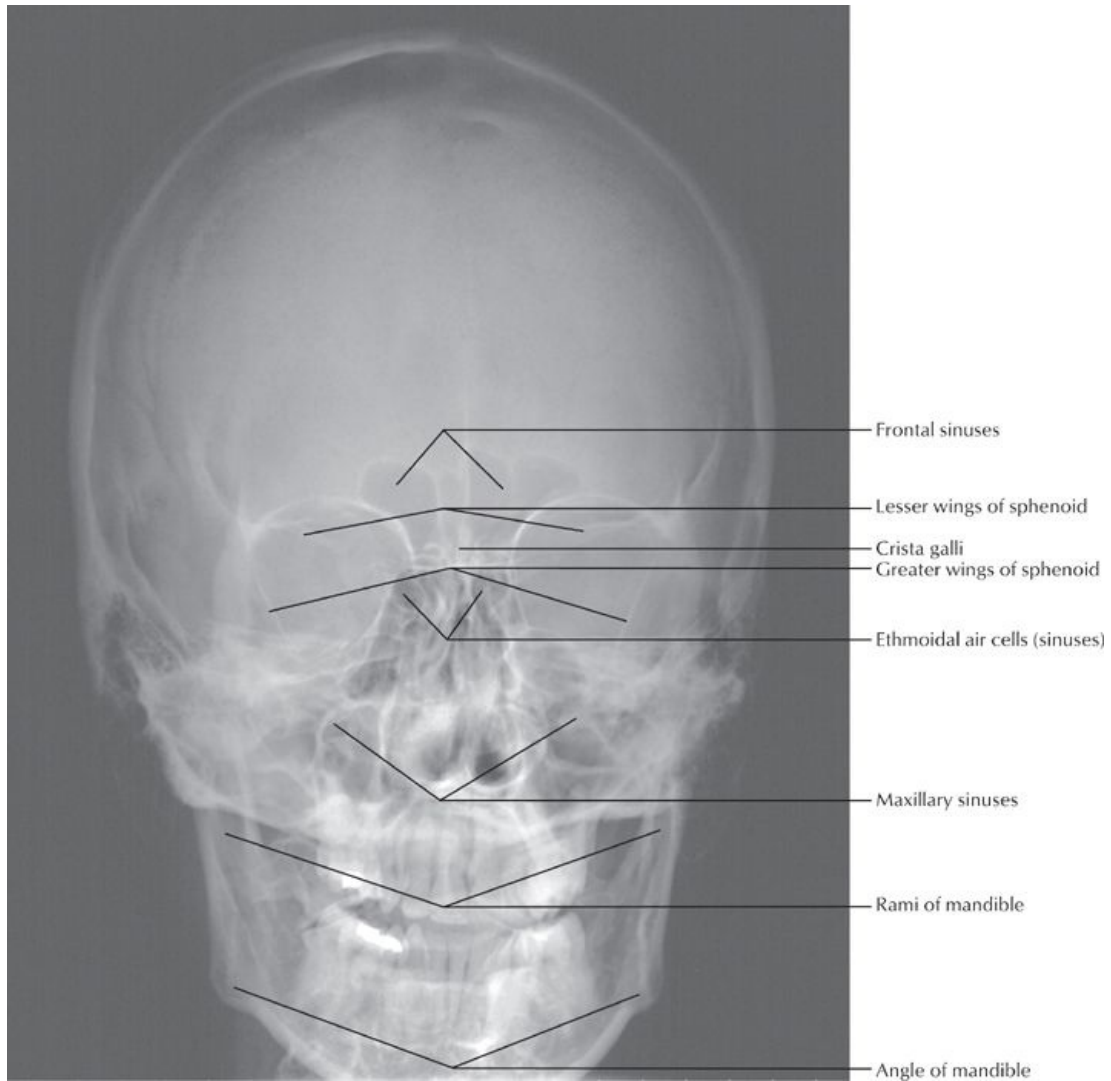
Head and Neck: Bones and Ligaments

Bones of head and neck

- Skull
- Mandible
- Cervical vertebrae

Skull

The skull is divided into the neurocranium or calvaria (contains the brain and its meningeal coverings) and the viscerocranium (facial skeleton). The skull is composed of 22 bones (excluding the middle ear ossicles), with 8 forming the cranium and 14 forming the face. The orbits (eye sockets) lie between the calvaria (skull cap) and the facial skeleton and are formed by contributions from 7 different bones.



[Plate 5 - Skull: Anteroposterior Radiograph]

Neurocranium		Viscerocranium	
Ethmoid	1	Zygomatic	2
Frontal	1	Vomer	1
Occipital	1	Inferior nasal concha	2
Sphenoid	1	Maxilla	2
Parietal	2	Nasal	2
Temporal	2	Palatine	2
		Lacrima	2
		(Mandible)	1
N=22	8	+	14

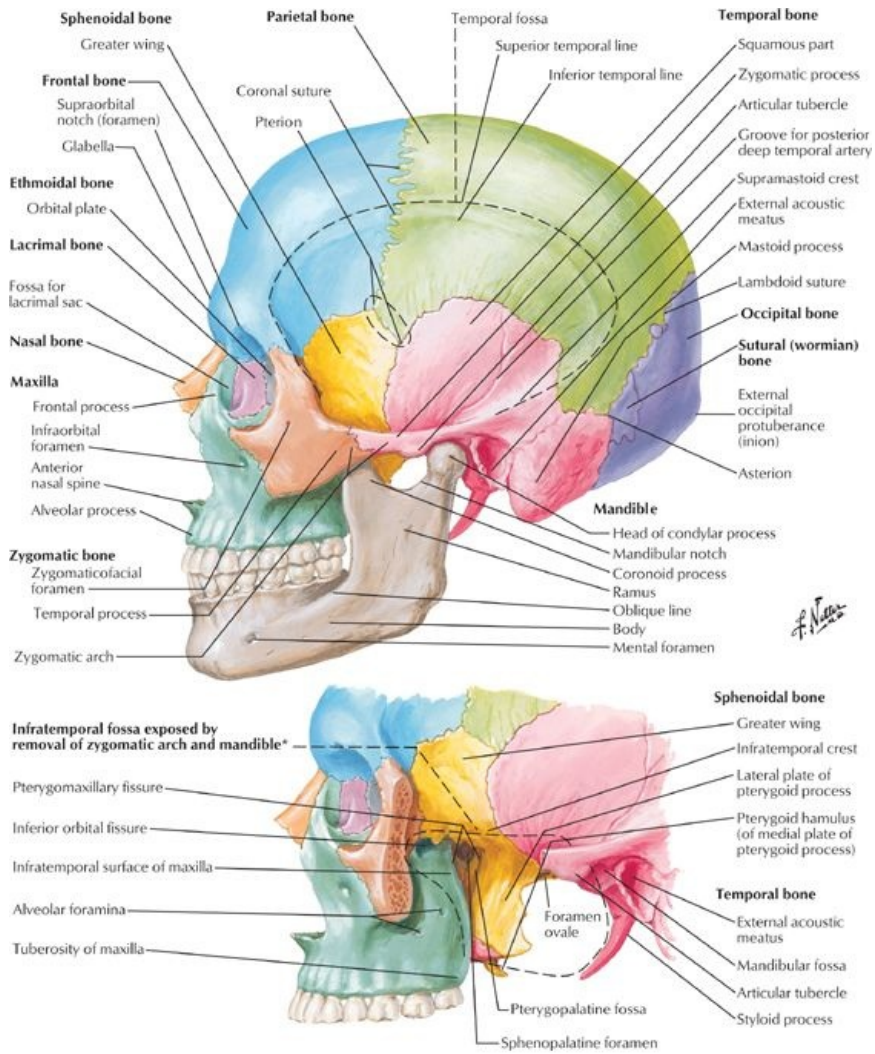
page 4
page 5

- Function of skull
 - Encloses, supports and protects brain and meninges
 - Contains foramina for the transmission of nerves and vessels
 - Forms foundation for the face
 - Contains specialized cavities and openings for sense organs (e.g., nasal, oral)
- Neurocranium
 - Cranial vault and base of skull
 - Encloses and protects brain
 - Composed of 8 bones
 - Bones united by interlocking sutures
 - Can be divided
 - Calvaria-dome-like roof
 - Cranial base
 - Calvaria composed of 4 bones
 - Frontal bone anteriorly
 - Occipital bone posteriorly
 - Two parietal bones laterally
 - Cranial base formed from
 - Ethmoid bone
 - Parts of occipital and temporal bones
- Viscerocranium
 - = facial skeleton
 - Composed of 14 bones
 - Encloses orbits, nose, paranasal sinuses, mouth, and pharynx
 - Maxillae and mandible form upper and lower jaw, respectively, and house the teeth
- There are also three auditory ossicles
 - Malleus, incus, and stapes
 - Found spanning tympanic cavity
 - First bones to be completely ossified during development

Major sutures of the skull

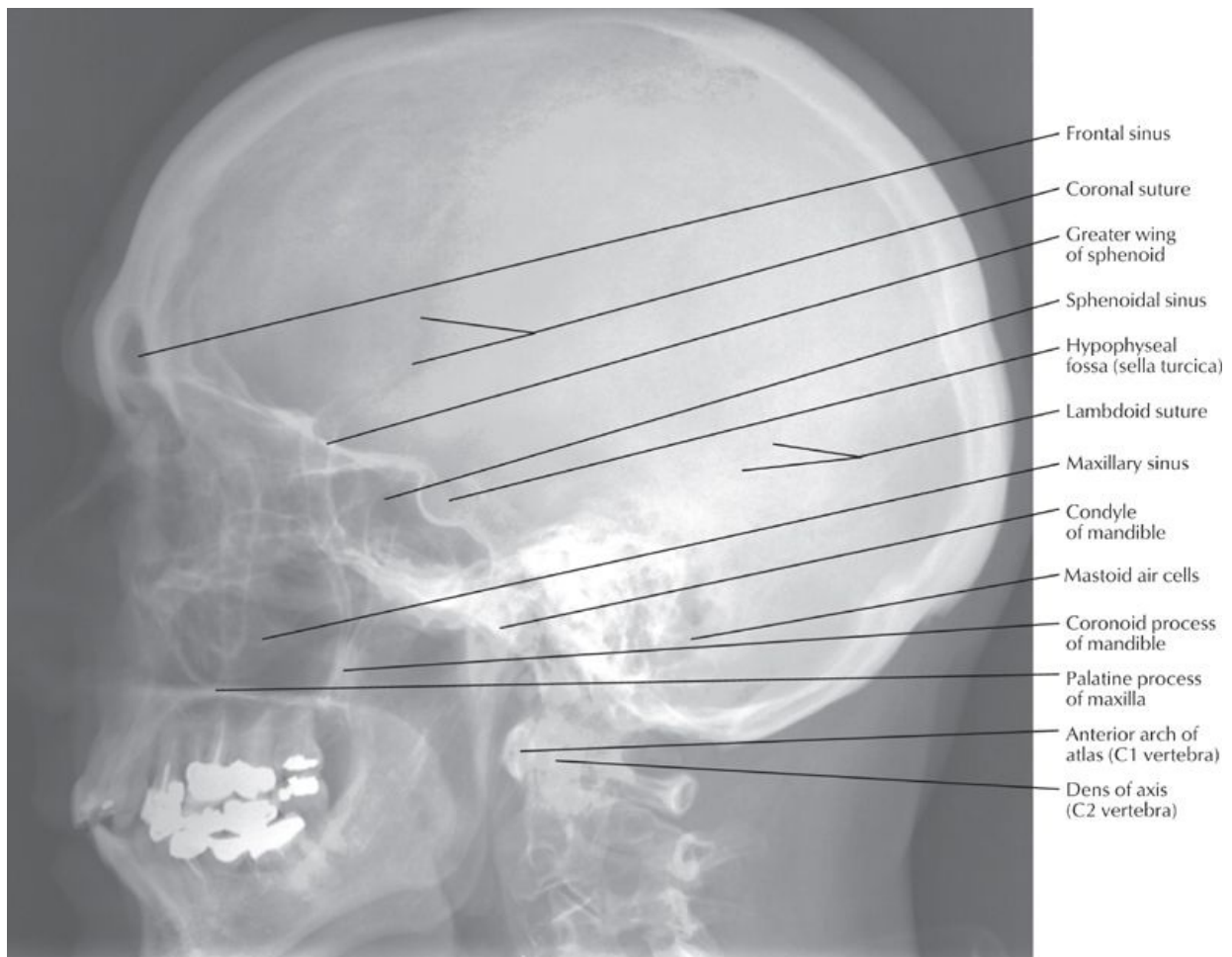
Most bones of the skull are bound by sutures, a type of fibrous joint that fuses with age and becomes immobile.

- Coronal suture separates frontal and parietal bones
- Sagittal suture separates two parietal bones
- Lambdoid suture separates parietal and temporal bones from occipital bones
- Squamous suture separates squamous part of temporal bone from parietal bone
- Sphenosquamous suture separates squamous part of temporal bone from greater wing of the sphenoid
- Metopic suture between two frontal bones is largely obliterated with fusion of frontal bones



*Superficially, mastoid process forms posterior boundary.

[Plate 6, Skull: Lateral View]



[Plate 7, Skull: Lateral Radiograph]

Internal Features of Base of Skull

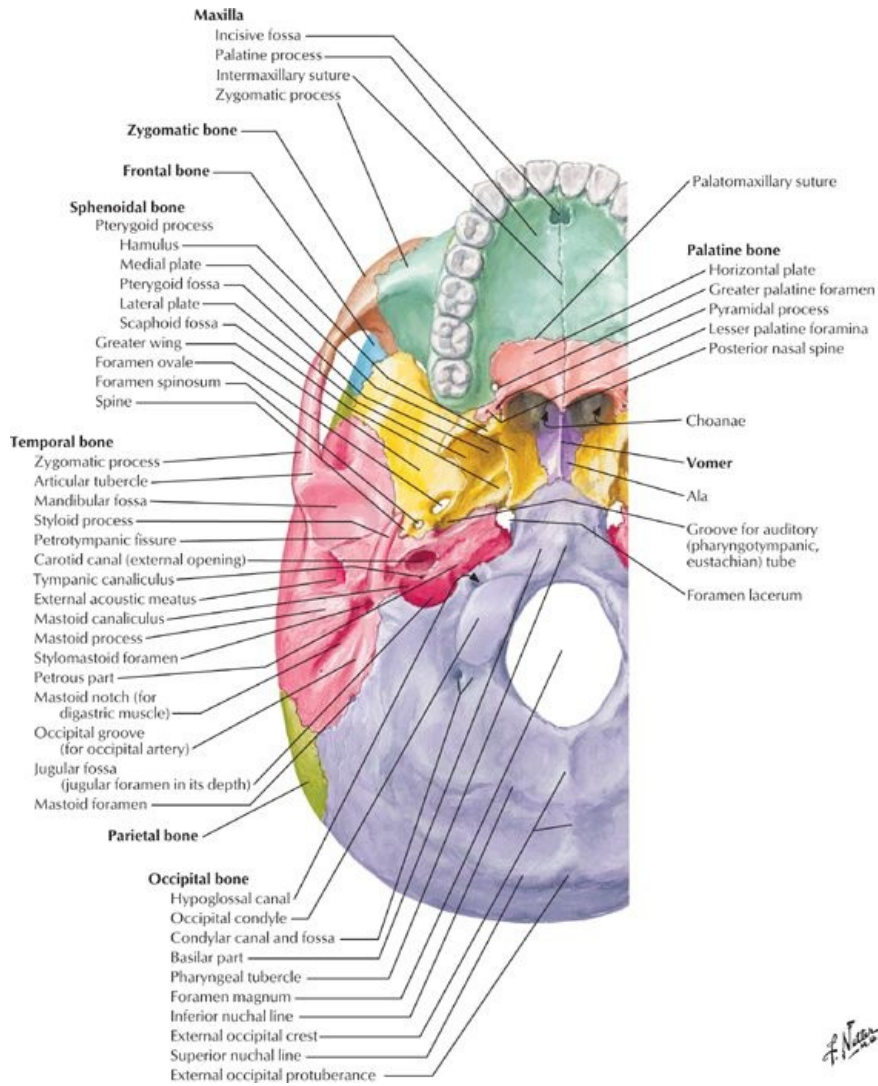
page 5
page 6

- Divided into anterior, middle, and posterior cranial fossae
- Anterior cranial fossa
 - Contains frontal lobe of brain
 - Formed by frontal bone anteriorly, ethmoid bone medially, and lesser wing of sphenoid posteriorly
 - Features
 - Frontal crest-midline bony extension of frontal bone
 - Foramen cecum-foramen at base of frontal crest
 - Crista galli-Midline ridge of bone from ethmoid posterior to foramen cecum
 - Cribriform plate-Thin, sieve-like plate of bone on either side of crista galli, which transmits olfactory nerves from nasal cavity to olfactory bulbs
- Middle cranial fossa
 - Contains temporal lobe, hypothalamus, and pituitary gland
 - Formed by greater wing and body of sphenoid, petrous temporal bone, lesser wing sphenoid
 - Features
 - Sella turcica-central depression in body of sphenoid for pituitary gland
 - Tuberculum sellae-Swelling anterior to sella turcica
 - Dorsum sellae-crest on body of sphenoid posterior to sella turcica
 - Anterior clinoid processes-medial projections of lesser wings of sphenoid bones
 - Posterior clinoid processes-swelling at either end of dorsum sellae
 - Foramen lacerum (one on each side)-jagged opening closed by plate of cartilage in life, transmits nothing
 - Contains four foramina in a crescent on either side in the body of the sphenoid
 - Superior orbital fissure
 - Foramen rotundum
 - Foramen ovale
 - Foramen spinosum
- Posterior cranial fossa:
 - Contains cerebellum, pons, and medulla oblongata
 - Composed largely of occipital bone, body of sphenoid, petrous, and mastoid parts of temporal bone
 - Features
 - Foramen magnum-transmits spinal cord
 - Internal occipital crest-divides posterior fossa into two lateral cerebellar fossae
 - Grooves for transverse and sigmoid dural venous sinuses
 - Jugular foramen-transmits sigmoid sinus (internal jugular vein) and several cranial nerves

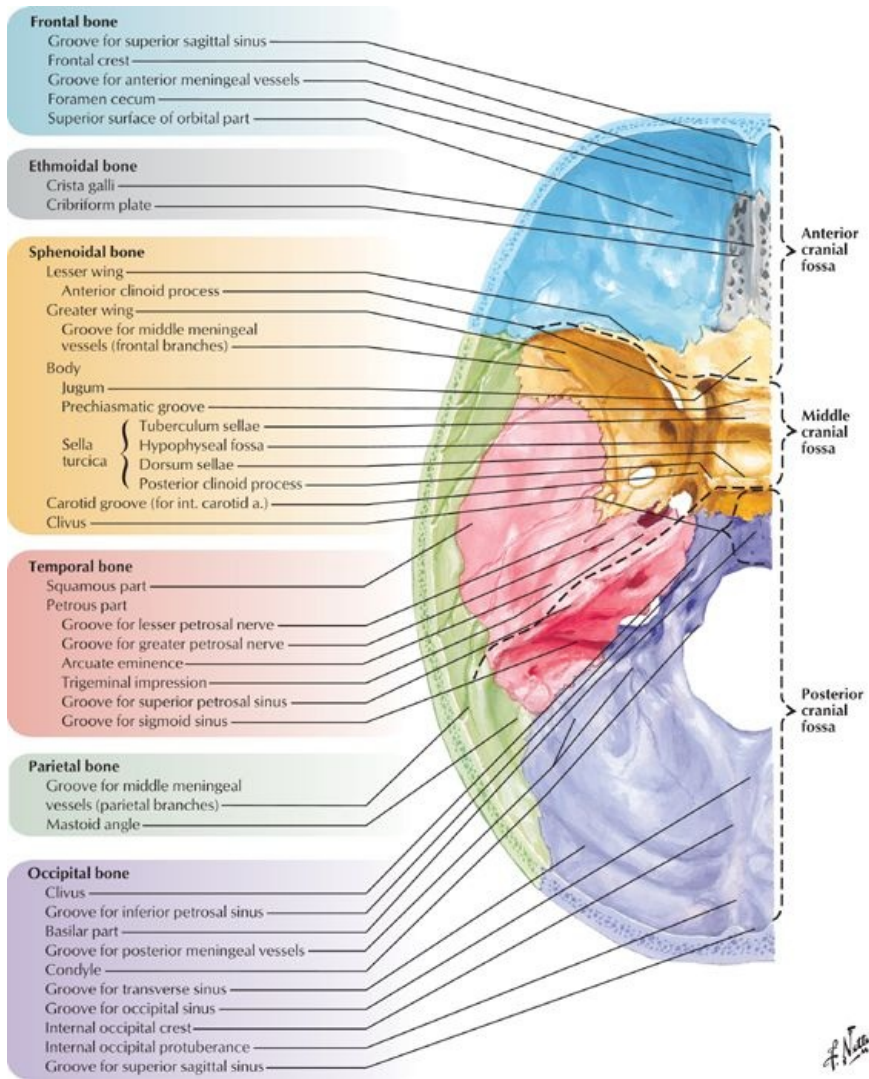
- Internal acoustic meatus-anterior and superior to jugular foramen, transmits facial and vestibulocochlear nerves (CN VII and CN VIII)
- Hypoglossal canal-anterolateral and superior to foramen magnum, transmits hypoglossal nerve (CN XII)

Foramina of Skull

Numerous holes appear in the cranial floor and they are called foramina. Important structures, especially cranial nerves arising from the brain, pass through the foramen to access the exterior.



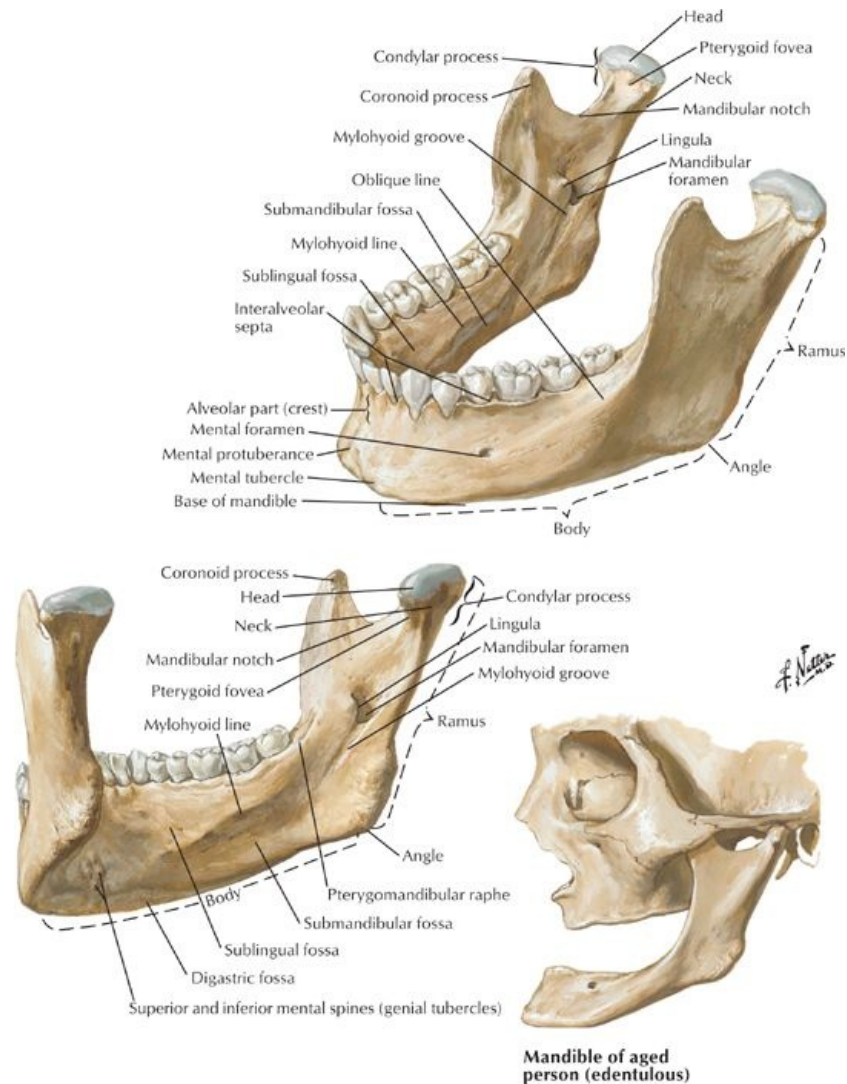
[Plate 10, Cranial Base: Inferior View]



[Plate 11, Cranial Base: Superior View]

Foramen/Opening	Bone	Structures Transmitted
Optic canal	Lesser wing sphenoid	Optic nerve Ophthalmic artery Sympathetic plexus
Superior orbital fissure	Greater and lesser wings sphenoid	Lacrimal nerve (V ₁) Frontal nerve (V ₁) Trochlear nerve (IV) Oculomotor nerve (III) Abducent nerve (VI) Nasociliary nerve (V ₁) Superior ophthalmic vein
Inferior orbital fissure	Between greater wing of sphenoid and zygomatic	Infraorbital vein Infraorbital artery Infraorbital nerve
Foramen spinosum	Greater wing of sphenoid	Middle meningeal artery and vein
Foramen rotundum	Greater wing of sphenoid	Maxillary division trigeminal nerve (V ₃)
Foramen ovale	Greater wing of sphenoid	Mandibular division trigeminal nerve Lesser petrosal nerve
Foramen lacerum	Between temporal bone (petrous area) and sphenoid bone	Internal carotid artery
Foramen magnum	Occipital bone	Medulla oblongata Vertebral artery Meninges Spinal roots of accessory nerve
Hypoglossal canal	Occipital bone	Hypoglossal nerve (XII)
Jugular foramen	Between temporal bone (petrous area) and occipital bone	Glossopharyngeal nerve (IX) Vagus nerve (X) Accessory nerve (XI) Inferior petrosal sinus Sigmoid sinus

Mandible



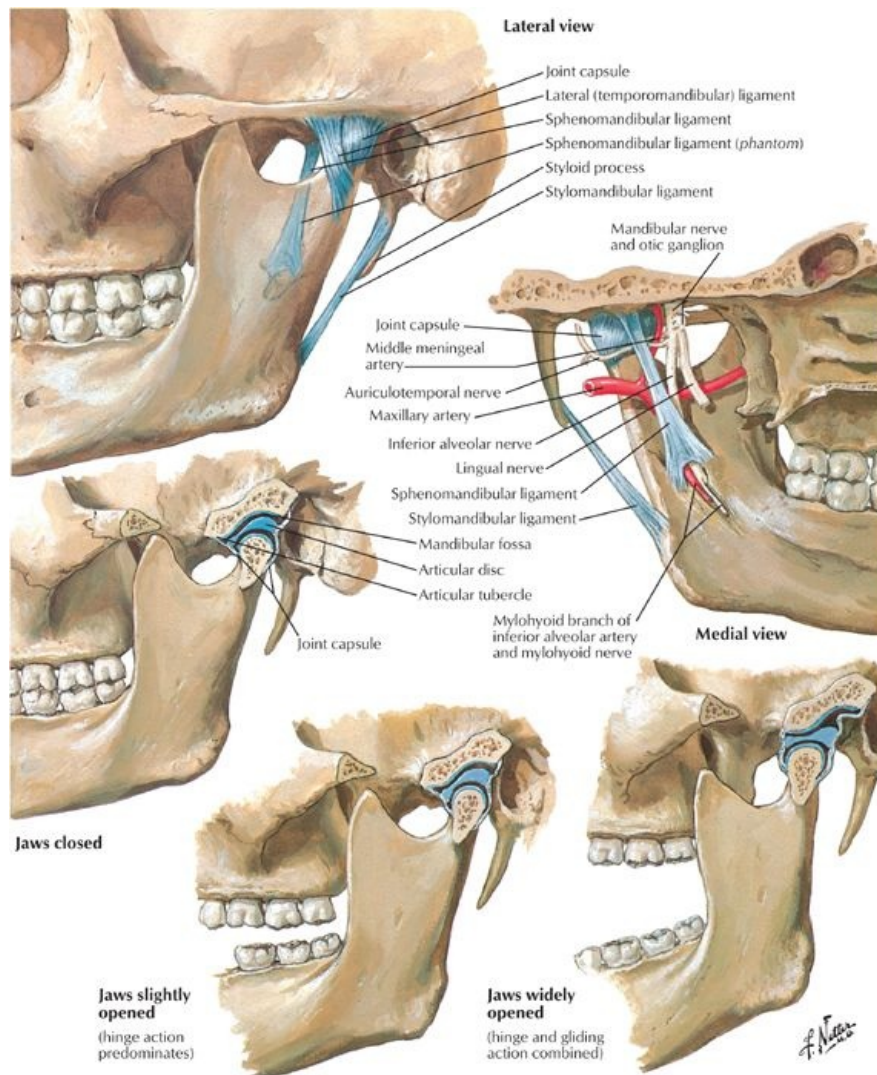
[Plate 17, Mandible]

Mandible of aged person (edentulous)

page 7
page 8

- Unpaired bone of lower jaw
- Largest and strongest bone in face
- Articulates with temporal bone at temporomandibular joint
- Consists of
 - Body
 - Can be divided into lower base and upper alveolar part
 - Has a mental protuberance anteriorly and inferiorly where two sides come together
 - Mental spine: rough projection on inner surface of body in the midline
 - Mental foramen below second premolar transmits terminal branch of inferior alveolar nerve to supply skin and mucus membrane of lower lip and chin
 - Mylohyoid line: a ridge extending upward and backward on internal surface of alveolar part of mandible for attachment mylohyoid muscle
 - Submandibular fossa: long depression below mylohyoid line, which accommodates submandibular gland
 - Sublingual fossa: concavities on either side of mental spine for sublingual gland
 - Rami
 - Lateral vertical projections from body
 - Each meets body inferiorly at angle of the jaw
 - Two processes at superior end: coronoid process and condylar process
 - Coronoid process-attachment of temporalis muscle
 - Condylar process-part of temporomandibular joint
 - Mandibular notch-concavity between condylar and coronoid processes
 - Mandibular foramen
 - On inner surface of ramus
 - Entrance to mandibular canal, through which passes the inferior alveolar nerve
 - Lingula-thin projection of bone overlapping mandibular foramen
 - Mylohyoid groove-groove leading anteriorly and inferiorly from mandibular foramen indicating course of mylohyoid nerve and vessels

Temporomandibular Joint



[Plate 18, Temporomandibular Joint]

The mandible articulates with the temporal bone and in chewing or speaking, it is only the mandible or lower jaw that moves; the upper jaw or maxilla remains stationary. The teeth are contained in the alveolar portion of the mandible.

- Articulation between condylar process of mandible, articular tubercle of temporal bone, and mandibular fossa
- Modified hinge-type synovial joint
- Contains fibrocartilaginous disc, which divides joint cavity into two compartments
 - Gliding movements (protrusion and retrusion/retraction) occur in upper compartment
 - Hinge movements (depression and elevation) occur in lower compartment
- Stabilized by three ligaments:
 - Lateral temporomandibular ligament
 - Lateral thickened parts of articular capsule
 - Prevent posterior dislocation of joint
 - Sphenomandibular ligament
 - Primary passive support
 - Runs from spine of sphenoid to lingual of mandible
 - Serves as swinging hinge and check ligament
 - Stylomandibular ligament
 - Thickening in capsule of parotid gland
 - Runs from styloid process to angle of mandible
- Movements
 - Depression-suprahyoid and infrahyoid muscles, gravity
 - Elevation-temporalis, masseter, and medial pterygoid muscles
 - Protrusion-lateral pterygoid, masseter, medial pterygoid
 - Retraction/retraction-temporalis, masseter
 - Side to side grinding-retractors of same side, protruders of opposite side

Cervical vertebrae

See: Back and Spinal Cord-Bones and Ligaments

FACTS & HINTS

High-Yield Facts

Anatomic Points

- Newborn's skull is large compared to other parts of the skeleton
- Facial skeleton small compared to calvaria
- Two halves of mandible begin to fuse during first year
- The mastoid process is not present at birth but develops in the first 2 years of life
- The anterior fontanelle:
 - A diamond-shaped region covered by a fibrous membrane
 - Lies at juncture of both frontal with both parietal bones
 - Ossifies by 18 months
 - Useful for assessing hydration and measuring heart rate and intracranial pressure
- Enlargement of frontal and facial regions associated with increasing size of paranasal sinuses
- Vertical growth of face because of dental development
- Thinnest part of skull is pterion:
 - Where parietal bone articulates with greater wing of sphenoid.
 - Fractures can cause intracranial bleeding as pterion overlies anterior division of middle meningeal artery and vein.

Clinical Points

Skull (Calvaria) Fractures

- Can occur as a result of direct trauma to the head
- Can be one of several types:
 - Depressed
 - Produced by hard blows in regions where calvaria is thin
 - Fragment of bone forced inward into brain
 - Linear
 - Most frequent
 - Fracture lines radiate away from point of impact
 - Comminuted - bone broken into several pieces
 - Contre-coup
 - Maybe no fracture at impact site
 - Brain impacts opposite side of skull and rebounds to site of impact, with resulting bruising
- May be associated with brain injury
- When assessing a patient with a head injury the Glasgow Coma Scale (GCS) is useful..

page 9
page 10

Clinical Points

- **Le Fort Fractures**
- Common variants of fractures of the maxillae, naso-orbital complex, zygomatic bones (midface fractures) were classified by Le Fort (surgeon and gynecologist)
- Le Fort I:
 - Horizontal fracture of one or both maxillae at the level of the nasal floor.
 - May present with crepitus on palpation and epistaxis
 - Rarely compromises airway.
- Le Fort II:
 - Pyramidal-shaped fracture that includes horizontal fracture of both maxillae, extending superiorly through maxillary sinuses, infraorbital foramina, and ethmoids to bridge of nose.
 - Separates central face from rest of skull
 - Places the airway at risk
- Le Fort III:
 - Includes fractures of Le Fort II plus horizontal fracture through superior orbital fissures, ethmoid, and nasal bones, great wings of sphenoid bones and zygomatic bones.
 - Maxillae and zygomatic bones separate from skull
 - May cause airway problems, nasolacrimal apparatus obstruction, and cerebrospinal fluid (CSF) leakage

Mnemonics

Memory Aids

Cranial/Orbital Bones:	Occipital; Parietal; Frontal; Temporal; Ethmoid; Sphenoid	
	Old People From Texas Eat Spiders	
Cranial Sutures:	Sutures have CLASS	
	C	Coronal
	L	Lambdoid
	a	And
	S	Squamous
	S	Sagittal.

Memory Aids

"Con Man Facial Bones: Max and Pal Ziggy Lack Nasty Voices"		
Con	=	Conchae
Man	=	Mandible
Max	=	Maxilla
Pal	=	Palatine
Ziggy	=	Zygomatic
Lack	=	Lacrimal
Nasty	=	Nasal
Voices	=	Vomer
Fontanels (Infant Skull):		Ababy's first words might be "PAPA!"
	P	P osterior
	A	A nterior
	P	P osterolateral
	A	A nterolateral

3 Superficial Face

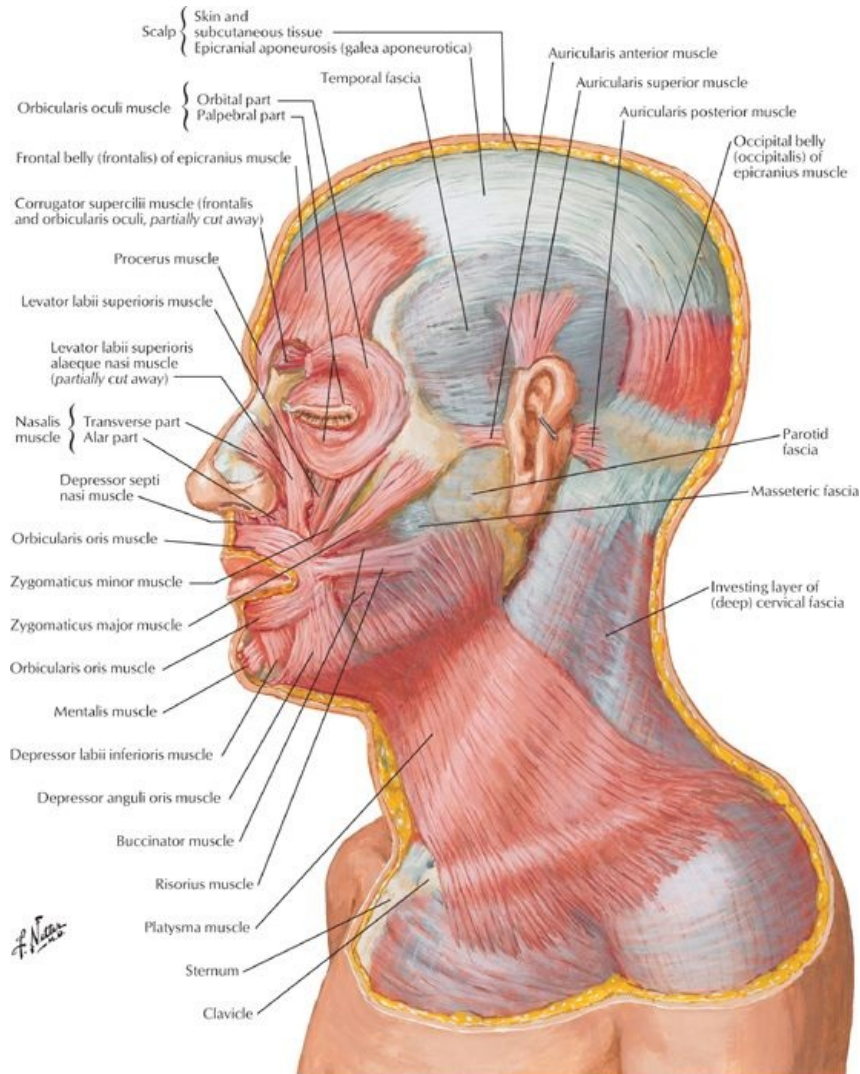
STUDY AIMS

At the end of your study, you should be able to:

- Outline the main muscles of facial expression and their actions
- Know the layers of the scalp, its innervation and vascular supply
- Understand the vascular supply and lymphatic drainage of the face
- Know the sensory and motor innervation of the face
- Outline the main muscles of mastication and their actions

GUIDE

Head and Neck: Superficial Face



[Plate 25, Muscles of Facial Expression: Lateral View]

Face

page 12
page 13

- Subcutaneous tissue of face
 - Contains muscles of facial expression
 - Contains varying amount of fat-for example, buccal fat pads of the cheek
 - Highly vascular
 - Contains sensory branches of trigeminal (V) nerve, upper cervical spinal nerves and motor branches of the facial nerve (VII)
 - Traversed by skin ligaments (retinacula cutis)
 - Bands of connective tissue
 - Connect skin to bones
- Muscles of facial expression

The muscles of facial expression are in several ways unique among the skeletal muscles of the body. They all originate embryologically from the second pharyngeal arch and are all innervated by terminal branches of the facial nerve (cranial nerve [CN] VII). Additionally, most arise from the bones of the face or fascia, and insert into the dermis of the skin overlying the scalp, face, and anterolateral neck.

 - Lie within superficial fascia
 - Most arise from bone and insert into skin
 - Arranged as sphincters or dilators around orifices of face
 - Innervated by one of five main branches of facial nerve (occipitalis innervated by posterior auricular branch)
- Muscles related to the orbit
 - Orbicularis oculi
 - Composed of three parts: lacrimal, palpebral, orbital
 - Lacrimal part draws eyelids and lacrimal puncta medially to drain tears
 - Inner palpebral part gently closes eyelids (blinking)
 - Outer orbital part that tightly closes eyelids (squinting)
 - Corrugator supercilii
 - Draws medial end of eyebrow medially and inferiorly for a concerned look

- Wrinkles skin of forehead
 - Frontalis portion of occipitofrontalis
 - Elevates the eyebrows for a surprised look
 - Wrinkles the forehead
- Muscles related to the nose
 - Nasalis
 - Consists of compressor naris-compresses nostril
 - And dilator naris-flares nostrils
 - Procerus
 - From forehead over bridge of nose
 - Draws medial eyebrow inferiorly
 - Creates transverse wrinkles over nose-frowning
- Muscles related to the ear
 - Anterior, superior, and posterior auricular
 - Variably developed
- Muscles related to mouth and lips
 - Orbicularis oris
 - Sphincter of the mouth
 - Important for speech, holding food between the teeth, whistling, blowing
 - Levator labii superioris alaeque nasi
 - Elevates nose and upper lip
 - Mentalis
 - Wrinkles skin on chin
 - Buccinator
 - Involved in smiling
 - Holds food between teeth during chewing
 - Used in whistling, sucking, and horn blowing
 - Depressor anguli oris
 - Depresses angle of mouth
 - Levator anguli oris
 - Elevates corner of mouth
 - Levator labii superioris
 - Lifts and everts upper lip
 - Depressor labii inferioris
 - Draws lip down and laterally
 - Used to show impatience
 - Risorius
 - Draws corner of mouth laterally
 - Used in grinning
 - Zygomaticus major
 - Draws angle of mouth up and laterally
 - Used in smiling and laughing
 - Zygomaticus minor
 - Raises upper lip as when showing contempt
 - Platysma
 - Depresses mandible
 - Draws corners of mouth down
 - Used when grimacing

Scalp

page 13
page 14

- Extends from superior nuchal line to superior orbital ridge
- Laterally extends to external acoustic meatus and zygomatic arch
- Composed of five layers
 - First three are adherent to skull, move as one
 - Skin (1)
 - Contains sweat and sebaceous glands and hair follicles
 - Well vascularized
 - Connective Tissue (2)
 - Dense
 - Well vascularized and innervated
 - Aponeurosis of occipitofrontalis muscle (3)
 - Tendinous sheet
 - Connects occipitalis, frontalis and superior auricular muscles
 - Loose connective tissue (4)
 - Spongy
 - Layer that collects fluid from injury of infection
 - Moves freely with first three layers over pericranium
 - Periosteum of skull (5)
 - External periosteum of calvaria
 - Fairly firmly attached to bone
 - Most tightly bound at suture lines
- Vasculature of scalp
 - Scalp has rich blood supply, so bleeding from a scalp injury is profuse
 - Arteries anastomoses
 - Branches of external carotid artery to scalp

- Posterior auricular
 - Occipital
 - Superficial temporal
 - Branches of internal carotid artery to scalp
 - Supratrochlear artery
 - Supraorbital artery
 - Venous drainage of scalp via veins of same name accompanying arteries
 - Deep aspects of scalp drain to deep temporal veins to pterygoid venous plexus
- Innervation of scalp
 - Anterior to auricle: ophthalmic, maxillary and mandibular divisions of cranial nerve (CN) V (trigeminal)
 - Posterior to auricle: cutaneous branches from C2 and C3 spinal nerves

Vascular supply of the face

- Arteries
 - Facial artery
 - Major arterial source for face
 - Arises from external carotid artery, crosses mandible and traverses face to medial angle of eye
 - Branches to upper and lower lip and nose
 - Superficial temporal artery
 - Terminal branch of external carotid
 - Enters temporal fossa and ends in scalp
 - Transverse facial artery
 - From superficial temporal
 - Crosses face below zygomatic arch
- Veins
 - Supratrochlear vein
 - Descends from forehead to nose
 - Joins supraorbital to form angular vein
 - Supraorbital vein
 - Begins in forehead and passes medially to join supratrochlear vein
 - Sends branch through supraorbital notch to join superior ophthalmic vein
 - Facial vein
 - Two veins provide main venous drainage of face
 - Follow course of facial artery
 - Drain directly or indirectly into internal jugular vein
 - Communicates with pterygoid venous plexus and cavernous sinus via superior ophthalmic vein
 - Superficial temporal vein
 - Drains scalp and forehead
 - Unites with maxillary vein to form retromandibular vein
 - Retromandibular vein
 - Descends through parotid gland
 - Sends branch to facial vein
 - Joins posterior auricular vein to form external jugular vein

page 14
page 15

Lymphatic drainage of the face

- Superficial lymphatics travel with veins
- Deep lymphatics travel with arteries
- Lateral face → parotid lymph nodes
- Upper lip and lateral lower lip → submandibular lymph nodes
- Chin and central part of lower lip → submental lymph nodes
- All lymphatic drainage eventually reaches the deep cervical lymph nodes

Innervation of the face

- Cutaneous branches of the cervical nerves
 - From the cervical plexus
 - Innervate posterior neck, ear, and area over parotid gland
- Trigeminal nerve (CN V)
 - Sensory for the face
 - Motor for muscles of mastication
 - Branches of ophthalmic nerve-CN V₁
 - Nasociliary nerve → external nasal nerve to skin on dorsum of nose
 - Nasociliary nerve → infratrochlear nerve to skin and lower eyelid
 - Frontal nerve → supratrochlear nerve to skin in midforehead
 - Frontal nerve → supraorbital nerve to skin of forehead and upper eyelid
 - Branches of maxillary nerve-CN V₂
 - Infraorbital nerve to skin of cheek, lower lid, lateral nose and mouth, upper lip
 - Zygomaticotemporal nerve to skin over anterior temple
 - Zygomaticofacial nerve to skin over zygomatic arch
 - Branches of mandibular nerve-CN V₃
 - Auriculotemporal nerve-to skin of external ear, posterior temple, anterior to ear
 - Buccal nerve-to skin of cheek

- Mental nerve-to skin of chin and lower lip
- Facial nerve
 - Sole motor supply to muscles of facial expression
 - Has five main branches
 - Temporal
 - Zygomatic
 - Buccal
 - Mandibular
 - Cervical
 - Names refer to areas they supply

Other muscles associated with the face: Muscles of mastication

The muscles of mastication include four pairs of muscles (left and right side) that attach to the mandible, are embryological derivatives of the first pharyngeal arch, are all innervated by the mandibular division of the trigeminal nerve (CN V₃), and are important in biting and chewing food.

- All attach to mandible
- Responsible for biting and chewing (movements at the temporomandibular joint [TMJ])
- All innervated by branches of the mandibular nerve (CN V₃)
- All supplied by branches of the maxillary artery
- Group of four muscles
 - Temporalis
 - Large, fan-shaped
 - Covers most of the side of the head
 - Inserts on coronoid process of mandible
 - Masseter
 - Deep to parotid gland and crossed by parotid duct
 - Inserts on entire lateral surface of ramus of mandible except for condylar process
 - Lateral pterygoid
 - Deep to temporal muscle
 - Runs horizontally backwards from infratemporal fossa and lateral pterygoid plate to insert on mandible
 - Covered with dense pterygoid plexus of veins
 - Medial pterygoid
 - Covered by inferior fibers of lateral pterygoid
 - Runs from inner surface of lateral pterygoid plate inferiorly to inner surface of ramus of mandible

Muscle	Origin	Insertion	Main Actions	Nerve Supply	Blood Supply
Temporalis	Floor of temporal fossa and deep temporal fascia	Coronoid process and ramus of mandible	Elevates mandible; posterior fibers retrace mandible	Mandibular nerve (V ₃)-deep temporal nerves	Superficial temporal and maxillary arteries, middle, anterior, and posterior deep temporal arteries
Masseter	Zygomatic arch	Ramus of mandible and coronoid process	Elevates and protrudes mandible; deep fibers retrace it	Mandibular nerve (V ₃)-masseteric nerve	Transverses facial artery, masseteric branch of maxillary and facial arteries
Medial pterygoid	<i>Superior head:</i> infratemporal surface of greater wing of sphenoid <i>Inferior head:</i> lateral pterygoid plate	Neck of mandible, articular disc, and capsule of TMJ	Acting together, protrude mandible and depress chin; acting alone and alternately, produces side-to-side movements	Mandibular nerve (V ₃)-nerve to medial pterygoid	Facial and maxillary arteries
Lateral pterygoid	Infratemporal surface of greater wing of sphenoid and lateral surface of lateral plate of pterygoid plate	Pterygoid fovea, capsule of TMJ and articular disk	Together, protrude mandible, depress chin Alone and alternately, side to side grinding	Mandibular nerve (V ₃)-muscular branches from anterior division	Maxillary artery-muscular branches

FACTS & HINTS

High-Yield Facts

Clinical Points

Scalp lacerations

- Scalp has rich blood supply
- Bleeding from scalp lacerations often profuse, because blood enters periphery of scalp and vessels anastomose
- Because of dense connective tissue in second layer of scalp, bleeding vessels do not retract into wound but stay open
- Patient can exsanguinate if bleeding is not controlled
- Bleeding controlled initially by direct pressure initially followed by suturing in layers rather than tying individual vessels

Clinical Points

Blood or infections in the scalp

- Blood or pus from an infection collects in loose connective tissue
- Can spread easily
- Prevented from passing into the neck or subtemporal regions, because of attachments of the epicranial aponeurosis
- Fluid can descend into orbits because orbitalis muscle attaches to skin in this region
- Orbital hematomas commonly occur following injury to the scalp

Clinical Points

Facial palsy (Bell's palsy)

- Facial nerve palsy without a known cause
- Can follow exposure to cold, dental work, Lyme disease, or otitis media
- Results in inflammation, compression, or edema of the nerve
- Facial nerve supplies muscles of facial expression
- Thus result is loss of facial muscle tone on the affected side
- Symptoms generally seen:
 - Paralysis orbicularis oris causes drooping of mouth on affected side and dribbling of saliva
 - Paralysis of orbicularis oculi causes eyelid to droop and evert, leaving cornea inadequately lubricated and eye constantly tearing
 - Paralysis of buccinator together with orbicularis oris leads to accumulation of food between cheek and teeth when chewing

page 17
page 18

Clinical Points

Table 100-2. Sites of lesions of the facial nerve and resulting symptoms

Site of Lesion	Symptoms
Below stylomastoid foramen (parotid gland tumor, trauma)	1) Facial paralysis (mouth draws to opposite side; on affected side, patient unable to close eye or wrinkle forehead; food collects between teeth and cheek as a result of paralysis of buccinator muscle.
Facial canal	2) All symptoms of (1), plus loss of taste in anterior tongue and decreased salivation on affected side as a result of chorda tympani involvement. Hyperacusis as a result of effect on nerve branch to stapedius muscle.
Geniculate ganglion	3) All symptoms of (1) and (2), plus pain behind ear. Herpes of tympanum and of external auditory meatus may occur
Intracranial and/or internal auditory meatus	4) All symptoms of (1-3), plus deafness as a result of involvement of eighth cranial nerve

Mnemonics

Memory Aids

Layers of scalp:	SCALP
	Skin
	Connective Tissue
	Aponeurosis
	Loose connective tissue
	Periosteum of skull

Memory Aids

Branches Facial Nerve:	"To Zanzibar By Motor Car"
	Temporal
	Zygomatic
	Buccal
	Mandibular
	Cervical

Memory Aids

Four muscles of mastication:	MTPP (<i>which can be read as "Empty Peepee"</i>)
	M asseter
	T emporal
	lateral P terygoids
	medial P terygoids

4 Neck

STUDY AIMS

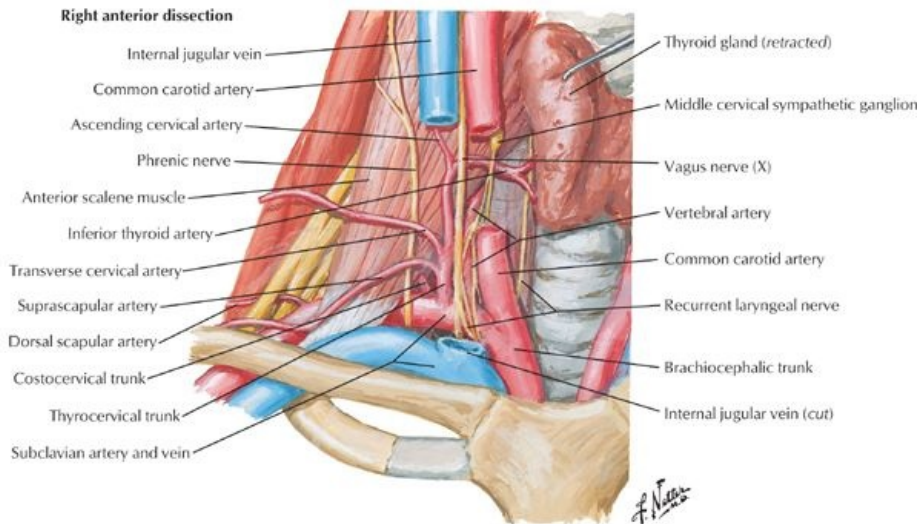
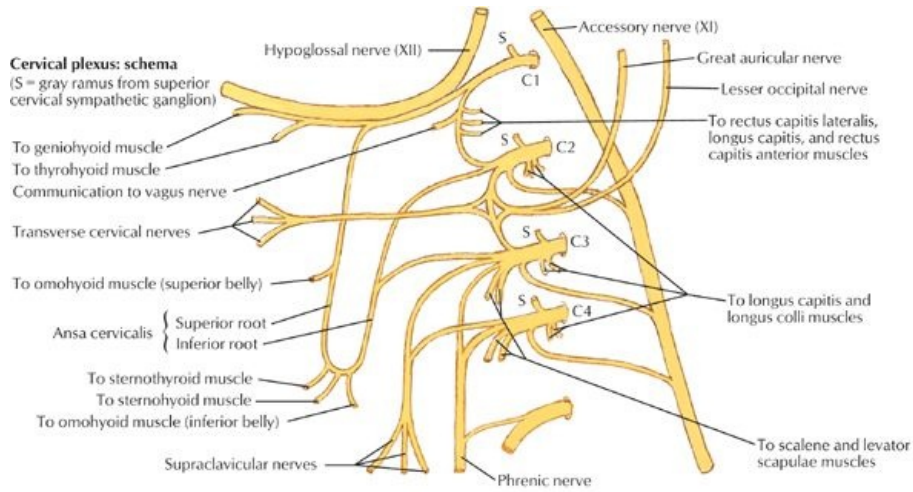
At the end of your study, you should be able to:

- Outline the gross structure of the neck
- Describe the anterior and posterior triangles of the neck: boundaries and contents
- Know the smaller triangles of the neck within the posterior and anterior triangles: boundaries and content
- Know the fascial layers of the neck
- Know the contents of the compartments the fascial layers create

GUIDE

Head and Neck: Neck

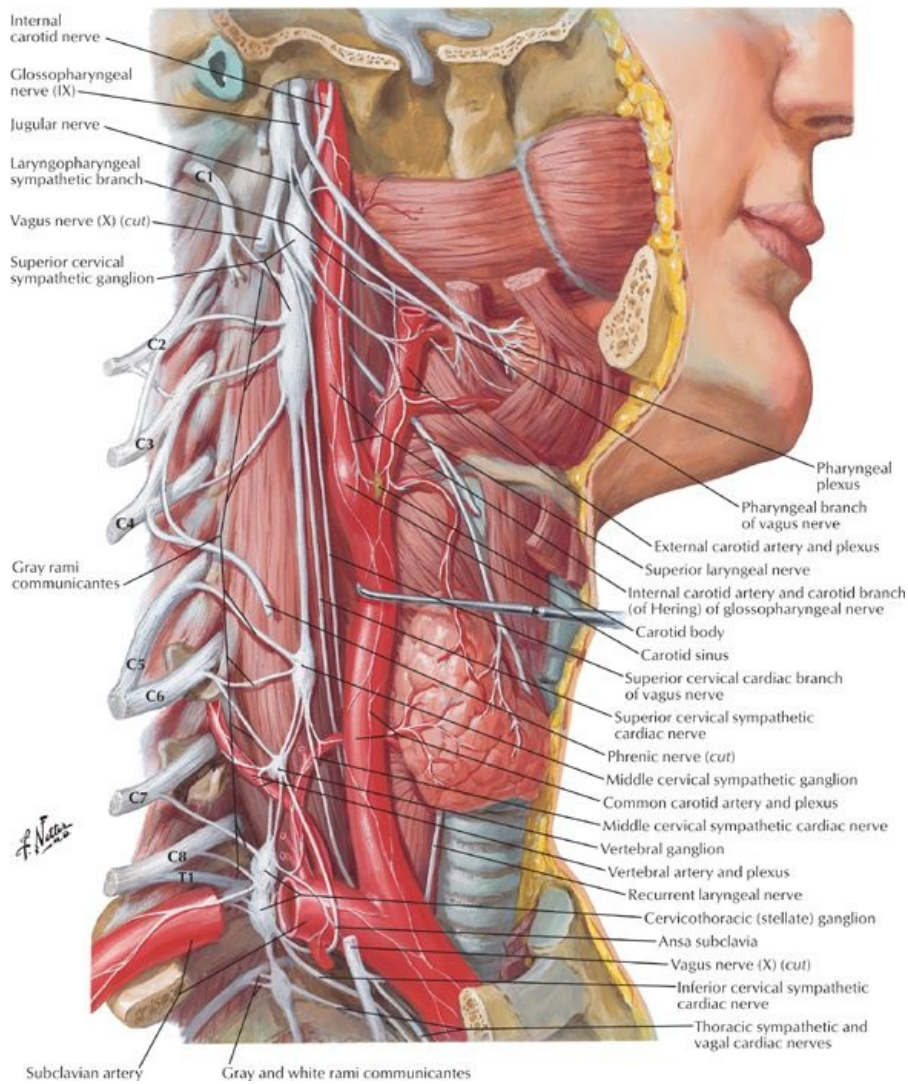
Neck-General Description



[Plate 32, Nerves and Vessels of Neck (Continued)]

- Junction between head and thorax
- Extends from base of skull superiorly to thoracic inlet inferiorly
- Supports head
- Skeleton
 - Bones to which muscles of neck attach
 - Seven cervical vertebrae
 - Hyoid bone
 - Manubrium of the sternum
 - Clavicle
- Contains
 - Blood vessels, nerves, and lymphatics traversing to and from the head and supplying muscles and viscera of the neck
 - Segments of digestive system: pharynx and esophagus
 - Segments of respiratory system: larynx and trachea
 - Endocrine glands: thyroid and parathyroid glands

Triangles of the Neck

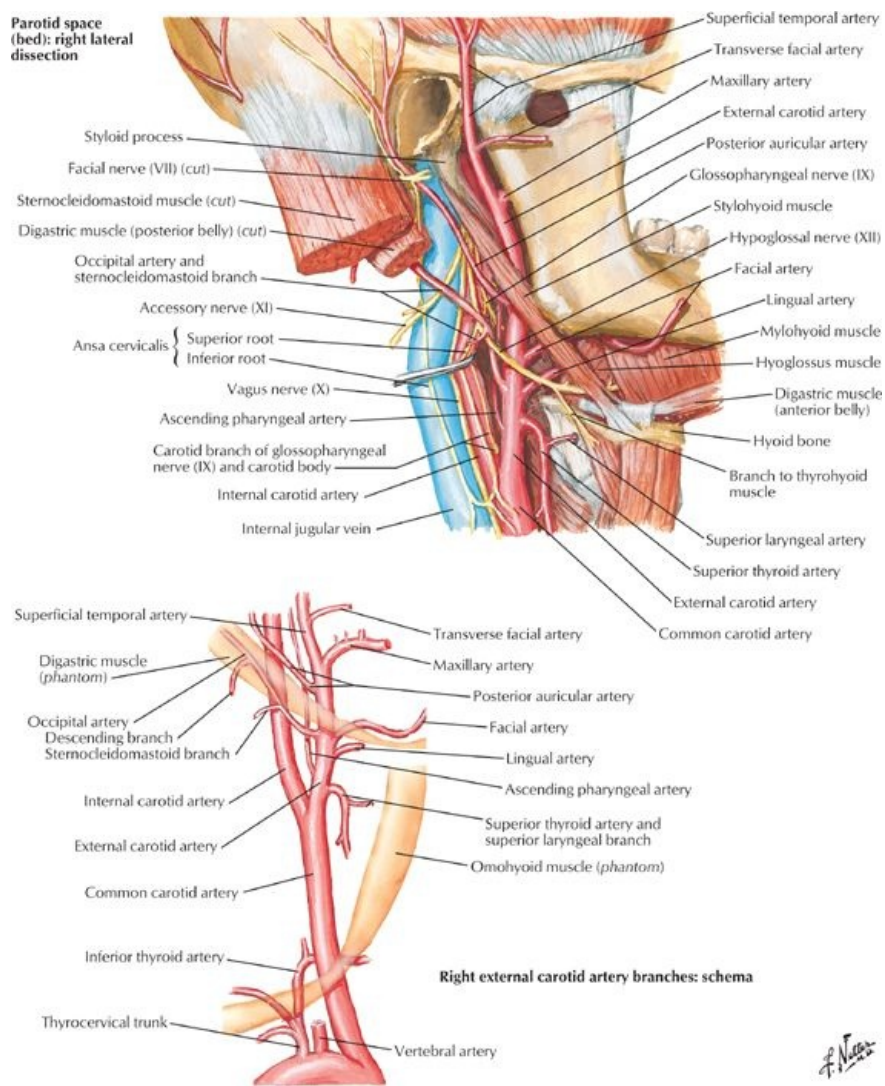


[Plate 129, Autonomic Nerves in Neck]

page 20
page 21

- Sternocleidomastoid (SCM) on each side of neck divides each side into two triangles:
 - Anterior
 - Posterior
- Facilitates description of anatomy of the neck
- Posterior Triangle
 - Boundaries
 - Posterior-anterior border of trapezius
 - Anterior-posterior border of SCM
 - Inferior-medial third clavicle
 - Roof-investing layer of deep cervical fascia
 - Floor-muscles
 - Muscles of the floor
 - Splenius capitis
 - Levator scapulae
 - Middle scalene
 - Posterior scalene
 - Vessels in triangle
 - External jugular vein
 - Subclavian vein
 - Third part of subclavian artery
 - Transverse cervical artery (from thyrocervical trunk)
 - Suprascapular artery (from thyrocervical trunk)
 - Occipital artery (from external carotid)
 - Nerves in the triangle
 - Accessory nerve (cranial nerve [CN] XI)
 - Ventral rami (roots) of brachial plexus
 - Cutaneous branches of cervical plexus
 - Suprascapular nerve
 - Phrenic nerve
 - Subdivided by inferior belly of omohyoid

- Occipital triangle
 - Larger triangle superiorly
 - Crossed by accessory nerve
 - Supraclavicular triangle
 - Smaller inferior triangle
 - Contains external jugular vein, suprascapular artery, and subclavian artery
 - Anterior Triangle
 - Boundaries
 - Lateral-anterior border of SCM
 - Anterior-anterior midline of neck
 - Superior-inferior mandible
 - Divided into four smaller triangles for descriptive purposes
 - Submandibular triangle (1)
 - Between inferior mandible and anterior and posterior bellies of the digastric muscle
 - Contains submandibular gland
 - Submandibular duct
 - Submandibular lymph nodes
 - Submental triangle (2)
 - Between body of hyoid bone and right and left anterior bellies of the digastric muscles
 - Apex is mandibular symphysis
 - Contains submental lymph nodes
 - Carotid triangle (3)
 - Bounded by anterior belly of omohyoid, posterior belly of digastric, and anterior border of SCM
 - Contains carotid sheath, with common carotid artery, internal jugular vein, and vagus nerve
 - Bifurcation of common carotid to internal and external carotid arteries
 - Carotid sinus
 - Carotid body
 - Muscular triangle (4)
 - Bounded by anterior border of SCM, superior belly of omohyoid, midline of neck
 - Contains infrahyoid muscles, thyroid, parathyroid



[Plate 33, Carotid Arteries]

Fascial Layers of Neck

- Superficial fascia
 - Between dermis and investing layer of deep fascia
 - Contains
 - Cutaneous nerves and vessels
 - Lymphatics
 - Fat
 - Platysma muscle anteriorly
- Deep fascia
 - Consists of three layers
 - Investing
 - Pretracheal
 - Prevertebral
 - Also includes carotid sheath: condensation of deep fascia around carotid vessels
- Investing layer of deep fascia
 - Surrounds entire neck, beneath superficial fascia
 - Inferior attachments
 - Manubrium
 - Superior border clavicle
 - Acromion
 - Spine scapula
 - Superior attachments
 - Superior nuchal line
 - Zygomatic arches
 - Angle mandible
 - Mastoid process
 - Spinous processes of cervical vertebrae
 - Splits to enclose sternocleidomastoid and trapezius muscles
 - Encloses parotid and submandibular glands
 - Forms roof of anterior and posterior triangles neck
- Pretracheal fascia
 - Only in anterior neck, from hyoid bone to fibrous pericardium
 - Invests infrahyoid muscles
 - Visceral layer invests
 - Trachea
 - Thyroid and parathyroid glands
 - Esophagus
 - Attaches inferiorly to adventitia of great vessels
 - Attaches superiorly
 - Thyroid cartilage
 - Buccopharyngeal fascia of pharynx
 - Blends laterally with carotid sheath
- Prevertebral fascia
 - Sheath for C1-T3 vertebrae and associated muscles
 - Longus colli and capitis
 - Anterior, middle, and posterior scalenes
 - Deep cervical muscles
 - Described as having two laminae: anterior and posterior
 - Superior attachment of both laminae to base of skull
 - Inferior attachment
 - Anterior lamina to anterior longitudinal ligament and posterior esophagus anteriorly
 - Posterior lamina to fascia over thoracic vertebral column posteriorly
 - Extends laterally as axillary sheath around axillary artery and brachial plexus

page 22
page 23

Carotid sheath

- Condensation of fascia around great vessels of the neck
- Extends from base of skull to root of neck
- United medially with prevertebral fascia
- Contains
 - Common carotid artery
 - Internal carotid artery
 - Internal jugular vein
 - Vagus nerve (CN X)
 - Deep cervical lymph nodes
 - Sympathetic fibers
- Communicates inferiorly with mediastinum

Facial spaces

- Retropharyngeal space
 - Largest and most significant space in neck
 - Potential space between prevertebral layer of deep fascia and buccopharyngeal fascia
 - From base of skull to posterior mediastinum

-
- Permits movement of pharynx, larynx, trachea, and esophagus during swallowing
 - Infection originating in pharyngeal area can spread to retropharyngeal space and inferiorly into superior mediastinum
 - Pretracheal space
 - Space between investing fascia and pretracheal fascia
 - Limited by attachments of fascia to thyroid cartilages superiorly
 - Can spread into thorax anterior to pericardium
 - Space between laminae of prevertebral fascia
 - Critical space
 - Extends from base of skull and through thorax

FACTS & HINTS

High-Yield Facts

Anatomic Points

- **Spinal accessory nerve** has a subcutaneous course in posterior triangle and can be damaged during surgery. Injury causes weakness of sternocleidomastoid and trapezius muscles.
- The **phrenic nerve** arises from cervical nerve roots to supply the diaphragm. Irritation of the diaphragm, e.g., because of infection, can cause referred pain to the C3, C4, C5 dermatome (shoulder).

Clinical Points

Torticollis

- In adults, spasm of the SCM can cause pain and turning and tilting of the head (torticollis)
- Congenital torticollis can occur in infants due to a fibrous tissue tumor in the SCM that develops in utero
- Head bends to affected side and face turns away
- Facial asymmetry can occur, because of growth retardation on affected side

page 23

page 24

Clinical Points

Thoracic outlet syndrome

- Caused by compression of the subclavian artery, vein, and roots of the brachial as they emerge from the root of the neck.
- Patient may complain of pain, paresthesia in the arm as a result of nerve compression; pallor, coldness, and pain in the arm as a result of arterial compression, or swelling in the arm as a result of decreased venous and lymphatic drainage.
- Common cause is the presence of a C7 cervical rib

Mnemonics

Memory Aids

Cervical spinal nerve roots which innervate diaphragm (C3, C4, C5):

C3, 4, 5 keeps the diaphragm alive

5 Nasal Region

STUDY AIMS

At the end of your study, you should be able to:

- Outline the structures that form the nasal region
- Describe the gross structure of the external nose
- Describe the nasal septum
- Define the boundaries of the nasal cavity
- Describe the structure of the nasal cavity including its blood supply, venous and lymphatic drainage, and innervation
- Describe the origin of the paranasal sinuses and their relationship to the nasal cavity

GUIDE

Head and Neck: Nasal Region

Nasal region

- External nose
- Nasal cavities
 - Divided by nasal septum
 - Filter, humidify and warm air
 - Contain specialised olfactory mucosa
 - Receive secretions from paranasal sinuses and nasolacrimal duct
- Includes related paranasal sinuses

External Nose

page 25

page 26

The nose is composed primarily of cartilages except at the "bridge" of the nose where the nasal bone resides. Anteriorly, the air enters or leaves the nose via the nares, which open into the nasal vestibule, whereas posteriorly the nasal cavity communicates with the nasopharynx via paired apertures called the choanae.

- Composed of bone and hyaline cartilage Bones
 - Paired nasal bones
 - Frontal processes of maxilla
 - Nasal part frontal bone
- Cartilages
 - Paired lateral cartilages
 - Paired alar cartilages
 - Septal cartilage
- Associated muscles dilate and flatten nares (nostrils)
 - Nasalis
 - Compressor nares
 - Dilator nares
- Innervation ophthalmic and maxillary divisions of trigeminal nerve (cranial nerve [CN] V₁ and V₂)
- Blood supply
 - Ophthalmic artery
 - Facial artery
- Venous drainage
 - Facial veins → internal jugular veins
 - Ophthalmic veins → cavernous sinus

Nasal septum

The nasal cavity is separated from the cranial cavity by portions of the frontal, ethmoid, and sphenoid bones, and from the oral cavity inferiorly by the hard palate. A nasal septum, usually deviated slightly to one side or the other, divides the nasal cavity into right and left chambers. The anterior third of the nasal septum is cartilaginous and the posterior two thirds is bony.

- Divides nasal cavity into two chambers
- Composed of
 - Bone
 - Vomer
 - Perpendicular plate of ethmoid
 - Septal cartilage
- Septal cartilage articulated with edges of bony septum

Nasal Cavity

page 26

page 27

The lateral wall of the nasal cavity is characterized by three shell-like conchae, or turbinates, that protrude into the cavity, and along with their covering of nasal respiratory epithelium, they greatly increase the surface area for warming, humidifying, and filtering the air. At the most superior aspect of the nasal cavity resides the olfactory region, with its olfactory epithelium and specialized sensory cells for the detection of smells.

- Each cavity narrow above and wider below, separated from each other by nasal septum
- Extend from nares to choanae
 - Naris = external opening of nose
 - Choana = opening into pharynx
- Vestibule
 - First part of cavity
 - Lined with skin with hairs
 - Bounded laterally by alar cartilages
 - Limen nasi
 - Crescentic line
 - Marks upper limit of vestibule
- Nasal mucosa
 - Lines nasal cavities except for vestibule
 - Bound to periosteum and perichondrium of surrounding bones and cartilages
 - Extends into all chambers, cavities and sinuses communicating with nasal cavities

- Upper one third is olfactory areas (mucosa)
- Lower two thirds is respiratory areas (mucosa)
- Boundaries (walls) of nasal cavity
- Nasal conchae
 - Three horizontal projections from lateral wall
 - Superior, middle and inferior nasal conchae
 - Divide nasal cavity into four areas
 - Superior meatus
 - Middle meatus
 - Inferior meatus
 - Sphenoethmoid recess
- Superior meatus
 - Between superior and middle conchae
 - Has openings from posterior ethmoidal sinuses
- Middle meatus
 - Wider and longer than superior
 - Depressed area-atrium-at anterior end
 - Ethmoid infundibulum at anterior end
 - Leads to frontonasal duct
 - Duct leads to frontal sinus
 - Ethmoidal bulla (swelling)
 - Rounded projection at inferior root of middle meatus
 - Represents bulge of ethmoid air cells (sinuses)
 - Groove called semilunar hiatus immediately beneath leads to infundibulum
 - Contains openings for frontal, maxillary, and anterior ethmoidal sinuses
 - Frontal sinus opening at anterior end of semilunar hiatus/infundibulum
 - Maxillary sinus opening at posterior end of semilunar hiatus
 - Variable openings for ethmoid air cells
- Inferior meatus
 - Below inferior concha
 - Receives nasolacrimal duct opens into anterior end
- Sphenoethmoidal recess:
 - Posterior and superior to superior concha
 - Receives opening of sphenoidal sinus
- Innervation
 - Posterior region of nasal cavity
 - Nasal septum: maxillary nerve (CN V₂) → nasopalatine nerve to nasal septum
 - Lateral wall: lateral branches of lateral palatine nerve
 - Anterior and superior regions of nasal cavity: anterior and posterior ethmoidal nerves, branches of nasociliary nerve from ophthalmic nerve (CN V₁)
 - Olfactory epithelium innervated by olfactory nerve (CN I)
- Arterial supply
 - Sphenopalatine artery (branch of maxillary artery)
 - Anterior and posterior ethmoidal arteries
 - Greater palatine artery
 - Superior labial and lateral nasal branches of facial artery
- Venous drainage
 - Plexus of veins beneath nasal mucosa drains to
 - Sphenopalatine veins
 - Facial veins
 - Ophthalmic veins
- Lymphatic drainage
 - Posterior nasal cavity to retropharyngeal nodes
 - Anterior nasal cavity to submandibular nodes

Paranasal sinuses

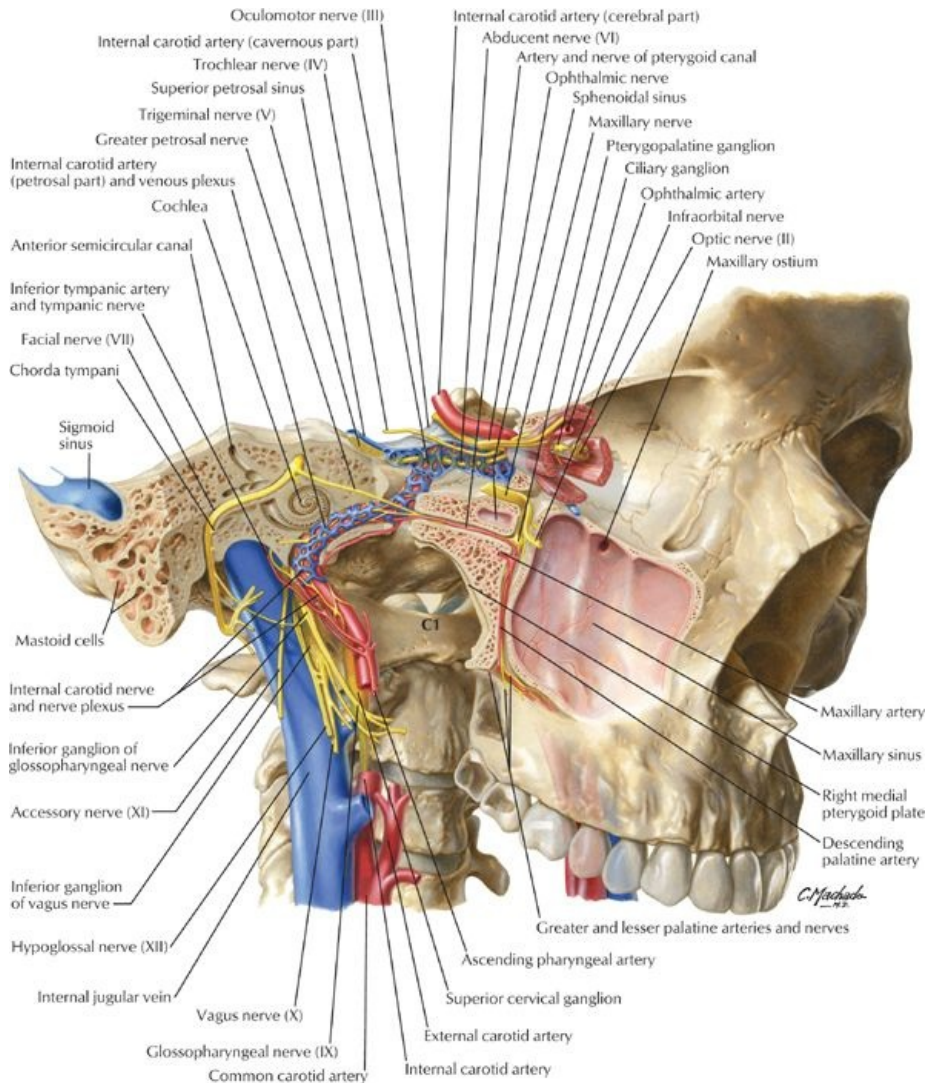
page 27
page 28

Sinus	Description
Frontal	Paired sinuses, lying anteriorly in frontal bone and draining into semilunar hiatus of middle meatus
Ethmoid	Paired anterior, middle, and posterior sinuses in ethmoid bone; anterior and middle draining into middle meatus (hiatus semilunaris and ethmoid bulla, respectively), and posterior, into superior nasal meatus
Sphenoidal	Paired sinuses, in sphenoid bone, draining into sphenoethmoidal recess
Maxillary	Paired sinuses, in maxilla, draining into middle meatus (semilunar hiatus); largest sinus (20-30 ml)

There are four pairs of paranasal sinuses, which are open chambers within several of the bones surrounding the nose and orbits. They are lined with respiratory epithelium, assist in warming and humidifying the inspired air, and drain their mucus secretions into the nasal cavities. Blowing the nose clears the nasal cavity and sinuses of excess secretions.

- Extensions of nasal cavity into maxillary, ethmoid, frontal, and sphenoid bones
- Lined with respiratory epithelium
- Present at birth and increase in size until adulthood
- Air filled
- Frontal sinuses (2)
 - Between inner and outer tables of frontal bone
 - Can be detected around age 7
- Maxillary sinuses (2)

- Largest of paranasal sinuses
- Occupy most of body of maxillae
- Ethmoidal sinuses
 - Several in number
 - Not well developed until after age 2
- Sphenoidal sinuses
 - Derive from extensions of ethmoidal sinuses into sphenoid bone around 2 years of age
 - Numbers different on either side
 - Bony septum between two sides
 - Only a thin plate of bone separates them from critical structures in the anterior and middle cranial fossae: optic nerves, pituitary gland, internal carotid arteries, cavernous sinuses



[Plate 46, Orientation of Nerves and Vessels of the Cranial Base]

FACTS & HINTS

High-Yield Facts

Clinical Points

Nasal Obstruction

- Can occur either acutely or be longer in duration-chronic
- Causes include: large adenoids (in children), tumors, a deviated septum, or foreign bodies.
- Patient may complain of snoring, abnormal speech, or breathing difficulties when eating

Clinical Points

page 28
page 29

Epistaxis

- Nosebleed
- Common because of rich vascular supply to nose
- In younger people occurs in the Little's area-where convergence of anterior ethmoidal artery, septal branches of sphenopalatine and superior labial arteries and greater palatine artery
- In older people can be related to hypertension
- Treatment involves identifying the source of bleeding and stopping the bleeding by direct pressure, packing the nose or cauterizing

Clinical Points

Sinusitis

- Paranasal sinuses may become infected via continuity with nasal cavities
- Inflammation and swelling of mucosa lining sinus
- Can be acute or chronic
- Bacterial infection usually follows a viral infection
- Patient may complain of pain, nasal discharge, blocked nose, postnasal drip, and fever
- Acute sinusitis is usually self-limiting
- Chronic may require antibiotics and if recurrent sinus surgery

Mnemonics

Memory Aids

Nasal Cavity: To help remember the parts of the nasal cavity
Never Call Me Needle Nose
N ares (external)
C onchae
M eatuses
N ares (internal)
N asopharynx

6 Oral Region

STUDY AIMS

At the end of your study, you should be able to:

- Understand the regions and boundaries of the oral cavity
- Know the major anatomic features of the lips, cheeks, and gingivae
- Describe the external features of the tongue
- Outline the intrinsic and extrinsic muscles of the tongue and their movements
- Describe the hard and soft palate and their anatomic features
- Describe the anatomy of the oral cavity related to the soft palate
- Know the muscles of the soft palate, their movements, and their innervation
- Outline the vascular supply and innervation of the palate
- Describe the parotid, submandibular, and sublingual salivary glands, including their vascular supply and innervation

GUIDE

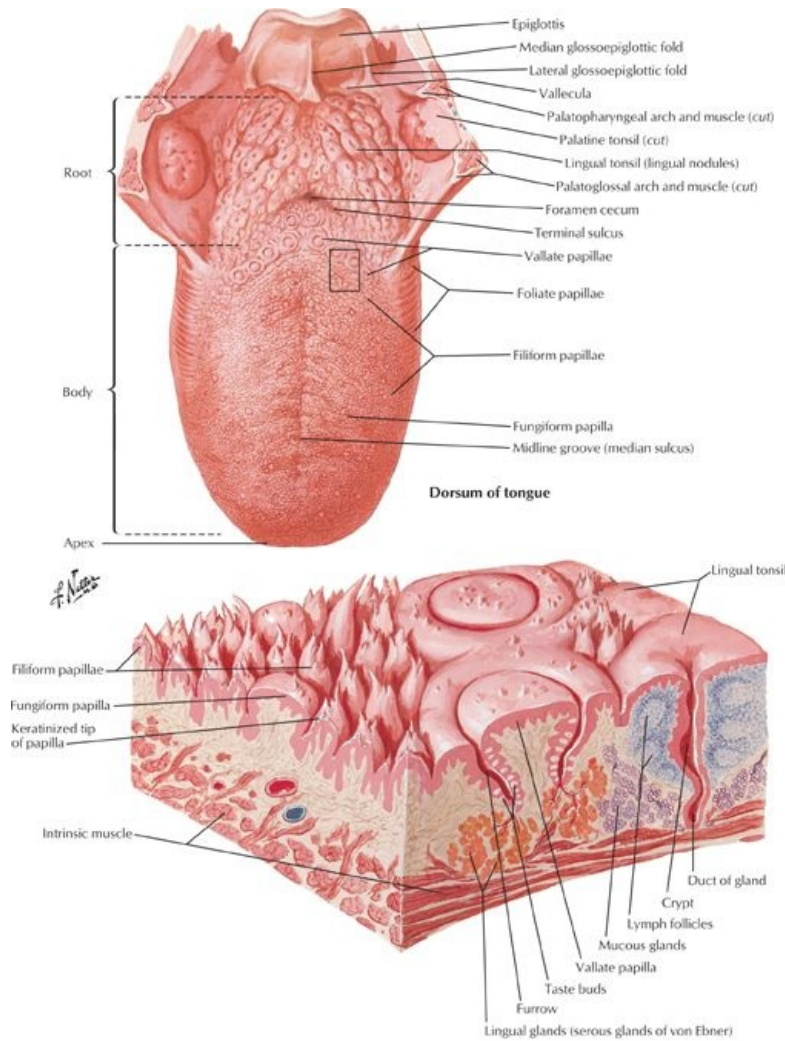
Head and Neck: Oral Region

Oral Cavity

page 30
page 31

- Divided into two regions
 - Oral vestibule
 - Narrow space between teeth and gingival and lips and cheeks
 - Size controlled by orbicularis oris, buccinator, risorius, and muscles controlling lips
 - Contains frenula (singular: frenulum)-midline mucosal folds from upper and lower lips to the gums
 - Oral cavity proper
 - Boundaries
 - Anteriorly: lips
 - Posteriorly: oropharyngeal isthmus to oropharynx
 - Roof: hard palate anteriorly and soft palate posteriorly
 - Floor: mucosa beneath the tongue
 - Space occupied by tongue
- Anatomical features of the lips
 - Contain
 - Orbicularis oris muscle, and fibers of levator labii superioris, depressor anguli oris, zygomaticus major and risorius muscles
 - Superior and inferior labial arteries and veins
 - a. From infraorbital and facial vessels superiorly
 - b. From facial and mental vessels inferiorly
 - Branches of infraorbital nerves (cranial nerve [CN] V₂) superiorly
 - Branches of mental nerves (CN V₃) inferiorly
 - Vermilion border: transition zone (border) of lip
 - Nasolabial grooves from nose to just lateral of angle of mouth separated lips from cheek
 - Philtrum: depression from nasal septum to vermilion border of upper lip
 - Labiomental groove separates lower lip from chin
 - Labial frenula: midline mucosal folds with a free edge that extend from upper and lower lips to the gums
- Anatomical features of the cheeks
 - Lateral walls of oral cavity
 - Form zygomatic prominences over zygomatic bones
 - Principal muscle is buccinator
 - Buccal fat pad external to buccinator
 - Supplied by buccal branches of maxillary artery
 - Innervated by buccal branches of mandibular nerve (CN V₃)
- Gingivae
 - Composed of fibrous tissue covered by mucous membrane
 - Firmly attached to alveolar processes of mandible and maxilla and necks of teeth

Tongue

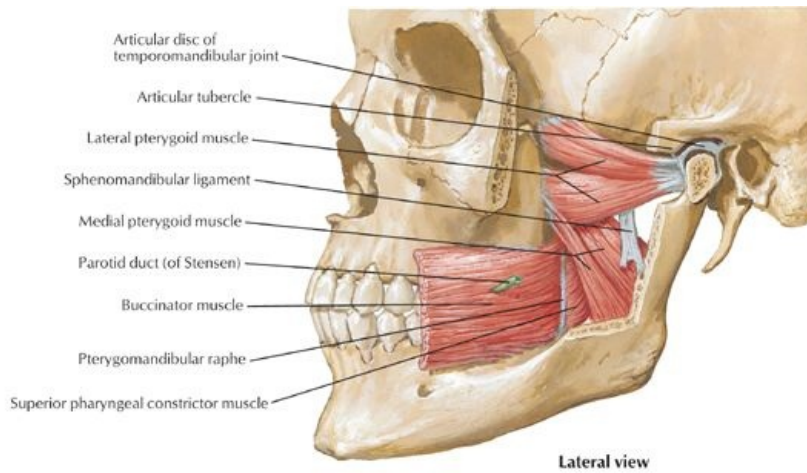


Schematic stereogram: area indicated above
 [Plate 58, Tongue]

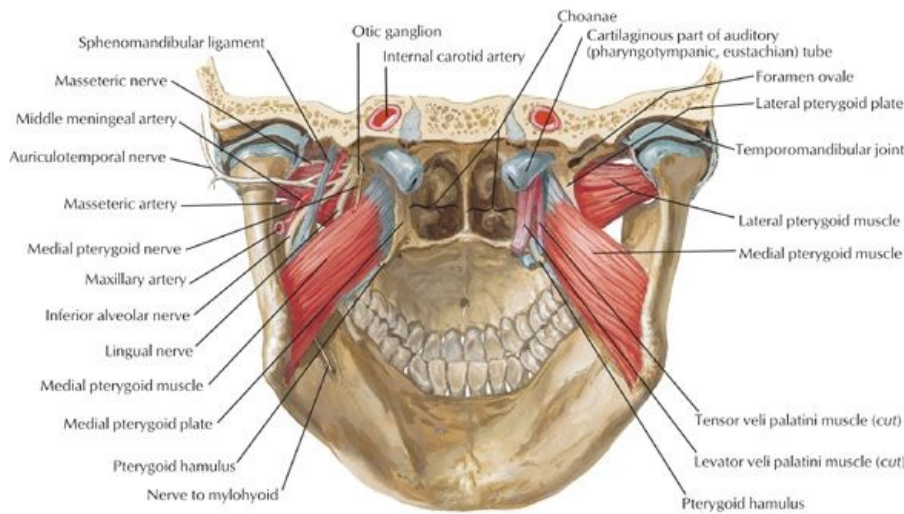
page 31
 page 32
 page 32
 page 33

- Highly mobile organ composed largely of muscle
- Main functions
 - Pressing food into the pharynx during swallowing
 - Assisting in the formation of words during speech
- External features of the tongue anterior to sulcus terminalis
 - Root
 - Posterior one third
 - Attached to hyoid bone and mandible
 - Body: anterior two thirds
 - Apex or tip: pointed or rounded anterior end
 - Dorsum of tongue
 - V-shaped groove: sulcus terminalis
 - a. Divides tongue into oral and pharyngeal parts
 - b. Apex points to foramen cecum
 - Foramen cecum
 - a. Small pit
 - b. Remnant of embryonic thyroglossal duct
 - Numerous papillae of different types
 - Lingual papillae
 - Vallate
 - a. Anterior to sulcus terminalis
 - b. Large and flat-topped
 - c. Have taste buds
 - Foliate
 - a. Small folds on lateral side of tongue
 - b. Have taste buds
 - Filiform
 - a. Numerous and mainly arranged in rows parallel to sulcus terminalis
 - b. Sensitive to touch

- Fungiform
 - a. Mushroom-shaped
 - b. Found on tip and sides of tongue
 - c. Have taste buds
- External features of the tongue posterior to sulcus terminalis
 - Posterior to palatoglossal arches
 - Roughened surface due to underlying lymphatic follicles = lingual tonsil
- External features of inferior tongue
 - Lingual frenulum
 - Midline fold of mucosa from gingivae to posteroinferior surface of tongue
 - Connects tongue to floor of mouth
 - Sublingual caruncle
 - Papilla on either side of frenulum
 - Opening of duct of submandibular gland
- Muscles
 - Both intrinsic and extrinsic muscles are paired
 - All muscles act coordinately
 - Fibrous septum separates muscles of each half of tongue
 - Extrinsic muscles
 - Alter position of tongue
 - Genioglossus
 - a. Most of bulk of tongue
 - b. Contributes to protrusion of tongue
 - c. Moves tongue from side to side
 - Hyoglossus
 - a. Depresses tongue
 - b. Aids in retraction
 - Styloglossus
 - a. Mingles with fibers of hyoglossus
 - b. Creates central trough or furrow with genioglossus during swallowing
 - c. Retracts tongue and curls side
 - Palatoglossus
 - a. Largely a soft palate muscle
 - b. Elevates posterior tongue
 - Intrinsic
 - Alter shape of tongue
 - Superior longitudinal: curls tip of tongue superiorly
 - Inferior longitudinal
 - a. Curls tip of tongue inferiorly
 - b. Acts with superior longitudinal muscle to shorten and thicken tongue
 - Transverse: narrows tongue and increases height
 - Vertical: flattens and broadens tongue
- Vasculature
- Arterial supply
 - Principally from lingual artery, branch of external carotid
 - Dorsal lingual artery
 - Deep lingual artery
 - Sublingual artery
 - Minor contributions from tonsillar and ascending pharyngeal arteries
- Venous drainage
 - Accompanies arterial supply
 - Dorsal lingual veins
 - Deep lingual veins (join sublingual veins)
 - All drain, either directly or indirectly to internal jugular vein
- Lymphatic drainage takes one of four routes
 - Tip (apex) to submental nodes
 - Anterior medial two thirds to inferior deep cervical nodes
 - Anterior lateral two thirds to submandibular nodes
 - Posterior one third to superior deep cervical nodes
- Innervation:
 - All muscles of tongue except palatoglossus supplied by hypoglossal nerve (CN XII)
 - Palatoglossus supplied by pharyngeal plexus (CN IX via CN X)
 - Sensory to anterior two thirds of tongue
 - General sensory: lingual nerve (CN V₃)
 - Special sensory (taste): corda tympani (CN VII)
 - General and special sensory to posterior one third of tongue: glossopharyngeal nerve (CN IX)



Lateral view



Posterior view

[Plate 55, Muscles Involved in Mastication (Continued)]

Muscle	Origin	Insertion	Innervation	Blood Supply	Main Actions
Genioglossus	Mental spine of mandible	Dorsum of tongue and hyoid bone	Hypoglossal nerve	Sublingual and submental arteries	Depresses and protrudes tongue
Hyoglossus	Body and greater horn of hyoid bone	Lateral and inferior aspect of tongue	Hypoglossal nerve	Sublingual and submental arteries	Depresses and retracts tongue
Styloglossus	Styloid process and stylohyoid ligament	Lateral and inferior aspect of tongue	Hypoglossal nerve	Sublingual artery	Retracts tongue and draws it up for swallowing
Palatoglossus	Palatine aponeurosis of soft palate	Lateral aspect of tongue	Vagus nerve and pharyngeal plexus	Ascending pharyngeal arteries and Palatine branches of facial and maxillary arteries	Elevates posterior tongue

Palate

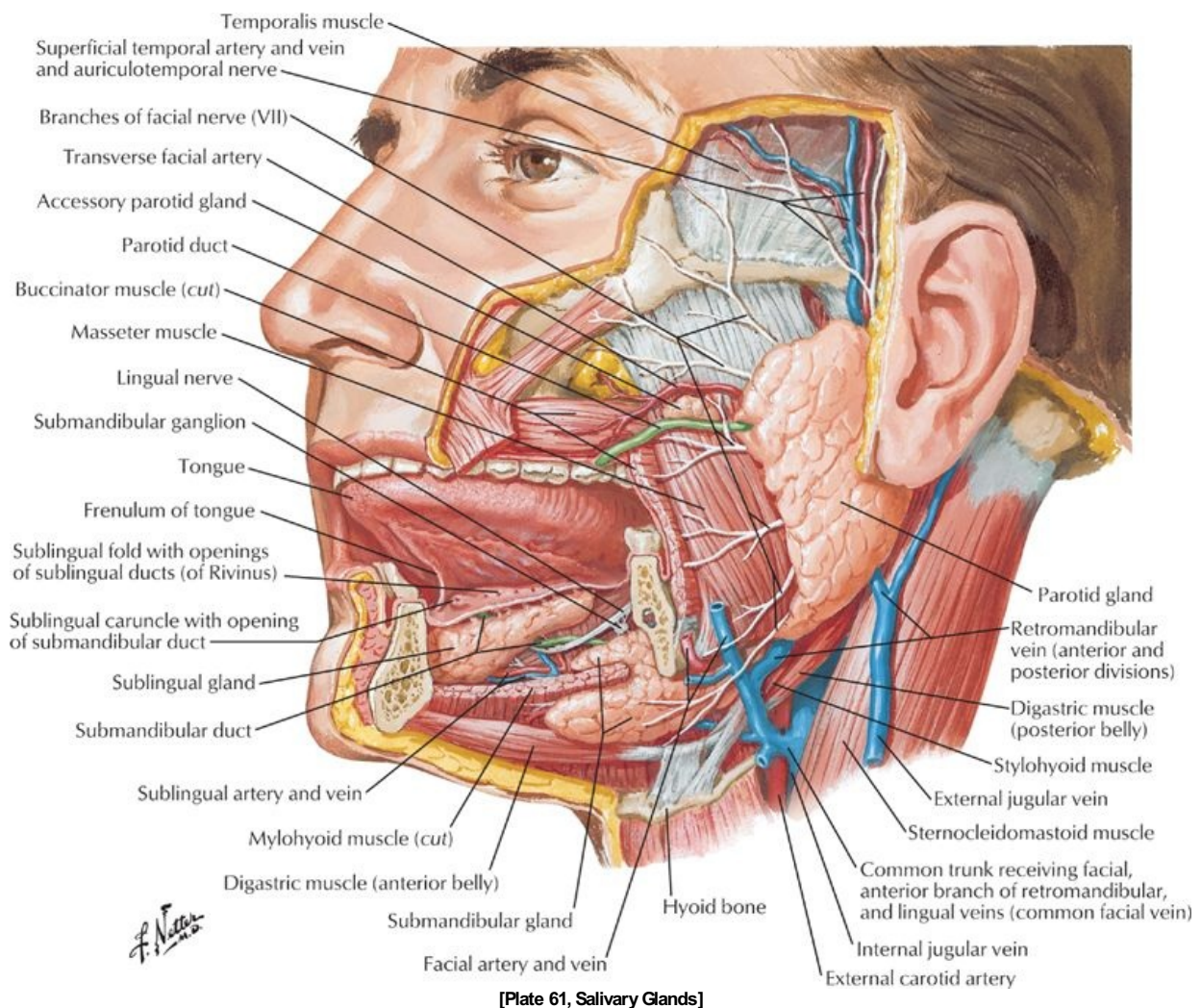
page 33
page 34
page 34
page 35

- Forms roof of mouth and floor of nasal cavities
- Consists of two parts
 - Hard palate anteriorly
 - Formed from by palatine processes of maxillae and horizontal plates of palatine bones
 - Covered with periosteum and oral mucosa (inferiorly) and respiratory mucosa superiorly
 - Has five foramina
 - a. Incisive fossa behind central incisors transmits nasopalatine nerves via incisive canals
 - b. Paired greater palatine foramina medial to third molar transmits greater palatine vessels and nerves
 - c. Paired lesser palatine foramina posterior to greater palatine foramina transmits lesser palatine nerves and vessels
 - Mucous secreting palatine glands beneath mucosa
 - Incisive papilla directly posterior to maxillary incisors
 - Palatine raphe
 - a. Midline ridge/groove

- b. Represents line of fusion of embryonic palatal plates
 - o Soft palate posteriorly
 - Moveable posterior third suspended from hard palate
 - No bony skeleton
 - Attaches to hard palate via aponeurotic palate
 - a. Expanded tendineous aponeurosis of tensor veli palatini muscles
 - b. Thick anteriorly
 - Muscular palate (tensor veli palatini) posteriorly
 - Posterior curved free margin has conical projection: uvula
- Anatomical features related to the soft palate
 - o Arches
 - Join soft palate to tongue and pharynx
 - Palatoglossal arch
 - a. Mucosal fold
 - b. Contains palatoglossus muscle
 - Palatopharyngeal arch
 - a. Mucosal fold
 - b. Posterior to palatoglossal arch
 - c. Contains palatoglossus muscle
 - Form anterior and posterior boundaries of tonsillar fossa on either side
 - o Tonsillar fossae
 - Contain palatine tonsils
 - Masses of lymphoid tissue between arches
 - o Fauces
 - Term for passage from oral cavity to oropharynx
 - Bounded by
 - a. Soft palate superiorly
 - b. Root of tongue inferiorly
 - c. Palatoglossal and palatopharyngeal arches laterally
- Muscles of soft palate
 - o Four paired muscles descend from base of brain to palate
 - Levator veli palatine elevates soft palate during swallowing, opens auditory tube
 - Tensor veli palatini tenses soft palate during swallowing
 - Palatoglossus elevates posterior tongue
 - Palatopharyngeus tenses soft palate and pulls pharynx superiorly and anteriorly during swallowing
 - o Unpaired musculus uvulae shortens uvula
- Swallowing and the palate
 - o Complex mechanism
 - o Soft palate tenses to allow tongue to press against it
 - o Tongue squeezes bolus of food to back of oral cavity
 - o Soft palate elevates superiorly and posteriorly to prevent back flush of food into nasal cavity
- Arterial supply
 - o Branches of descending palatine artery on each side
 - Greater palatine artery
 - Lesser palatine artery
 - o Ascending palatine artery from facial artery
- Venous drainage via pterygoid venous plex
- Lymphatic drainage: deep cervical nodes
- Innervation
 - o Sensory from pterygopalatine ganglion (from CN V₂)
 - Greater palatine nerve to hard palate
 - Nasopalatine nerve to anterior hard palate
 - Lesser palatine nerve to soft palate
 - o Motor
 - Tensor veli palatini innervated by medial pterygoid nerve from otic ganglion (CN V₃)
 - All other muscles by cranial root of spinal accessory nerve (CN XI) via pharyngeal plexus

Muscle	Origin	Insertion	Innervation	Blood supply	Main actions
Levator veli palatini	Temporal (petrous portion) bone	Palatine aponeurosis	Vagus nerve via pharyngeal plexus	Ascending palatine artery branch of facial artery and descending palatine artery branch of maxillary artery	Elevates soft palate during swallowing
Tensor veli palatini	Scaphoid fossa of medial pterygoid plate, spine of sphenoid, and auditory tube	Palatine aponeurosis	Mandibular nerve	Ascending palatine artery branch of facial artery and descending palatine artery branch of maxillary artery	Tenses soft palate and opens auditory tube during swallowing and yawning
Palatopharyngeus	Hard palate and superior palatine aponeurosis	Lateral pharyngeal wall	Vagus nerve via pharyngeal plexus	Ascending palatine artery branch of facial artery and descending palatine artery branch of maxillary artery	Tenses soft palate; pulls walls of pharynx superiorly, anteriorly, and medially during swallowing
Musculus uvulae	Nasal spine and palatine aponeurosis	Mucosa of uvula	Vagus nerve via pharyngeal plexus	Ascending palatine artery branch of facial artery and descending palatine artery branch of maxillary artery	Shortens, elevates, and retracts uvula

Salivary Glands



[Plate 61, Salivary Glands]

page 35
page 36

- Functions
 - Moisten and lubricate food
 - Begin digestion of starches
 - Contribute to
 - Ability to taste
 - Prevention of tooth decay
- Parotid gland:
 - Largest salivary gland
 - Thin watery secretion
 - Found within investing cervical fascia
 - Occupies space between ramus of mandible and anterior border of sternocleidomastoid (SCM) muscle
 - Overlaps posterior masseter muscle
 - Deep part extends posteriorly to mastoid process and external auditory meatus
 - Parotid duct
 - Emerges at anterior border of gland
 - Runs over masseter
 - Pierces buccinator to enter mouth opposite upper second molar
 - Structures passing through the gland
 - Facial nerve
 - a. Enters gland and branches into two stems
 - b. Two stems give rise to five branches that emerge from borders of gland
 - Superficial temporal vein
 - a. Runs through deeper part of gland
 - b. Unites with maxillary vein within the gland to form retromandibular vein
 - External carotid artery through deep part of gland
 - Arterial supply
 - External carotid artery
 - Superficial temporal arteries
 - Venous drainage: retromandibular vein
 - Innervation
 - Great auricular nerve (C2 and C3 spinal nerves)
 - Auriculotemporal nerve (CN V₃)
 - Parasympathetic fibers from glossopharyngeal nerve (CN IX) via auriculotemporal from otic ganglion

-
- Sympathetic fibers from external carotid plexus from cervical ganglia
 - Submandibular gland
 - Lies superior and inferior to posterior half of mandible
 - Divided into superficial and deep parts by mylohyoid muscle
 - Duct
 - Opens at sublingual papilla, one on either side of lingual frenulum
 - Lingual nerve loops under duct
 - Arterial supply: submental artery
 - Innervation
 - Secretomotor parasympathetic fibers
 - a. Presynaptic fibers from facial nerve via chorda tympani to submandibular ganglion
 - b. Postsynaptic fibers from cells in submandibular ganglion
 - Vasoconstrictive sympathetic fibers from superior cervical ganglion
 - Sublingual glands
 - Smallest and deepest of glands
 - Lie in floor of mouth within sublingual folds, between mandible and genioglossus muscle
 - Numerous ducts open along sublingual folds
 - Arterial supply
 - Sublingual artery from lingual artery
 - Submental artery from facial artery
 - Innervation same as that for submandibular gland

FACTS & HINTS

High-Yield Facts

Clinical Points

Parotid Tumors

- Most common salivary gland tumor, but still rare
- More common in people older than 40 years of age
- Patient usually presents with a slow growing lump
- If painful or affecting the facial nerve suggests the tumor is malignant
- Treatment is by surgical excision conserving the facial nerve and its branches

Clinical Points

Sialoadenitis

- Inflammation of the salivary gland
- Can be caused by infection or obstruction of the duct of a gland
- Most commonly a result of bacterial infection (*Staphylococcus aureus*)
- Patient may present with pain, swelling, and fever
- Submandibular gland most commonly affected
- Treatment with antibiotics and/or increasing secretions with drugs
- Relief of the obstruction may require surgery

page 36

page 37

Clinical Points

Sialolithiasis

- Obstruction of the duct of a salivary gland with a calculus (stone)
- Commonly occurs in submandibular gland
- Patient presents with pain when eating and swelling
- Ninety percent of stones are radio-opaque-diagnosis can be made on radiograph
- Ultrasound or computed tomography (CT) can also be useful
- Treatment is by removing the stone, increasing secretions with drugs or surgical removal

Mnemonics

Memory Aids

Three Tonsils	
People (or for short PPL) have three tonsils:	PPL
	Pharyngeal
	Palatine
	Lingual.

7 Pharynx

STUDY AIMS

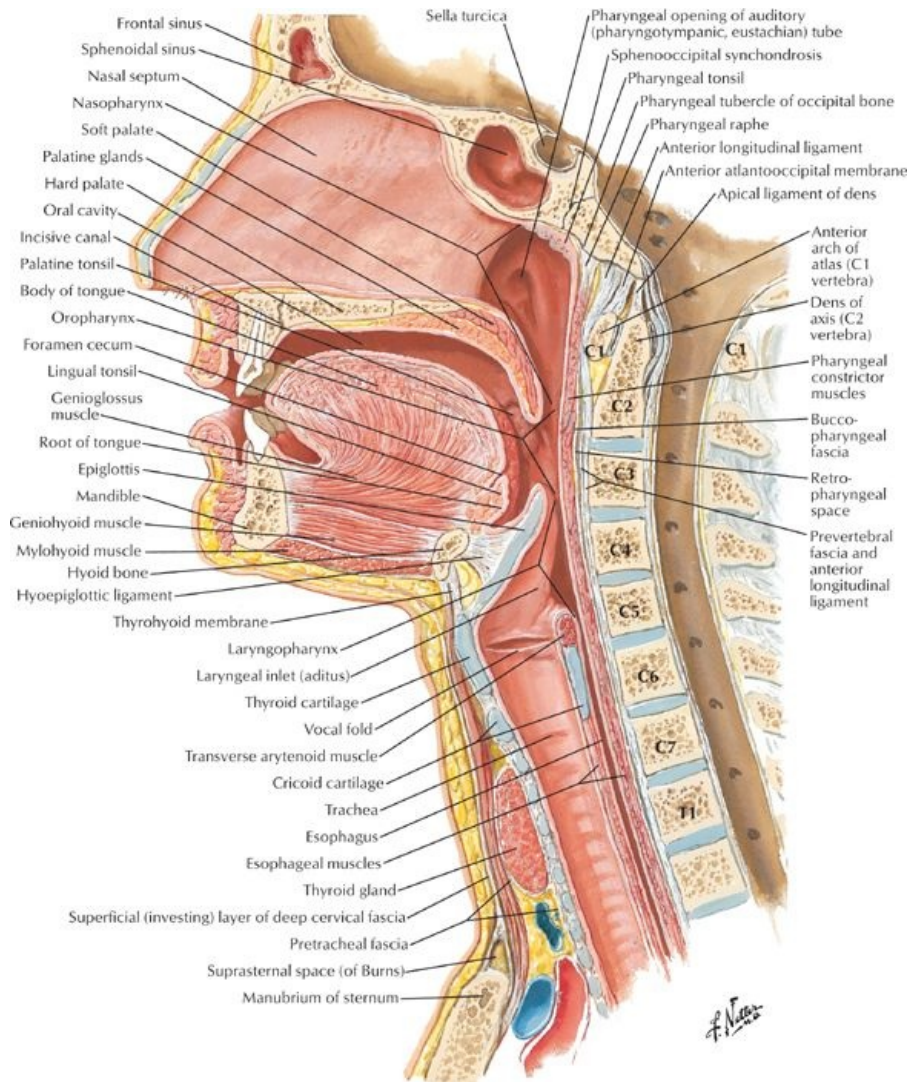
At the end of your study, you should be able to:

- Know the general anatomy of the pharynx
- Describe the anatomy of the nasopharynx
- Describe the anatomy of the oropharynx
- Describe the anatomy of the laryngopharynx
- Know the muscles of the pharynx
- Know the vascular supply and lymphatic drainage of the pharynx
- Understand the innervation of the pharynx
- Outline the process of swallowing

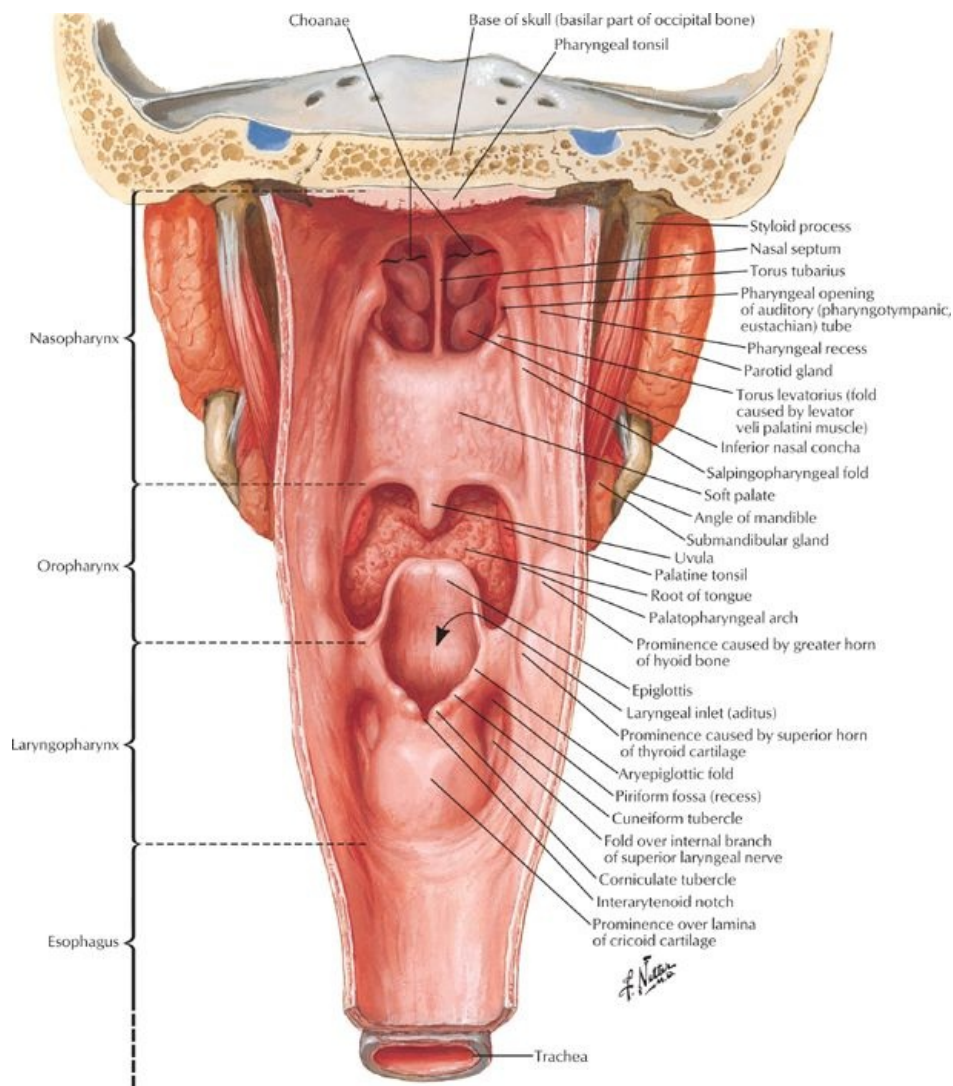
GUIDE

Head and Neck-Pharynx

Pharynx



[Plate 63, Pharynx: Median Section]



[Plate 66, Pharynx: Opened Posterior View]

page 38
page 39

The pharynx is a muscular tube, which is deficient anteriorly as a result of the openings nasal and oral cavities and larynx-as revealed when the posterior wall is removed.

- Muscular tube
- Posterior to nasal and oral cavities
- Continuous with both esophagus and larynx
- Anterior to superior six cervical vertebrae and prevertebral muscles and fascia
- Retropharyngeal space = potential space between pharynx and prevertebral fascia
- Divided into three parts: Nasopharynx, Oropharynx, and Laryngopharynx
- Nasopharynx
 - Posterior to nose and above soft palate
 - Lined with ciliated epithelia
 - Boundaries
 - Anteriorly, continuous with nasal cavities via choanae
 - Roof and posterior wall: body of sphenoid and base of occipital bone
 - Laterally: superior constrictor muscle
 - Contains openings of auditory (Eustachian) tubes (from middle ear)
 - Salpingopharyngeal fold
 - Extends inferiorly from medial end of auditory tube
 - Covers salpingopharyngeus muscle-opens tube during swallowing
 - Ridge over opening = torus tubarius
 - Pharyngeal recess
 - Slit-like projection
 - Posterior to torus
 - Contains abundant lymphoid tissue
 - Incomplete ring in superior part of pharynx
 - Aggregates in certain areas = tonsils
 - Lymphoid tissue in mucus membrane of roof and posterior wall = adenoids
 - Lymphoid tissue near opening of auditory tube = tubal tonsil
- Oropharynx
 - From soft palate to superior ends of epiglottis

- Boundaries
 - Anteriorly: oropharyngeal opening posterior one third tongue epiglottis
 - Laterally: palatoglossal and palatopharyngeal arches (containing palatoglossus and palatopharyngeus muscles)
 - Superiorly: soft palate
 - Posteriorly: superior and middle constrictor muscles
- Contains palatine tonsils
 - Found in cleft between palatoglossal and palatopharyngeal arches
 - Tonsil lies on tonsillar bed = superior constrictor muscle and pharyngobasilar fascia
- Epiglottis
 - United to tongue by median and lateral glossoepiglottic folds
 - Depression between medial and lateral folds = epiglottic valleculae
- Laryngopharynx
 - From superior border of epiglottis to inferior border of cricoid cartilage
 - Lined with stratified squamous epithelium
 - Boundaries
 - Inferiorly: continuous with esophagus
 - Superiorly: continuous with oropharynx
 - Anteriorly: larynx
 - Posteriorly: middle and inferior constrictor muscles deep: Bodies of C4-C6 vertebrae
 - Laterally: middle and inferior constrictor muscles
 - Piriform recesses
 - Small depressions on either side of laryngeal inlet
 - Separated from inlet by aryepiglottic folds
 - Bounded medially by thyroid cartilage and thyrohyoid membrane

Muscles of Pharynx

page 39
page 40

- Wall of pharynx is unique
 - Composed of *outer circular* and *inner longitudinal* layers of muscles
 - External circular layer consists of three constrictor muscles: pharyngeal constrictors
 - Inner longitudinal layer consists of three paired muscles
- Pharyngeal constrictors = three muscles
 - Superior, middle, and inferior constrictor muscles form a muscular sleeve
 - Have strong internal facial lining: pharyngobasilar fascia
 - Contract involuntarily in sequence = peristalsis
 - All supplied by pharyngeal plexus of nerves
- Inner longitudinal layer = three muscles
 - Elevate larynx
 - Shorten pharynx
 - Act during swallowing and speaking
 - Stylopharyngeus
 - Palatopharyngeus
 - Salpingopharyngeus
- Gaps between constrictors
 - Areas where structures can enter and leave pharynx
 - Between superior constrictor and skull
 - Levator veli palatini
 - Auditory tube
 - Ascending palatine artery
 - Between superior and middle constrictor
 - Stylopharyngeus muscle
 - Glossopharyngeal nerve
 - Stylohyoid ligament
 - Between middle and inferior constrictor
 - Internal laryngeal nerve
 - Superior laryngeal artery and vein
 - Below inferior constrictor
 - Recurrent laryngeal nerve
 - Inferior laryngeal artery

Muscle	Origin	Insertion	Innervation	Main Actions
Superior pharyngeal constrictor	Hamulus, pterygomandibular raphe, mylohyoid line of mandible	Median raphe of pharynx	Vagus via pharyngeal plexus	Constricts wall of pharynx during swallowing
Middle pharyngeal constrictor	Stylohyoid ligament and horns of hyoid bone	Median raphe of pharynx	Vagus via pharyngeal plexus	Constricts wall of pharynx during swallowing
Inferior pharyngeal constrictor	Oblique line of thyroid cartilage, and cricoid cartilage	Median raphe of pharynx	Vagus via pharyngeal plexus	Constricts wall of pharynx during swallowing
Salpingopharyngeus	Auditory (pharyngotympanic) tube	Side of pharynx wall	Vagus via pharyngeal plexus	Elevates pharynx and larynx during swallowing and speaking
Stylopharyngeus	Medial aspect of styloid process	Pharyngeal wall	Glossopharyngeal nerve	Elevates pharynx and larynx during swallowing and speaking

Arterial supply

- Tonsillar artery (from facial) to tonsil

- Branches from
 - Ascending pharyngeal
 - Lingual
 - Ascending and descending palatine

Venous drainage

- External palatine vein → pharyngeal plexus
- Pharyngeal venous plexus → internal jugular vein

Lymphatic drainage

- General drainage to deep cervical nodes
- From tonsillar tissue to nodes near angle of mandible and tonsillar (jugulodigastric) node

Innervation

page 40
page 41

- From pharyngeal plexus (motor and almost all sensory)
- Motor
 - From pharyngeal plexus via vagus nerve from cranial root of accessory nerve (cranial nerve [CN] XI)
 - To all muscles of pharynx except stylopharyngeus (CN V₂)
 - Branches from external and recurrent branches of vagus
 - To inferior constrictor
- Sensory
 - Mainly from glossopharyngeal nerve (CN IX) via plexus
 - Also
 - Maxillary nerve (CN V₂) to anterior and superior nasopharynx
 - Tonsillar nerves from branches of glossopharyngeal and vagus (CN X)

Swallowing (deglutition)

- Occurs in three stages
- 1 = voluntary
 - Food is in the mouth, breathing occurs through the nasopharynx
 - Food is chewed (masticated) and mixed with saliva to produce a bolus
 - Bolus of food is compressed against hard palate
 - Palatoglossal folds relax
 - Muscles of tongue and soft palate push bolus into oropharynx
 - Cycle lasts 1 to 2 seconds
- 2 = involuntary
 - Reflexive, mediated via glossopharyngeal nerve
 - Nasopharynx is closed off by tension and elevation of the soft palate
 - Prevents reflux of food/fluids into the nose
 - Mediated by tensor veli palatine and levator veli palatine muscles
 - Suprahyoid muscles and longitudinal pharyngeal muscles contract
 - Elevate larynx
 - Close epiglottis
 - Propel bolus
- 3 = involuntary
 - Food propelled through the pharynx by peristalsis (sequential contraction of all three constrictors)
- On reaching the distal end of pharynx, high pressure causes relaxation of terminal part of inferior constrictor
 - Called cricopharyngeus muscle
 - Serves as superior esophageal sphincter
 - Food enters the oesophagus
- As bolus passes pressure drops, the sphincter closes
- Larynx and epiglottis return to normal positions

FACTS & HINTS

High-Yield Facts

Anatomic Points

- The piriform fossa is a common site for fish bones to lodge. It is also a site where pharyngeal tumors can grow undetected for a period of time.
- Aggregations of lymphoid tissue in the nasopharynx are called adenoids. They can become enlarged in children, causing obstruction of the nasopharynx and forcing the child to breathe through the mouth.

page 41
page 42

Clinical Points

Pharyngitis

- Also called a sore throat
- Usually caused by viral infection
- In children, common cause of bacterial pharyngitis is beta hemolytic streptococcus
- If infection is severe, auditory tubes can become blocked, predisposing to otitis media
- Patient may complain of pain on swallowing and pain referred to the ear
- On examination, the throat may be reddened and cervical lymph nodes may be enlarged

Clinical Points

Tonsillectomy

- Surgical removal of the palatine and lingual tonsils
- Tonsillectomy is advised if the patient has experienced recurrent attacks of tonsillitis, particularly if they resulted in airway obstruction and hearing difficulties
- A major and common surgical procedure performed in children in the USA
- Recovery usually within 2 weeks, although for adults this may take longer and can have a higher complication rate

8 Thyroid Gland and Larynx

STUDY AIMS

At the end of your study, you should be able to:

- Know the general anatomy of the larynx
- Describe the cartilaginous skeleton of the larynx
- Describe the membranes of the larynx
- Know the internal anatomy of the larynx
- List the intrinsic and extrinsic muscles of the larynx and their function
- Describe the arterial supply, venous and lymphatic drainage, and innervation of the larynx
- Describe the structure of the thyroid gland
- Describe the structure of the parathyroid glands

GUIDE

Head and Neck: Thyroid Gland and Larynx

Larynx: General Anatomy

- Organ of phonation and sphincter guarding lower respiratory tract
- Approximately 8 cm long
- Connects oropharynx with trachea
- Lies anterior to prevertebral muscles, fascia, and the bodies of C3-C6 vertebrae

Laryngeal skeleton

page 43
page 44

- Comprised of three paired and three nonpaired cartilages
- Epiglottic cartilage (epiglottis)
 - Leaf-shaped elastic cartilage
 - Posterior to root of tongue and hyoid bone, anterior to laryngeal inlet
 - Broad superior end is free
 - Inferior end attached in midline to angle of thyroid laminae by thyroepiglottic ligament
 - Quadrangular membranes run between lateral sides of epiglottic cartilage and arytenoid cartilages on either side
 - Upper free margin of quadrangular membrane + covering mucosa = aryepiglottic fold
 - During swallowing overlies laryngeal inlet
- Thyroid cartilage
 - Composed of two flat laminae
 - Lower two thirds of laminae fuse in midline to form laryngeal prominence (Adam's apple)
 - Upper one third of laminae diverge to form superior thyroid notch
 - Posterior superior border of each plate projects superiorly as superior horns
 - Posterior inferior border of each plate projects inferiorly as inferior horns
 - Superior horns and superior borders of laminae attach to hyoid bone by thyrohyoid membrane
- Cricoid cartilage
 - Signet ring shaped, signet (lamina) facing posteriorly
 - Strong, thick, complete circle of cartilage
 - Attached to inferior thyroid by median cricothyroid ligament
 - Attached to first tracheal ring by cricotracheal ligament
- Arytenoid cartilages (paired)
 - Pyramid shaped with three sides
 - Articulate with lateral superior parts of cricoid lamina
 - Has three processes:
 - a. Apex at superior end
 - b. Vocal process projects anteriorly
 - c. Muscular process projects laterally
 - Apex: Corniculate cartilage sits atop; attaches to aryepiglottic fold
 - Vocal process: posterior attachment for vocal ligament
 - Muscular process: attachment for posterior and lateral cricoarytenoid muscles
- Corniculate and cuneiform cartilages
 - Nodules in posterior aryepiglottic folds
 - Cuneiforms do not attach to other cartilages
 - Corniculates attach to apices of arytenoids

Membranes of the laryngeal skeleton

- Cricothyroid ligaments
 - Median cricothyroid ligament
 - Lateral cricothyroid ligaments (conus elasticus)
 - Both attach to cricoid cartilage to inferior border of thyroid cartilage
 - Medial free edge of lateral cricothyroid ligaments = vocal ligaments, basis of true vocal cords
- Quadrangular membrane
 - Inelastic connective tissue
 - Attaches lateral aspects of arytenoids and epiglottis
 - Lower free border = vestibular ligament (false vocal cord)
 - Covered by vestibular fold
 - Above vocal fold
 - Extends from thyroid cartilage to arytenoid cartilage
 - Upper free border forms aryepiglottic ligament
 - Covered with mucosa
 - Called aryepiglottic fold
- Thyrohyoid membrane
 - Bridges gap between superior border and superior horns of thyroid cartilage and
 - Pierced by superior laryngeal vessels and internal laryngeal nerve
- Mucous membrane
 - Respiratory epithelium except over true and aryepiglottic folds
 - This is composed of stratified squamous epithelium

- Laryngeal cavity
 - From laryngeal inlet to tracheal cavity
 - Can be divided into three parts
 - Vestibule-above vestibular folds
 - Ventricle-sinus between vestibular folds above and vocal folds below
 - Infraglottic cavity-from below vocal folds to inferior border of cricoid cartilage
- Vocal folds
 - Paired, project into laryngeal cavity on either side
 - Consist of
 - Vocal ligament-medial free edge of lateral cricothyroid ligament (conus elasticus)
 - Vocalis muscle-medial fibers of thyroid arytenoids muscle
 - Overlying mucosa
 - Source of sound
 - Produce audible vibrations when free edges of folds closely approximate each other
 - Are sphincter of larynx when folds are tightly approximated
- Rima glottidis
 - Space between vocal folds
 - Varies in size with activity
 - During normal breathing: narrow wedge
 - During forced respiration: wide apart
 - During phonation: slit-like
- Vestibular folds (false vocal cords)
 - Folds of mucous membrane over vestibular ligaments superior to vocal folds
 - Extend between thyroid and arytenoids cartilages
 - Protective in function
- Ventricle of larynx: lateral outpocketings between vocal and vestibular folds on either side

Muscles of the larynx

- Extrinsic muscles
 - Are muscles attached to hyoid bone and thus move thyroid
 - Infrahyoid muscles: lower larynx and hyoid bone
 - Sternohyoid
 - Omohyoid
 - Sternothyroid
 - Thyrohyoid
 - Suprahyoid muscles: Fix hyoid or elevate hyoid bone and larynx
 - Stylohyoid
 - Digastric
 - Myohyoid
 - Stylopharyngeus-elevates hyoid bone and larynx
- Intrinsic muscles
 - Alter length and tension of vocal cords
 - Alter rima glottides
 - Adductors
 - Lateral cricoarytenoid muscles
 - Transverse arytenoids
 - Abductors: posterior cricoarytenoid muscles
 - Sphincters
 - Transverse arytenoids muscles
 - Oblique arytenoids muscles
 - Aryepiglottic muscles
 - Tensors: cricothyroid muscles
 - Relaxers
 - Thyroarytenoid muscles
 - Vocalis muscles
 - All except cricothyroid supplied by recurrent laryngeal nerve

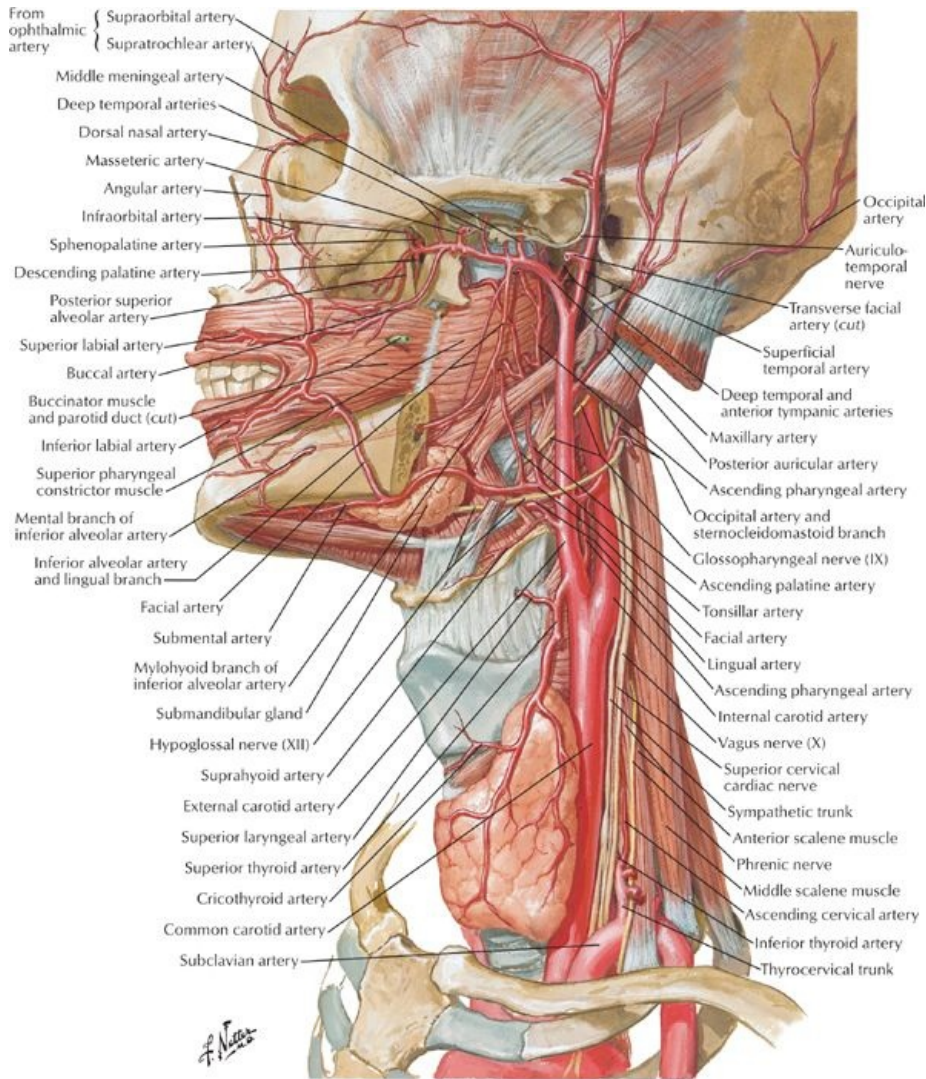
Muscle	Proximal Attachment (Origin)	Distal Attachment (Insertion)	Innervation	Blood Supply	Action
Cricothyroid	Anterior cricoid cartilage	Inferior border of thyroid cartilage and its inferior horn	External branch of superior laryngeal nerve	Superior and inferior thyroid arteries	Lengthens and tenses vocal ligaments
Posterior cricoarytenoid	Posterior surface of lamina of cricoid cartilage	Muscular process of arytenoid cartilage	Recurrent laryngeal nerve	Superior and inferior thyroid arteries	Abducts vocal folds
Lateral cricoarytenoid	Arch of cricoid cartilage	Muscular process of arytenoid cartilage	Recurrent laryngeal nerve	Superior and inferior thyroid arteries	Adducts vocal folds
Thyroarytenoid	Posterior aspect of thyroid cartilage	Muscular process of arytenoid cartilage	Recurrent laryngeal nerve	Superior and inferior thyroid arteries	Shortens and relaxes vocal cords

Vocalis	Vocal process of arytenoids cartilage	Vocal ligament	Recurrent laryngeal nerve	Superior and inferior thyroid arteries	Tenses anterior vocal ligament and relaxes posterior vocal ligament
Transverse and oblique arytenoids	Arytenoid cartilage	Opposite arytenoid cartilage	Recurrent laryngeal nerve	Superior and inferior thyroid arteries	Closes intercartilaginous portion of rima glottides

Joints of the larynx and movements at the joints

- Cricothyroid joints
 - Thyroid cartilage glides and rotates here
 - Changes length of vocal folds
- Cricoarytenoid joints: movement of the arytenoids cartilage on the lamina of the cricoid
 - Slide towards each other and away from each other
 - Rotate
 - Tilt forward and back

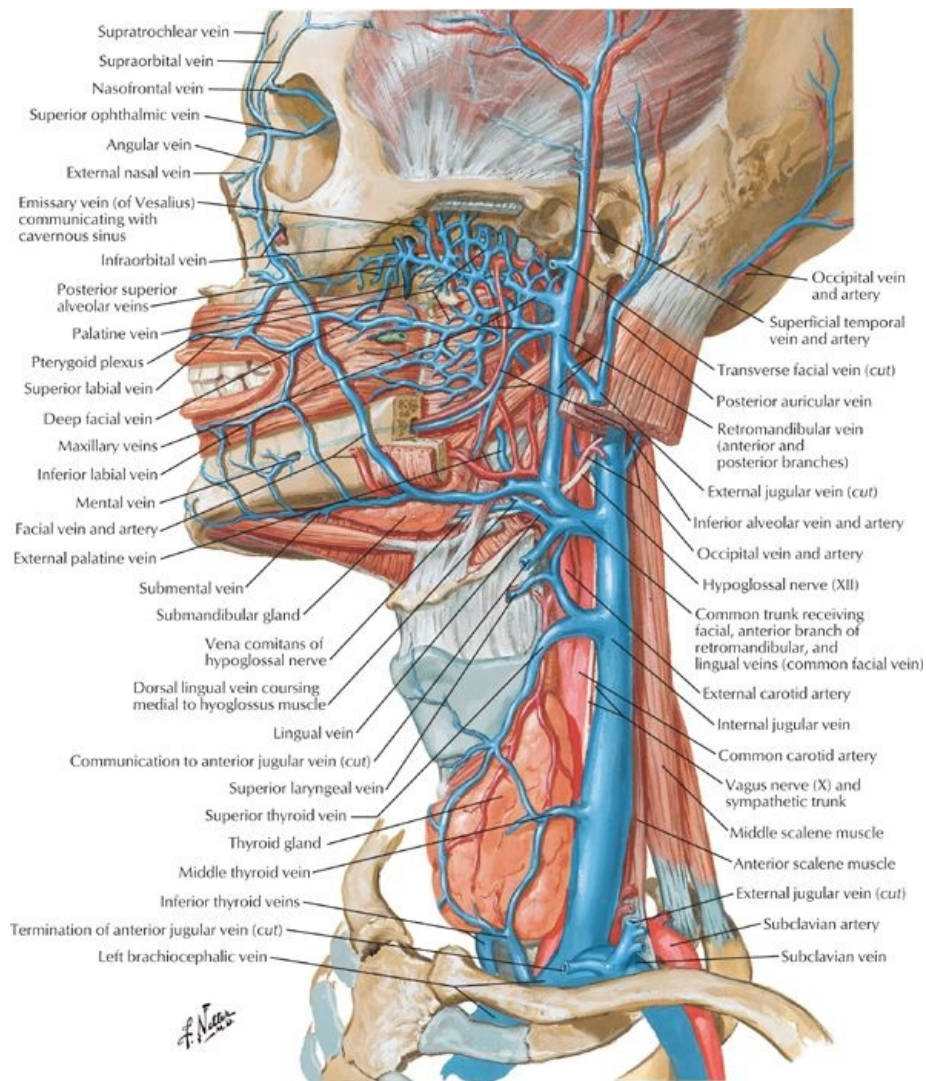
Arterial supply to larynx



[Plate 69, Arteries of Oral and Pharyngeal Regions]

- Superior laryngeal artery
 - Through gap in thyrohyoid membrane
 - Supplies internal larynx
 - Accompanied by superior laryngeal nerve
- Inferior laryngeal artery
 - Supplies inferior internal larynx
 - Accompanied by recurrent laryngeal nerve

Venous drainage of larynx



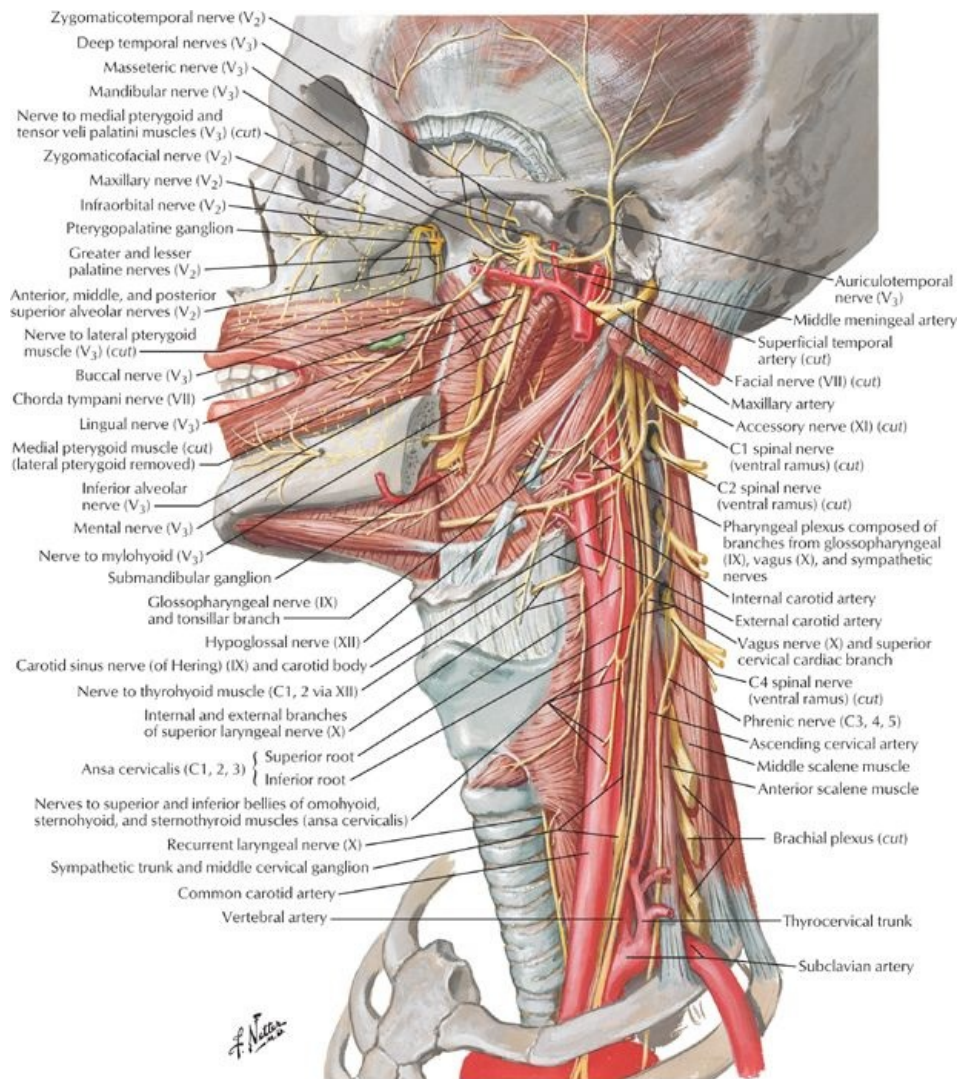
[Plate 70, Veins of Oral and Pharyngeal Regions]

- Superior laryngeal vein to internal jugular vein
- Inferior laryngeal vein → inferior thyroid vein or thyroid venous plexus (left brachiocephalic)

Lymphatic drainage of larynx

- Above folds: to deep cervical nodes
- Below folds: to paratracheal nodes to deep cervical nodes

Innervation of larynx



[Plate 71, Nerves of Oral and Pharyngeal Regions]

- Sensory
 - Above vocal folds: internal laryngeal nerve (branch of superior laryngeal)
 - Below vocal folds: inferior laryngeal nerve (branch of recurrent laryngeal nerve)
- Motor:
 - Recurrent laryngeal nerve to all intrinsic muscles except cricothyroid
 - External laryngeal nerve to cricothyroid

Thyroid Gland

page 47
page 48

- H-shaped endocrine gland
- Produces two hormones
 - Thyroid hormone-controls metabolic rate
 - Calcitonin-controls calcium metabolism
- Overlies anterior and lateral surface trachea
- Enclosed in thin fibrous capsule with septa into gland
- Surrounded by pretracheal fascia (therefore moves on swallowing)
- Two lateral lobes linked by isthmus
 - Lobes extend from second to fifth tracheal ring
 - Isthmus lies at third tracheal ring
- Occasionally a pyramidal lobe extends superiorly from isthmus on left side
- Anatomic relationships
 - Anteriorly: sternohyoid and sternothyroid muscles jugular vein
 - Anterolaterally: infra-hyoid muscles sternocleidomastoid
 - Posterolaterally: carotid sheath
 - Posteromedially: trachea
larynx
esophagus
- Innervation
 - Parasympathetic: external branch superior laryngeal nerve (branch vagus n.)
 - Sympathetic

- From: superior, middle, and inferior cervical ganglia
 - Vasomotor, not secretomotor
- Arterial supply
- Superior thyroid artery
 - Branch of external carotid artery
 - Divides into anterior and posterior branches
 - Anterior branch
 - Supplies anterior thyroid
 - Anastomoses with opposite anterior branch
 - Posterior branch
 - Supplies posterior thyroid
 - Anastomoses with inferior thyroid artery
- Inferior thyroid artery
 - Branch thyrocervical trunk from subclavian artery
 - Supplies inferior pole of thyroid
- Thyroid ima artery
 - Branch of aorta
 - Occurs in 10% of all people
 - Unpaired, on left of midline
 - Supplies isthmus
- Venous drainage
 - Three pairs of thyroid veins
 - Superior thyroid vein
 - Drains superior region of thyroid
 - Tributary of internal jugular
 - Middle thyroid veins
 - Drain middle of gland
 - Tributaries of internal jugular
 - Inferior thyroid veins
 - Drain inferior region of thyroid
 - Tributaries of brachiocephalic vein
- Lymphatic drainage
 - Lymphatic vessels run with arteries
 - Drain to capsular network of lymphatics
 - → prelaryngeal, pretracheal, or paratracheal nodes
 - → deep cervical nodes
- Innervation: sympathetic from cervical sympathetic ganglia

Parathyroid Gland

- Small, oval endocrine glands
- On medial half of posterior surface of lateral lobes of thyroid, external to capsule
- Two pairs of glands
 - Superior glands slightly above entrance of inferior thyroid arteries
 - Inferior glands slightly below entrance of inferior thyroid arteries
- Arterial supply
 - Superior thyroid artery
 - Inferior thyroid artery
 - Thyroid ima artery
- Venous drainage
 - Parathyroid veins
 - → thyroid plexus of veins
- Lymph drainage: paratracheal and deep cervical lymph nodes

FACTS & HINTS

High-Yield Facts

Clinical Points

page 48
page 49

Severance of recurrent laryngeal nerve

- Recurrent laryngeal nerve (supplies intrinsic muscles larynx)
- Is closely associated with inferior thyroid artery and needs to be avoided during neck surgery
- If unilateral damage, voice hoarseness may result because one vocal fold cannot approximate the other.
- If bilateral damage, loss of voice will result because vocal folds cannot approximate each other (be adducted)

Clinical Points

Thyroid lumps

- Lumps in thyroid can be single, multiple
- Solitary nodules are likely to be benign (80%)
- Investigation includes: history, examination, and fine-needle aspiration of the gland for cytology and radionuclide imaging
- Most common malignant is papillary thyroid cancer
- Treatment is total thyroidectomy

Clinical Points

Hyperthyroidism

- Medical condition with increased activity of the thyroid gland
- Results in excessive amount of circulating thyroid hormones
- Leads to increased rate of metabolism
- Affects about 1% of women and 0.1% of men
- Thyrotoxicosis is a toxic condition caused by an excess of thyroid hormones from any cause.
- Hyperthyroidism with diffuse goiter (Graves' disease)
 - Most common cause of hyperthyroidism in patients younger than 40 years.
 - Excess synthesis and release of thyroid hormone (T_3 and T_4) result in thyrotoxicosis,
 - Thyrotoxicosis upregulates tissue metabolism and leads to symptoms indicating increased metabolism.

Mnemonics

Memory Aids

Table 100-2. Cartilages of the Larynx

Four cartilages in the larynx:	TEAC
	Thyroid, Epiglottis, Arytenoid, Cricoid

Note: TEAC is a brand name of a home stereo. Associate the TEAC sound with the vocal cords and you can make a connection.

9 Orbit and Contents

STUDY AIMS

At the end of your study, you should be able to:

- Define the boundaries, content, and function of the bony orbit
- Know the foramina of the bony orbit and what they transmit
- Describe the anatomy of the eyelids
- Describe the anatomy of the lacrimal apparatus and know its functions
- Know the anatomy of the eyeball and the composition of its three layers
- Understand the roles of the refractive structures and media of the eyeball
- Outline the key extraocular and intraocular muscles and their function
- Know the vascular supply of the eye
- Outline the innervation of the eye

GUIDE

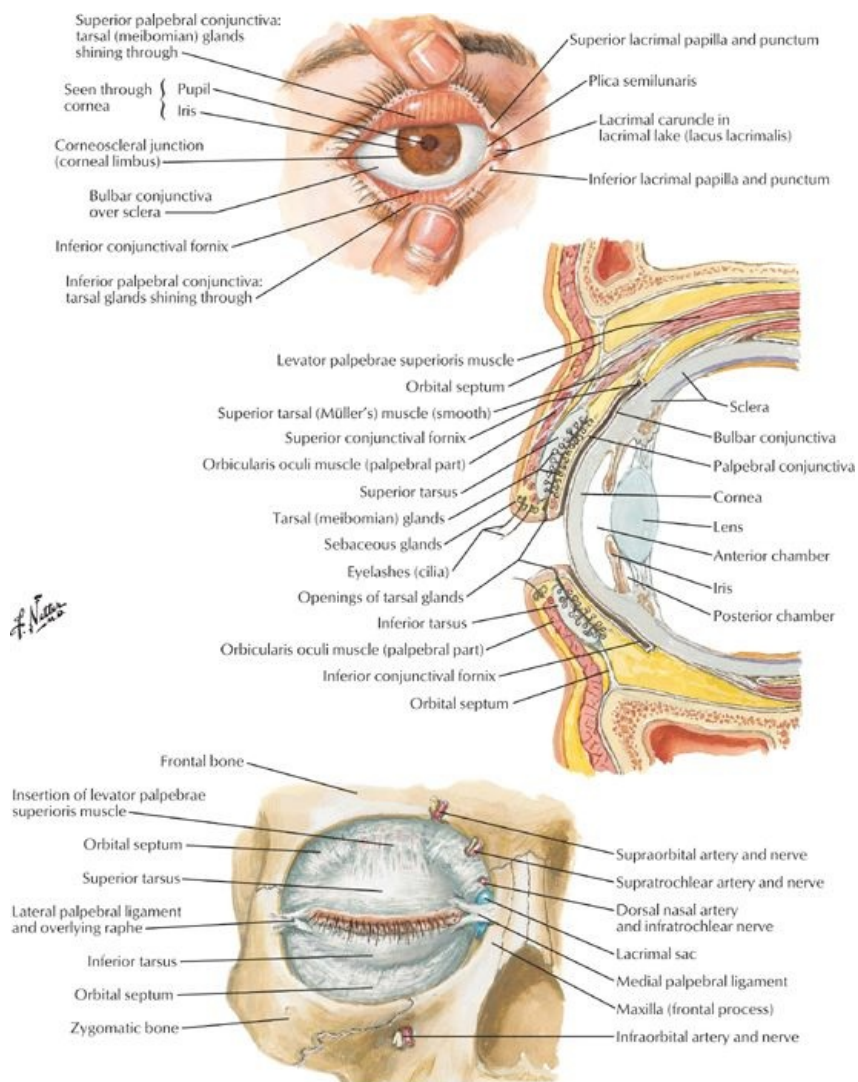
Head and Neck: Orbit and Contents

Bony Orbit

- Cavity containing and protecting five sixths of eyeball, associated muscles, nerves, and vessels.
- Opening is protected by a thin moveable fold: the eyelid.
- Supports, protects and maximizes the functions of the eye
- Pyramidal shape with apex directed posteriorly and base anteriorly
- Boundaries
 - Roof
 - Orbital plate frontal bone
 - Lesser wing sphenoid
 - Fossa for lacrimal gland found in orbital part
 - Floor
 - Orbital plate of maxilla
 - Some contributions from zygomatic and palatine bones
 - Contains inferior orbital fissure from apex to orbital margin
 - Medial wall
 - Paper thin
 - Orbital plate of ethmoid bone
 - Some contributions from frontal, lacrimal, and sphenoid bones
 - Indented by lacrimal fossa for lacrimal sac
 - Lateral wall
 - Frontal process of zygomatic bone
 - Greater wing of sphenoid
 - Apex
 - Lesser wing of sphenoid
 - Contains optic canal medial to superior orbital fissure
- Foramina of the orbital cavity

Foramen	Location	Structures Transmitted
Supraorbital groove	Supraorbital margin	Supraorbital nerve and blood vessels
Infraorbital groove and canal	Orbital plate of maxilla (floor)	Infraorbital nerve and blood vessels
Nasolacrimal canal	Medial wall	Nasolacrimal duct
Inferior orbital fissure	Between greater wing sphenoid and maxilla	Maxillary nerve Zygomatic branch maxillary nerve Ophthalmic vein Sympathetic nerves
Superior orbital fissure	Between greater and lesser wings sphenoid	Lacrimal nerve Frontal nerve Trochlear nerve Oculomotor nerve Abducent nerve Nasociliary nerve Superior ophthalmic vein
Optic canal	Lesser wing sphenoid	Optic nerve Ophthalmic artery
Zygomatofacial foramen	Lateral wall	Zygomatofacial nerve
Zygomatotemporal foramen	Lateral wall	Zygomatotemporal nerve
Anterior ethmoidal foramen	Ethmoid bone	Anterior ethmoidal nerve
Posterior ethmoidal foramen	Ethmoid bone	Posterior ethmoidal nerve

Eyelids and Lacrimal Apparatus



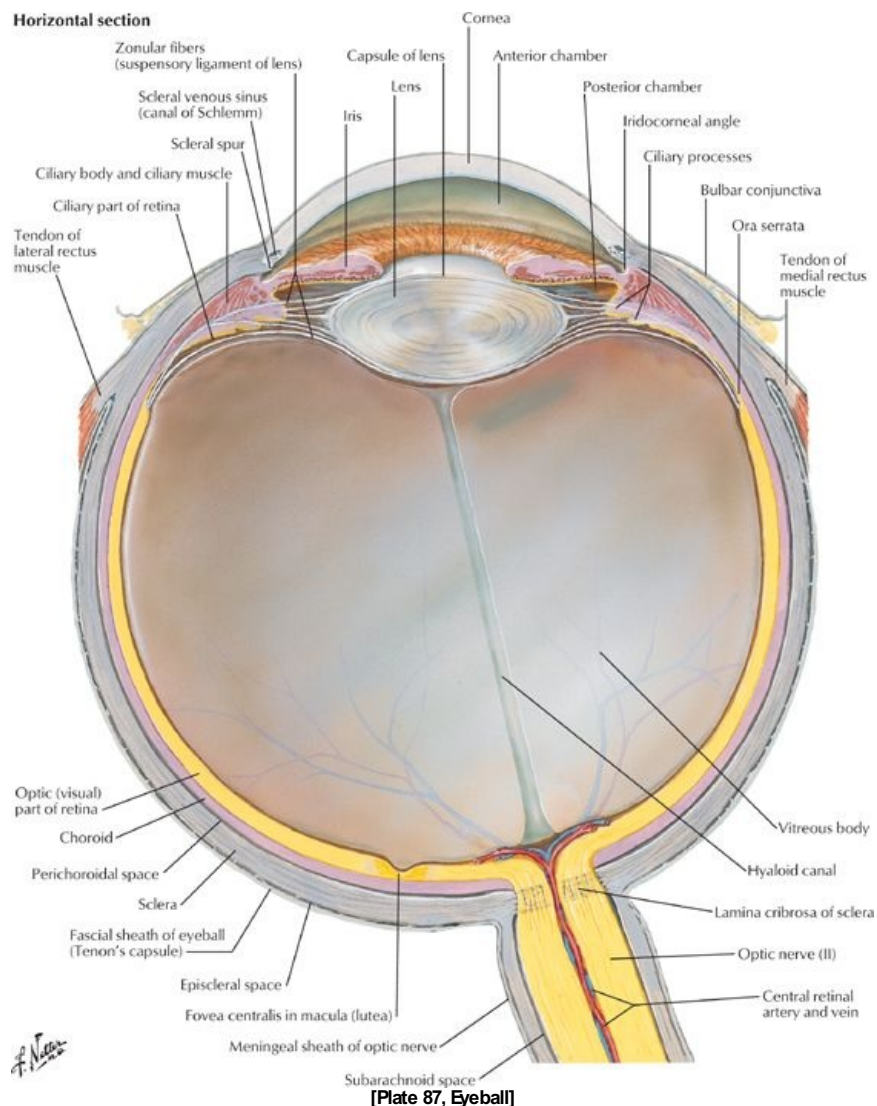
[Plate 81, Eyelids]

page 51
page 52

- Eyelids and tears (lacrimal fluid) protect cornea and eyeball from dust and particulate matter.
- Eyelids
 - Two moveable folds of skin that cover the eye anteriorly
 - Protect the eye from injury and excessive light and keep the corneas moist.
 - Eyelids separated by an elliptical opening, the palpebral fissure.
 - Covered by thin skin externally and palpebral conjunctiva internally
 - Palpebral conjunctiva continuous with bulbar conjunctiva of eyeball
 - Lines of reflection of palpebral conjunctiva onto eyeball are deep recesses: superior and inferior conjunctival fornices
 - Strengthened by plates of dense connective tissue: tarsal plates
 - Tarsal glands embedded in plates
 - Produce a lipid secretion
 - a. Lubricates edge of eyelids to prevent them from sticking together
 - b. Barrier for lacrimal fluid
 - Medial palpebral ligaments
 - a. Attach tarsal plates to medial margin of orbit
 - b. Orbicularis oculi attaches to this ligament
 - Lateral palpebral ligaments attach tarsal plates to lateral margin of orbit
 - Orbital septum from tarsal plates to margins of orbit, continuous with periosteum of bony orbit
 - Skin around the eyes devoid of hair except for eyelashes
 - Are arranged in double or triple rows on the free edges of the eyelids
 - Ciliary glands associated with eyelashes: sebaceous glands.
 - Muscles of the eyelids
 - Orbicularis oculi
 - Levator palpebrae superioris
- Lacrimal apparatus
 - Functions
 - Secretes tears
 - Prevents desiccation of cornea and conjunctiva
 - Lubricates eye and eyelid
 - Antibacterial

- Consists of
 - Lacrimal glands
 - Lacrimal ducts
 - Lacrimal canaliculi
 - Nasolacrimal ducts
- Lacrimal gland
 - Lies in fossa for lacrimal gland in superolateral orbit
 - Consists of two parts
 - a. Larger orbital
 - b. Smaller palpebral
 - c. Divided by expansion of tendon of levator palpebrae superioris
 - Twelve lacrimal ducts open from deep surface of gland into superior conjunctival fornix
 - Secrete lacrimal fluid upon stimulation by parasympathetic secretomotor fibers from CN VI
- Lacrimal canaliculi
 - Drain tears from lacrimal lake at medial angle of eye
 - Drain to lacrimal sac
- Lacrimal sac drains to nasal cavity via nasolacrimal duct

Contents of the Orbit



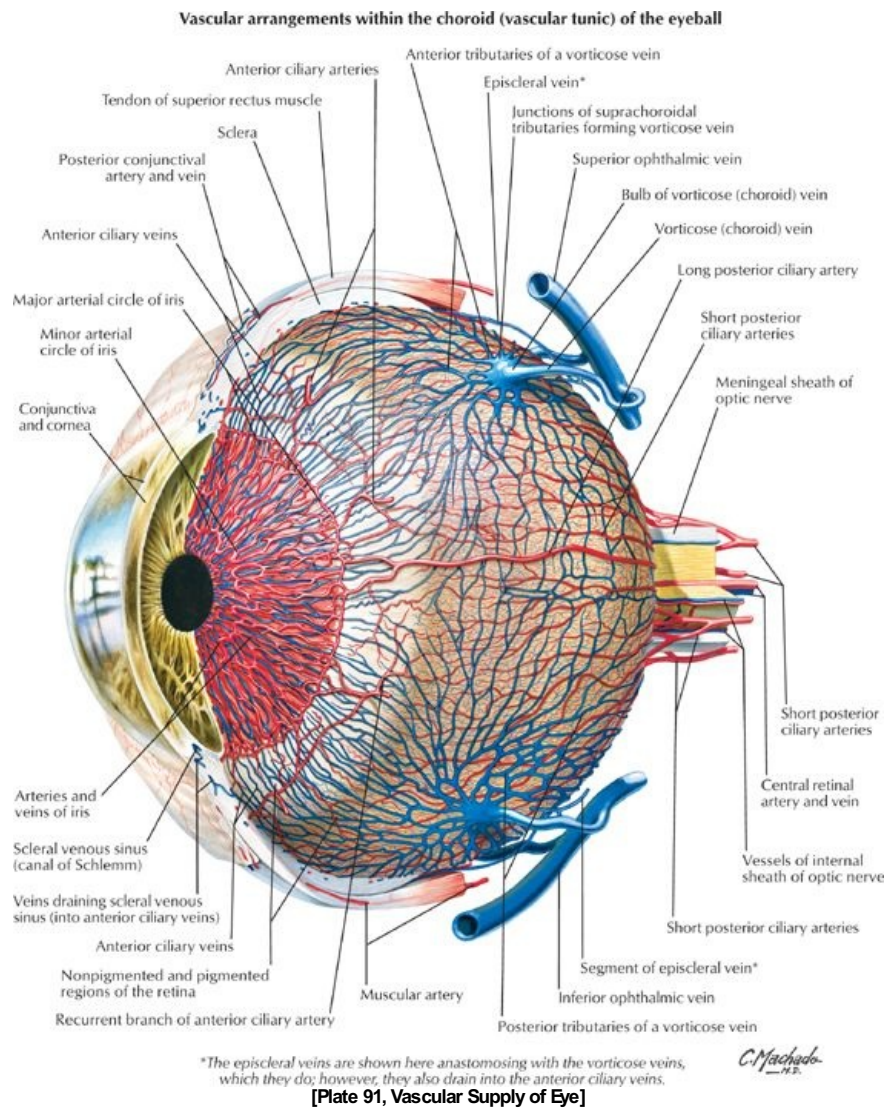
page 52
page 53

- Eyeball
 - Surrounded by fascial sheath (Tenon's capsule)
 - From optic nerve to junction of cornea and sclera
 - Forms socket
 - Pierced by tendons of extraocular muscles
 - Three layers
 - Outer fibrous = sclera and cornea
 - Middle vascular = choroid, ciliary body and iris
 - Inner pigmented and nervous = retina
 - Fibrous coat

- Intrinsic (intraocular) muscles
 - Ciliary muscle
 - Constrictor pupillae of iris
 - Dilator pupillae of iris
- Extrinsic (extraocular) muscles
 - Six muscles
 - Four arise from common tendinous ring surrounding optic canal and part of superior orbital fissure
 - Lateral and medial rectus (2)
 - a. Lie in same horizontal plane
 - b. Rotate eyeball laterally and medially, respectively
 - Superior and inferior rectus (2)
 - a. Lie in same vertical plane
 - b. Pull eyeball superiorly and inferiorly, respectively
 - Inferior oblique
 - a. Works with superior rectus
 - b. Pulls eyeball superiorly and laterally
 - Superior oblique
 - a. Works with inferior rectus
 - b. Pulls eyeball inferiorly and laterally
 - Sheathed by reflection of fascial sheath around eyeball (Tenon's capsule)
 - Medial and lateral check ligaments
 - a. Triangular expansions of sheath of medial and lateral rectus muscles
 - b. Attached to lacrimal and zygomatic bones
 - c. Limit abduction and adduction
 - Suspensory ligament
 - a. Union of check ligaments with fascia of inferior rectus and inferior oblique muscles
 - b. Forms sling that supports eyeball

Muscle	Origin	Insertion	Action	Nerve Supply	Blood Supply
Extrinsic muscles of the eyeball					
Superior rectus	Common tendinous ring	Superior aspect of eyeball, posterior to the corneoscleral junction	Elevates, adducts, and medially rotates eyeball	Oculomotor nerve (CN III) -superior division	Ophthalmic artery
Inferior rectus	Common tendinous ring	Inferior aspect of eyeball, posterior to corneoscleral junction	Depresses, adducts, and laterally rotates eyeball	Oculomotor nerve (CN III) -superior division	Ophthalmic artery
Medial rectus	Common tendinous ring	Medial aspect of eyeball, posterior to corneoscleral junction	Adducts eyeball	Oculomotor nerve (CN III) -superior division	Ophthalmic artery
Lateral rectus	Common tendinous ring	Lateral aspect of eyeball, posterior to corneoscleral junction	Abducts eyeball	Abducent nerve (CN VI)	Ophthalmic artery
Superior oblique	Body of sphenoid, above optic foramen and medial origin of superior rectus	Passes through trochlea and attaches to superior sclera between superior and lateral recti	Abducts, depresses, and medially rotates eyeball	Trochlear nerve (CN IV)	Ophthalmic artery
Inferior oblique	Anterior floor of orbit lateral to nasolacrimal canal	Lateral sclera deep to lateral rectus	Abducts, elevates, and laterally rotates eyeball	Oculomotor nerve (CN III) -inferior division	Ophthalmic artery
Muscles of eyelids					
Levator palpebrae superioris	Lesser wing of sphenoid, anterior to optic canal	Superior tarsal plate	Raises upper eyelid	Oculomotor nerve (CN III) -superior division	Ophthalmic artery
Orbicularis oculi	Medial orbital margin, palpebral ligament, and lacrimal bone	Skin around orbit palpebral ligament, upper and lower eyelids	Closes eyelids	Facial nerve (CN VII)	Facial and superficial temporal arteries
Intrinsic muscles of the eye					
Sphincter pupillae (iris)	Circular smooth muscle of the iris that passes around pupil		Constricts pupil	Parasympathetic fibers via oculomotor (CN III)	Ophthalmic artery
Dilator pupillae (iris)	Ciliary body		Dilates pupil	Sympathetic fibers via long ciliary nerves (CN V ₁)	Ophthalmic artery
Ciliary muscles	Corneoscleral junction	Ciliary body	Controls lens shape (accommodation)	Parasympathetic fibers via short ciliary nerves (CN III)	Ophthalmic artery

Vasculature of the Orbit



page 55
page 56

- Arteries
 - Ophthalmic artery (main supply)
 - Enters orbit through optic canal
 - Lateral to optic nerve
 - Infraorbital artery from maxillary
 - Branches of ophthalmic artery
 - Supraorbital
 - Supratrochlear
 - Lacrimal
 - Dorsal nasal
 - Ethmoidal-anterior and posterior
 - Central artery of the retina
 - a. Branch of ophthalmic
 - b. Runs within dural sheath of optic nerve
 - c. Emerges at optic disc and branches over retina
 - Posterior ciliary arteries
 - a. Branches of ophthalmic
 - b. Six short to choroid
 - c. Two long to ciliary plexus
 - Anterior ciliary
 - a. From muscular branches of ophthalmic
 - b. Anastomoses with posterior ciliary arteries

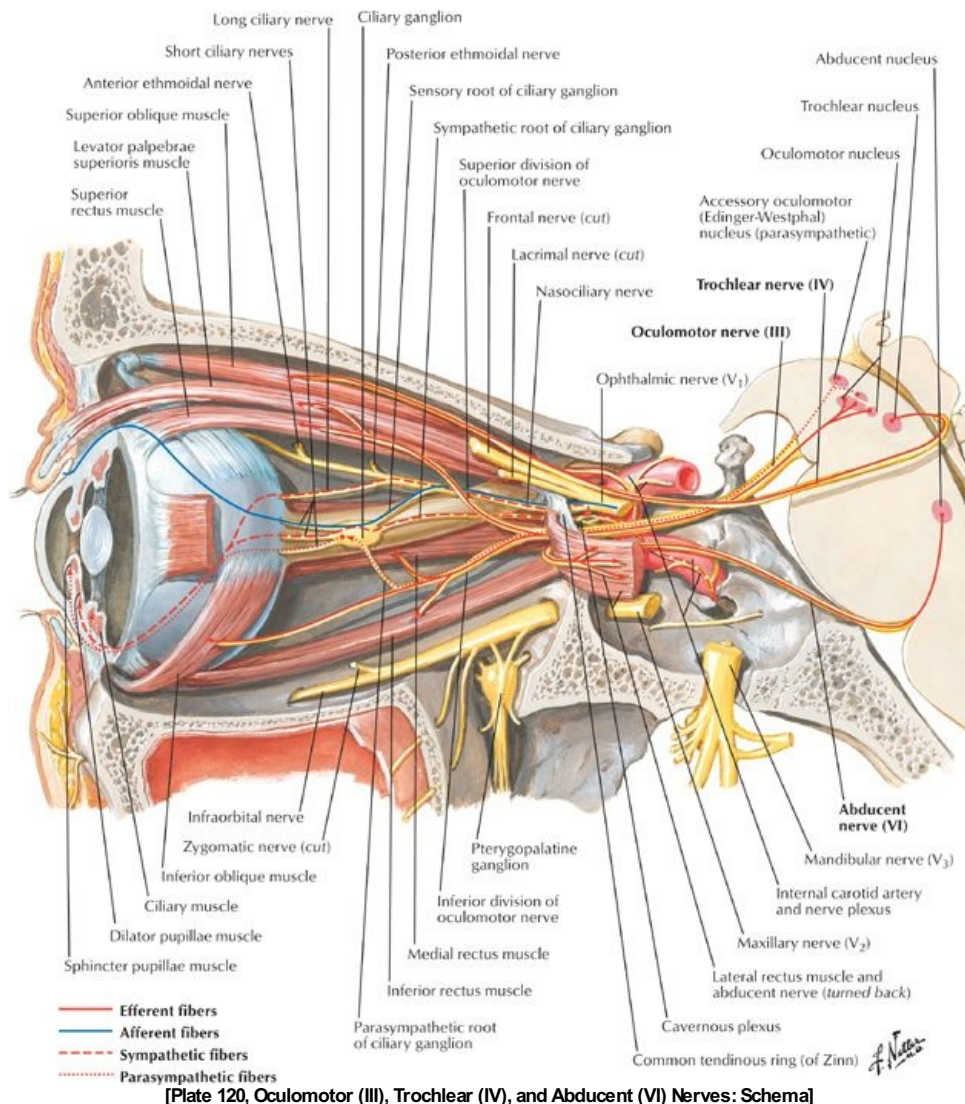
Distribution of Branches of Ophthalmic Artery

Branch (in order of origin)	Structures Supplied
Lacrimal artery	Lacrimal gland, conjunctive and eyelids

Short posterior ciliary arteries	Choroid layer of retina to supply visual layer
Long posterior ciliary artery	Ciliary body and iris
Central artery of retina	Retina
Supraorbital artery	Forehead and scalp
Posterior ethmoidal artery	Posterior ethmoid air cells
Anterior ethmoidal artery	Anterior and middle ethmoid air cells, frontal sinus, nasal cavity, skin of nose
Dorsal nasal	Dorsum of nose
Supratrochlear	Forehead and scalp

- Venous drainage
 - Superior ophthalmic vein
 - Formed by union of supraorbital and angular vein of face
 - Receives blood from anterior and posterior ethmoid, lacrimal and muscular branches, central vein of retina, and upper two vorticoses veins of retina
 - Drains to cavernous sinus
 - Inferior ophthalmic vein
 - Forms in floor of orbit
 - Receives blood from lower extraocular muscles and lower two vorticoses veins of retina
 - Drains to cavernous sinus
 - Communicates with pterygoid plexus of veins through inferior orbital fissure

Innervation of the Orbit



- Optic nerve
 - Formed from axons of retinal ganglion cells
 - Exits through optic canal
 - Fibers from medial half of each retina cross at optic chiasm and join uncrossed fibers from lateral half of contralateral retina to form

-
- optic tract
 - Oculomotor nerve (CN III)
 - Runs in lateral wall of cavernous sinus
 - Enters orbit through superior orbital fissure
 - Contains parasympathetic fibers to sphincter pupillae and ciliary muscles
 - Supplies
 - Levator palpebrae superioris
 - Superior rectus
 - Medial rectus
 - Inferior rectus
 - Inferior oblique
 - Trochlear nerve (CN IV)
 - Runs in lateral wall of cavernous sinus
 - Passes through superior orbital fissure
 - Supplies superior oblique muscle
 - Abducent nerve (CN VI)
 - Courses through cavernous sinus
 - Enters orbit via superior orbital fissure
 - Innervates lateral rectus muscle
 - Branches of the ophthalmic nerve (CN V₁)
 - Lacrimal nerve to lacrimal gland
 - Frontal nerve
 - Divides into supraorbital and supratrochlear
 - Supplies upper eyelid, forehead, and scalp
 - Nasociliary nerve and its branches
 - Infratrochlear to eyelids, conjunctiva, and nose
 - Anterior and posterior ethmoidal nerves to sphenoid and ethmoid sinuses and anterior cranial fossa
 - Long ciliary nerves to dilator pupillae
 - Short ciliary nerves
 - Branches from ciliary ganglion
 - Carry parasympathetic and sympathetic fibers
 - Innervate ciliary body and iris

FACTS & HINTS

High-Yield Facts

Clinical Points

page 57
page 58

General Testing of Extraocular Muscles

- Extraocular muscles act as synergists and antagonists and are responsible for multiple movements of the eye.
- It can be difficult to test each eye muscle individually.
- A generalist, however, can gain a general idea of extraocular muscle (or nerve) impairment by checking the ability of individual muscles to elevate or depress the globe with the eye abducted or adducted, thereby aligning the globe with the pull (line of contraction) of the muscle
- Ask patient to "Follow my finger with just your eyes" and move your finger in the form of the letter H.
- Superior rectus is tested by moving your finger superiorly and medially to the eye (to counteract the interaction of the inferior oblique)
 - a. Inferior rectus is tested by moving your finger inferiorly and medially to the eye (to counteract the interaction of the superior oblique)
 - b. The medial and lateral rectus muscles are tested by moving your finger medially and laterally to the eye.
 - c. The inferior oblique is tested by moving your finger superiorly and laterally to the eye
 - d. The inferior oblique is tested by moving your finger inferiorly and laterally to the eye.
- Remember that because all the muscles are involved in the continuous movement of the eye, it is difficult to isolate the action of just one with absolute clinical certainty via this test.

Clinical Points

Cataract

- Most common clinical condition of the eye worldwide
- Involves opacification or cloudiness of the lens
- Risk factors include: smoking, age, alcohol, diabetes, steroid use, and exposure to ultraviolet (UV) rays
- Treatment involves surgical removal of the lens
- Eyesight is corrected with an implant, glasses, and/or contact lens

Clinical Points

Glaucoma

- One of most common cause of blindness world wide
- Build-up of pressure in anterior and posterior chambers of the eye
- Usually a result of resistance to outflow of aqueous humor via angle of eye and through canal of Schlemm
- Results in compression of neural layer of retina
- Leads to visual field defects and ultimately blindness
- Increased intraocular pressure classified as open or closed angle
 - a. Open angle-develops gradually with blocking of canal of Schlemm or obstruction of angle
 - b. Closed angle-occurs rapidly when iris and lens block passage of aqueous humor through pupil

Clinical Points

Orbital "blow-out" Fractures

- Medial and inferior walls of orbit are very thin, so a blow to the eye can fracture the orbit
- Indirect trauma that displaces walls is called a "blow-out" fracture
- Fractures of medial wall may involve ethmoid and sphenoid sinuses
- Fracture of the floor may involve the maxillary sinus
- Fractures can result in intraorbital bleeding
- Blood puts pressure on eyeball, causing exophthalmos
- Blood and orbital structures can herniate into maxillary sinus

Clinical Points

page 58
page 59

Conjunctivitis

- Common condition often referred to as "pink eye"
- An inflammation of the conjunctiva
- Symptoms include redness, irritation, and watering of the eyes and sometimes discharge and itching
- Can be triggered by infection
 - a. Highly contagious
 - b. Caused by bacteria or viruses
 - c. Sexually transmitted diseases (STDs), such as gonorrhoea and chlamydia, can cause it
 - d. Viral conjunctivitis is common with several viral infections and can arise as a result of or during a common cold or flu
- Can be triggered by allergies
 - a. More frequently occurs in children with other allergic conditions, e.g., hay fever, animal fur
 - b. Typically affects both eyes at the same time
- Can be triggered by an external irritant
 - a. Can be caused by pollutants such as traffic fumes, smoke
 - b. Can be caused by chemicals such as soap, chlorine

Mnemonics

68 / 425

Memory Aids

Formula for the innervation of extraocular muscles:
LR6-SO4
Rest 3
LR6 L <i>ateral R</i> <i>ectus</i> → CN VI (abducent)
SO4 S <i>uperior O</i> <i>blique</i> → CN IV (trochlear nerve)
Rest: Remaining 4 muscles → CN III (oculomotor)
<i>Superior rectus</i>
<i>Inferior rectus</i>
<i>Medial rectus</i>
<i>Inferior Oblique</i>

10 Ear

STUDY AIMS

At the end of your study, you should be able to:

- Define the external, middle, and inner ear
- Describe the anatomical features of the external ear
- Describe the tympanic membrane (ear drum)
- Describe the walls of the middle ear
- Outline the structures located within the middle ear
- Understand the transmission of sound through the middle ear
- Describe the bony labyrinth and its components
- Describe the membranous labyrinth and its components
- Understand the organization of the semicircular canals and their relationship to equilibrium
- Understand the organization of the Organ of Corti and its relationship to hearing
- Understand how sound is perceived

GUIDE

Head and Neck: Ear

Ear

- Is divided into three parts
 - External ear
 - Auricle
 - External acoustic meatus
 - Middle ear
 - Tympanic cavity and its contents
 - Epitympanic recess
 - Inner ear
 - Vestibulocochlear organ
 - Membranous labyrinth
 - Bony labyrinth
- Functions are equilibrium (balance) and hearing

External Ear

page 60
page 61

- Auricle or pinna
 - Skin-covered elastic cartilage
 - Collects sound and directs it to external auditory meatus
 - Features
 - Deep depression: concha
 - Lobule: earlobe
- External auditory (acoustic) meatus
 - From the deepest part of the concha to the tympanic membrane
 - Through the tympanic part of the temporal bone
 - Lateral one third is cartilaginous and lined with normal skin
 - Medial two thirds are bony and lined with thin skin continuous onto tympanic membrane
 - Ceruminous glands (wax producing) and sebaceous glands found in subcutaneous tissue of lateral one third
- Tympanic membrane
 - Forms medial wall external ear, lateral wall of middle ear
 - Oval and semitransparent
 - Covered with thin skin externally and mucous membrane internally
 - Has shallow, cone-like depression at its center (seen otoscopically) with the umbo at the center of the depression
 - Lateral process (handle) of the malleus embedded in tympanic membrane and tip extends to the umbo on the internal surface
 - Pars tensa
 - Part of membrane below handle of malleus
 - Contains circular and radial fibers
 - Pars flaccida
 - Part of membrane above handle of malleus
 - Contains no fibers
 - Moves in response to air vibrations
 - Transmits vibrations to auditory ossicles of middle ear via handle of malleus

Middle Ear

page 61
page 62

- Contained within petrous part of temporal bone
- Includes tympanic cavity and epitympanic recess
- Is connected anteriorly with nasopharynx by pharyngotympanic tube (auditory canal)
- Contains
 - Auditory ossicles (bones of middle ear)
 - Malleus (hammer)
 - Incus (anvil)
 - Stapes (stirrups)
 - Stapedius and tensor tympani muscles
 - Chorda tympani nerve
 - Tympanic plexus (nerves)
- Walls of tympanic cavity
 - Roof
 - Thin bone-tegmen tympani
 - Separates tympanic cavity from middle cranial fossa
 - Floor
 - Bony
 - Separates tympanic cavity from superior bulb of internal jugular vein
 - Medial wall
 - Separates tympanic cavity from inner ear
 - Features
 - a. Promontory: round projection overlying basal turn of cochlea
 - b. Oval window into which footplate of stapes fits-covered by secondary tympanic membrane

- c. Fenestra cochlea or round window
 - o Anterior wall
 - Separates tympanic cavity from carotid canal
 - Superiorly has opening of auditory tube and canal for tensor tympani
 - o Posterior wall
 - Superiorly, aditus (opening) to mastoid antrum, connecting to mastoid air cells
 - Between posterior wall and aditus, prominence of canal of facial nerve
 - Pyramidal eminence
 - a. Tiny cone-shaped prominence
 - b. Contains proximal attachment of stapedius muscle
 - o Lateral wall
 - Tympanic membrane
 - Lateral wall of epitympanic recess
 - Handle of malleus
- Ossicles
 - o Chain of bones across tympanic cavity
 - o Extend from tympanic membrane to oval window on medial wall
 - Handle of malleus attaches to tympanic membrane and head articulates with incus
 - Incus articulates with head of malleus and end of long limb with stapes
 - Head of stapes articulates with long limb of incus and base (foot-plate) fits into oval window on medial wall
 - o Increase the force but decrease amplitude of vibrations from tympanic membrane
- Auditory (pharyngotympanic) tube
 - o Formerly called Eustachian tube
 - o = Communication between middle ear and nasopharynx
 - o Allow equalisation of atmospheric pressure in middle ear
 - o Actively opened by coordinated contractions of levator and tensor veli palatine muscles
- Muscles
 - o Function to dampen movement of auditory ossicle
 - o Tensor tympani
 - o Stapedius
- Nerves
 - o Chorda tympani
 - Branch of facial nerve (cranial nerve [CN] VII)
 - Emerges from facial canal through canaliculus in posterior wall of middle cavity
 - Carries taste fibers to anterior two thirds of tongue
 - Crosses medial surface of neck of malleus
 - Exits anteriorly via canaliculus to petrotympanic fissure
 - o Tympanic plexus
 - On the promontory of the medial wall
 - Contributions from tympanic branch of glossopharyngeal (CN IX)
 - Twigs from internal carotid plexus
 - Twig from facial nerve
 - Supplies
 - a. Mucous membrane of tympanic cavity
 - b. Mastoid antrum
 - c. Mastoid air cells
 - d. Auditory tube

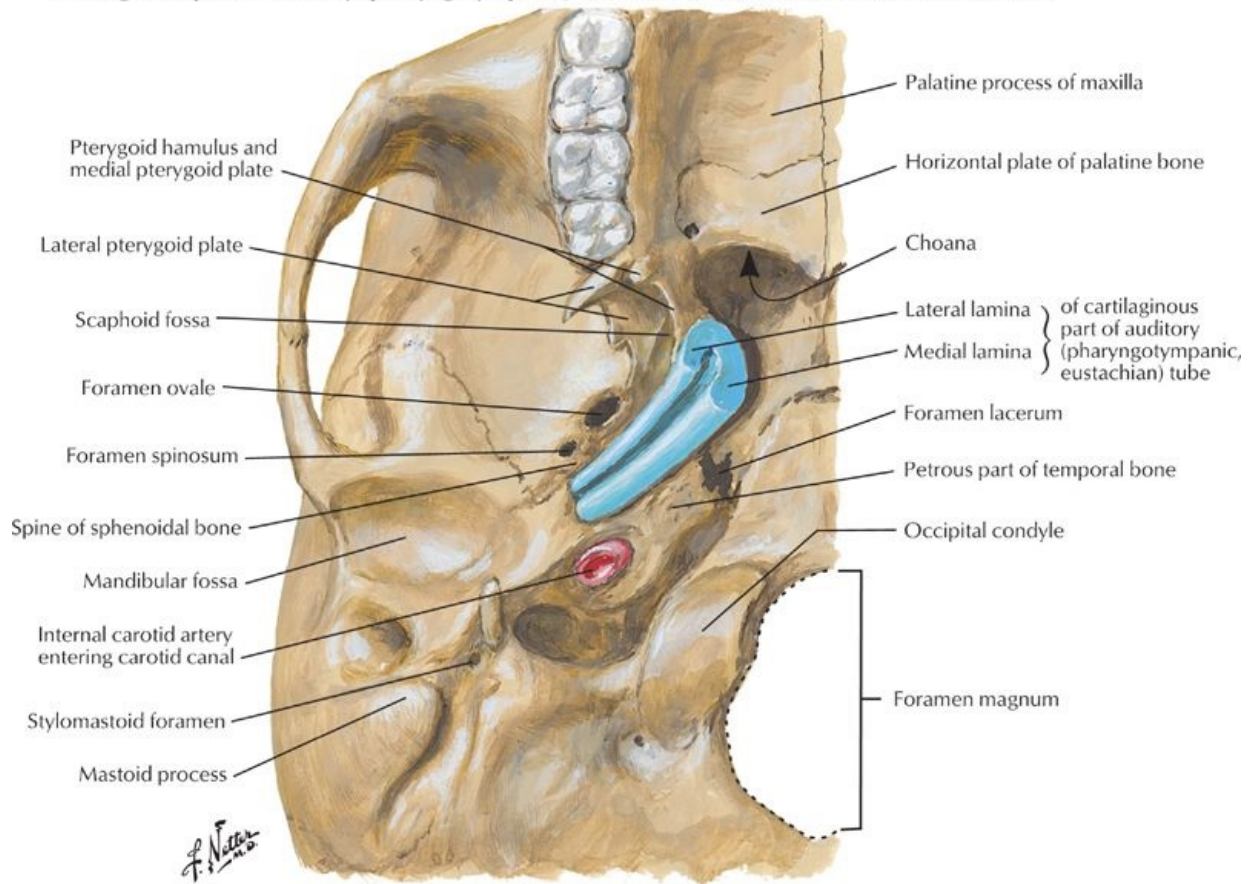
Inner Ear

page 62
page 63
page 63
page 64

- Concerned with the reception of sound and maintenance of balance
- Buried within petrous portion of temporal bone
- Membranous labyrinth suspended within bony labyrinth
- Bony labyrinth
 - o Occupies lateral region of petrous ridge of temporal bone
 - o = Space filled with perilymph
 - o Surrounded by bony capsule harder than petrous bone
 - o Cochlea
 - Concerned with hearing
 - Contains the membranous cochlear duct
 - Consists of
 - a. Spiral canal
 - b. Bony core, the modiolus
 - Canal spirals around modiolus
 - Basal turn forms promontory of medial wall of tympanic cavity
 - o At basal turn, bony labyrinth communicates with subarachnoid space above jugular foramen via cochlear aqueduct
 - o Vestibule
 - Small oval chamber
 - Contains membranous utricle and saccule
 - Oval window is on lateral wall
 - Continuous with
 - a. Cochlea anteriorly
 - b. Semicircular canals posteriorly
 - Communicates with posterior cranial fossa via aqueduct of vestibule
 - a. Extends to posterior surface of petrous ridge of temporal bone

- b. Contains membranous endolymphatic duct
 - o Semicircular canals
 - Anterior, posterior, and lateral
 - Set at right angles to each other in three planes
 - Lie posterosuperior to vestibule
 - Each opens into vestibule
 - Swelling at one end of each canal: ampulla
 - Contain membranous semicircular ducts
- Membranous labyrinth
 - o Collection of ducts and sacs
 - o Suspended within bony labyrinth
 - o Filled with endolymph
 - o Vestibular labyrinth
 - Utricle
 - a. Has specialized area of sensory epithelium: macula
 - b. Hair cells in macula innervated by vestibular division of vestibulocochlear nerve (CN VIII)
 - c. Hairs respond to tilting of head and linear acceleration and deceleration
 - Sacculle
 - a. Communicates with utricle
 - b. Continuous with cochlear duct
 - c. Contains macula, identical in structure and function to that of utricle
 - Semicircular ducts
 - a. Within semicircular canals
 - b. Each has ampulla at one end
 - c. Ampullary crest in each ampulla senses movement of endolymph in plane of duct
 - d. Hair cells in crest innervated by vestibular division of vestibulocochlear nerve (CN VIII)
 - e. Detect rotational (tilting) movements of head
 - o Cochlear labyrinth
 - Spiral ligament suspends cochlear duct from external wall of spiral canal
 - Cochlear duct
 - a. Triangular in shape
 - b. Filled with endolymph
 - c. Spans spiral canal, dividing it into two channels, each filled with perilymph
 - d. Two channels: scala tympani and scala vestibule, meet at apex of cochlea (helicotrema)
 - e. Third, middle channel = cochlear duct
 - f. Roof of duct = vestibular membrane
 - g. Floor of duct = basilar membrane
 - Spiral organ of Corti
 - a. Found on basilar membrane
 - b. Covered by gelatinous tectorial membrane
 - c. Contains hair cells-tips embedded in tectorial membrane
 - d. Hair cells innervated by cochlear division of vestibulocochlear nerve (CN VIII)
- Propagation of sound
 - o Initiated by sound waves
 - Transmitted as vibrations by ossicles
 - Stapes vibrates in oval window
 - Creates waves of pressure in perilymph of vestibule
 - Waves ascend in spiral canal in scala vestibule
 - Transfer to scala tympani at helicotrema
 - Pass down scala tympani to round window
 - Dissipated via secondary tympanic membrane in round window to air of middle ear cavity
 - o Reception of sound
 - Deformation of cochlear duct by pressure waves in perilymph
 - Stimulates hair cells of spiral organ embedded in tectorial membrane
 - Base of spiral organ receives high frequency sounds and apex receives low-frequency sounds
- Internal auditory (acoustic) meatus
 - o 1 cm long tiny canal in petrous ridge of temporal bone
 - o Opening in posteromedial aspect of ridge in posterior cranial fossa
 - o Transmits facial (CN VI) and vestibulocochlear (CN VIII) nerve

Cartilaginous part of auditory (pharyngotympanic, eustachian) tube at base of skull: inferior view



[Plate 98, Auditory (Pharyngotympanic, Eustachian) Tube]

FACTS & HINTS

High-Yield Facts

Clinical Points

Otitis externa

- Defined as an inflammation or infection of the external ear
- Also called swimmer's ear
- Usually bacterial in origin
- Pathogens include pseudomonas aeruginosa and staphylococcus aureus
- Patient may present with itchiness, a sensation of having the ear blocked, and pain
- Ear on examination is painful, erythematous, and may be discharging pus
- Treatment is with topical antibiotics (eardrops)

Clinical Points

Otitis media

- Defined as an inflammation of the middle ear
- Also known as glue ear
- Most common in children between the ages of 6 months and 2 years
- Symptoms include: pulling or rubbing the ears because of ear pain, fever, fussiness, or irritability, fluid leaking from the ear, changes in appetite or sleeping patterns, trouble hearing
- Usually to the result of bacterial infection
- On examination with an otoscope, the ear drum looks dull with loss of the cone of light
- Commonly treated with antibiotics
- With frequent reoccurring infections and evidence of hearing loss or speech delay, small tubes called tympanostomy tubes are placed in the eardrums to ventilate the area behind the eardrum and keep the pressure equalized to atmospheric pressure in the middle ear.

Clinical Points

Weber Test and Rinne Test for Hearing

page 64
page 65

Weber Test

- With a Weber test of hearing, a tuning fork is struck and placed on the patient's forehead
- The patient is asked to report in which ear the sound is heard louder
- This test cannot confirm normal hearing, because hearing defects affecting both ears equally will produce an apparently normal test result
- A Rinne test should be done at the same time

Rinne Test

- A Rinne test compares perception of sounds, as transmitted by air or by sound conduction through the mastoid
- This is achieved by placing a vibrating tuning fork (512 Hz) initially on the mastoid, then next to the ear and asking which sound is loudest
- A patient with normal hearing with a positive Rinne on both sides would hear the sound equally in both ears or may not even hear it at all if the room is noisy enough to mask the subtle sound of the tuning fork
- A patient with a unilateral (one-sided) conductive hearing loss would hear the tuning fork loudest in the affected ear (conduction through bone is more effective than the normal route through the outer and middle ear)

11 Meninges and Brain

STUDY AIMS

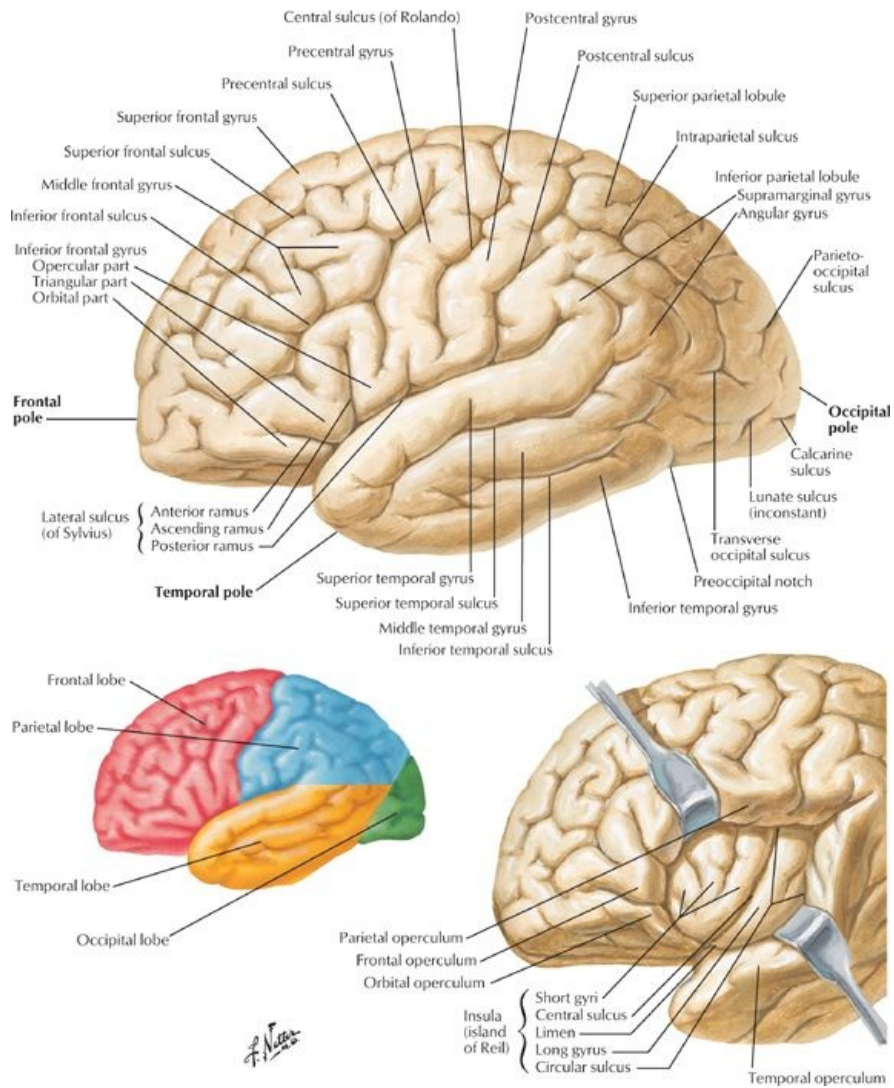
At the end of your study, you should be able to:

- Outline the gross structure of the brain
- State the lobes of the cerebral hemispheres and their function
- Describe the layers of the meninges
- Outline the venous drainage of the brain and the key venous sinuses
- Describe the formation of cerebrospinal fluid

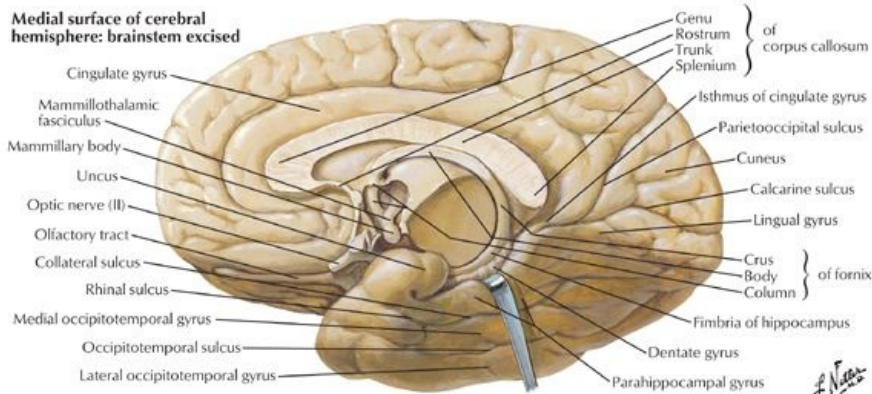
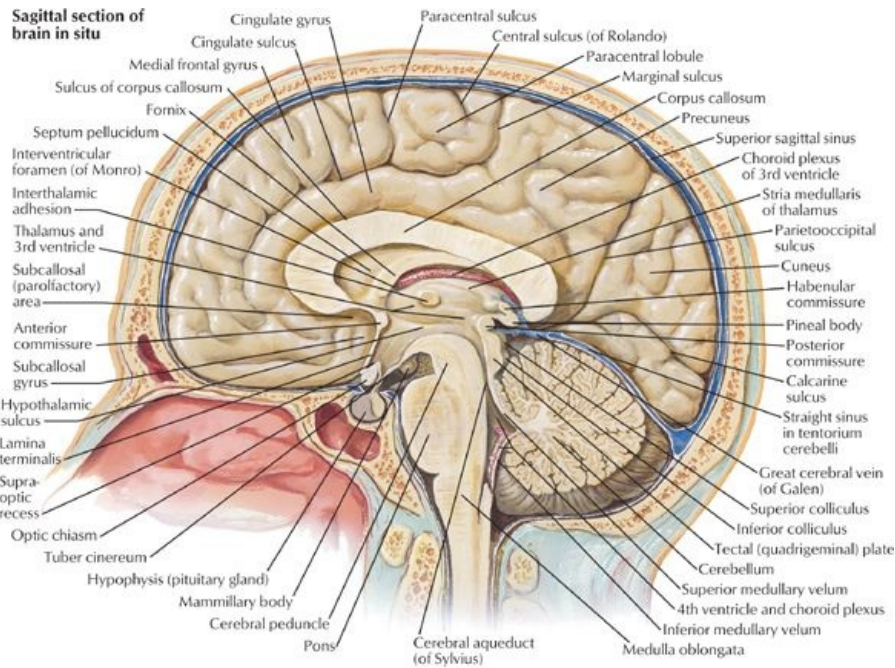
GUIDE

Head and Neck: Meninges and Brain

Brain



[Plate 104, Cerebrum: Lateral Views]



[Plate 105, Cerebrum: Medial Views]

page 66
page 67

- Is composed of six regions for purposes of description
- (1) Cerebral hemispheres (cerebrum)
 - Largest part of brain
 - Occupy anterior and middle cranial fossae
 - Two, separated by longitudinal cerebral fissure
 - Connected by transverse fiber bundle at base of longitudinal fissure: corpus callosum
 - Cavity in each hemisphere = ventricle
 - Composed of four lobes:
 - Frontal lobe:
Involved in higher mental function
Contains speech and language centers
 - Parietal lobe:
Initiates movement
Involved in perception
 - Temporal lobe:
Involved in memory, hearing, and speech
 - Occipital lobe:
Contains visual cortex
 - Each lobe marked by folds (gyri) and grooves (sulci)
- (2) Diencephalon
 - Composed of
 - Epithalamus
 - Thalamus
 - Hypothalamus
 - Surrounds third ventricle of brain between right and left halves
- (3) Mdbrain (mesencephalon)
 - At junction of middle and posterior cranial fossae
 - Contains narrow canal: cerebral aqueduct
- (4) Pons
 - Found in anterior region of posterior cranial cavity

- Contains cavity that contributes to fourth ventricle
- (5) Medulla oblongata
 - Lies in posterior cranial fossa
 - Continuous with spinal cord
 - Contains inferior portion of fourth ventricle
- (6) Cerebellum
 - Dorsal to pons and medulla
 - Beneath posterior cerebrum
 - Composed of two lateral hemispheres connected by vermis in midline
 - Important in
 - Maintenance of balance, posture and coordination
 - Timing and strength of contraction of muscles

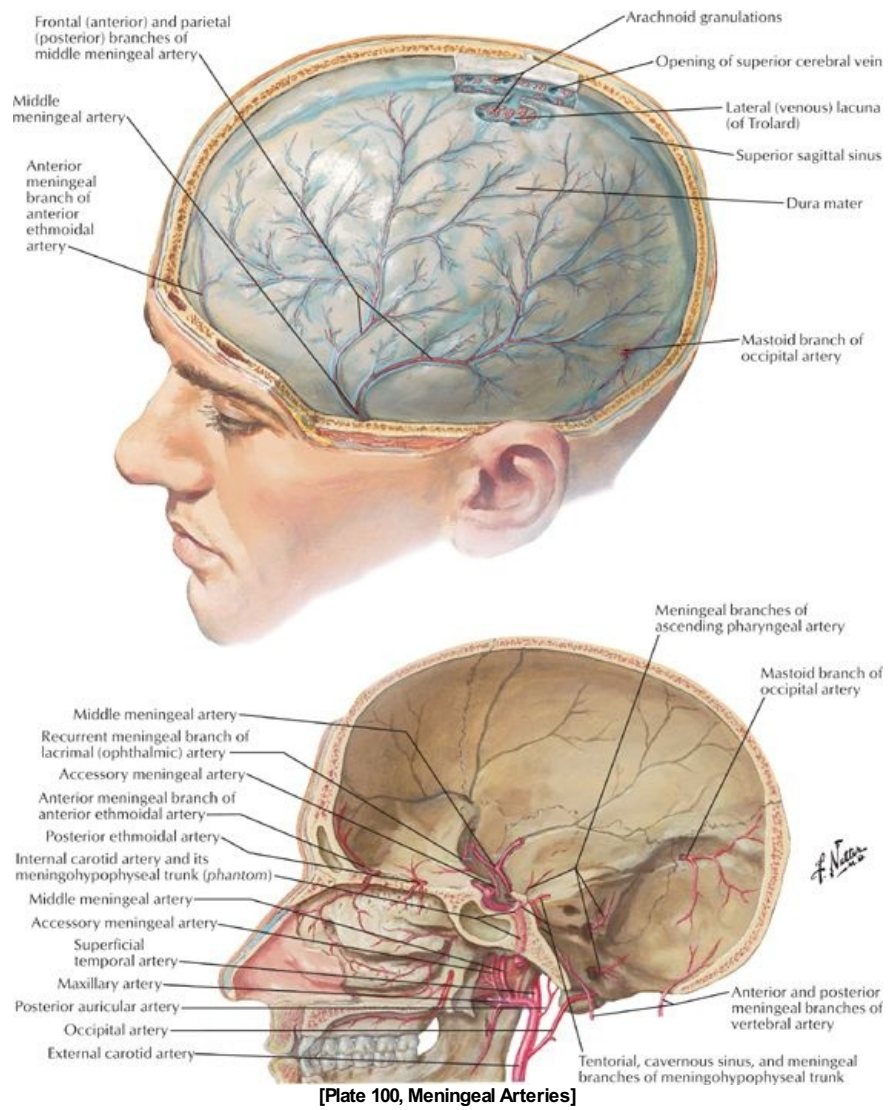
Brainstem

- Parts of brain hidden by cerebral hemispheres and cerebellum
- Contains third and fourth ventricles and cerebral aqueduct
- Composed of
 - Midbrain
 - Pons
 - Medulla oblongata
- Contains masses of gray matter, many of which are sensory and motor nuclei of cranial nerves

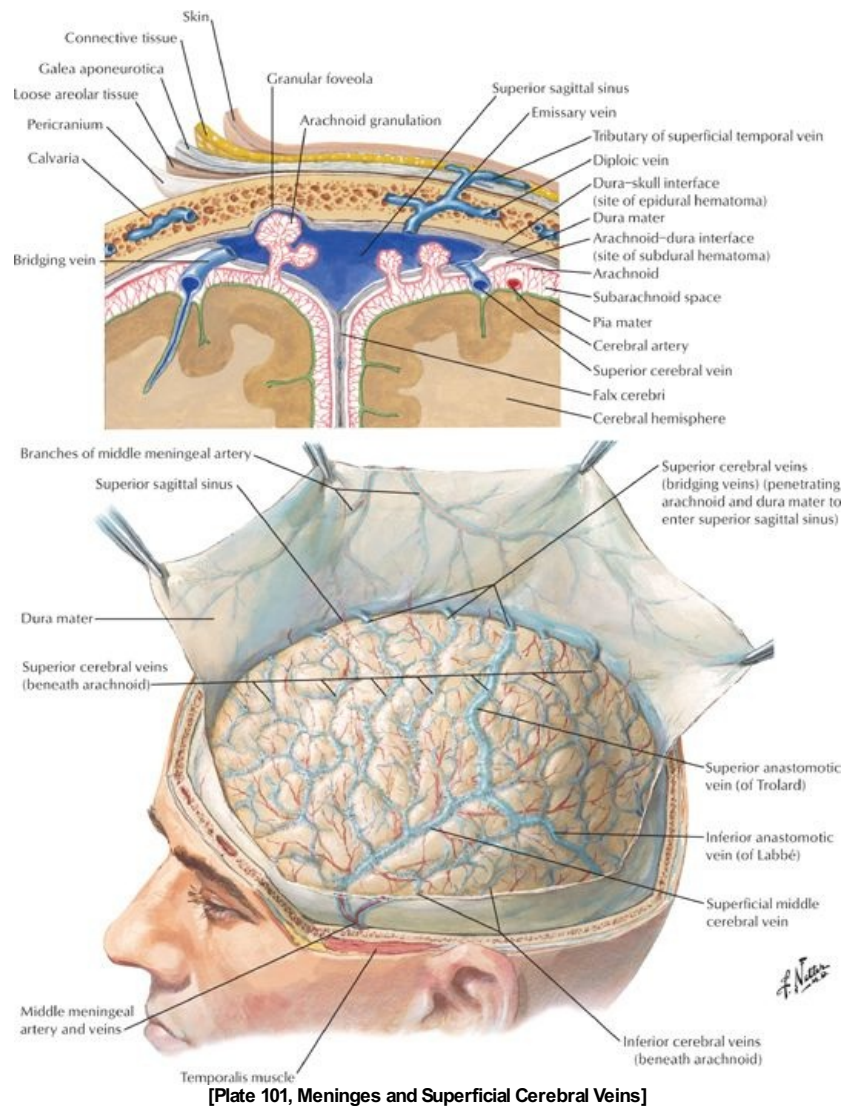
Arterial supply to the brain

- Internal carotid artery
 - Arises in neck
 - Enters cranial cavity via carotid canals
 - Terminates as
 - Anterior cerebral artery-connected to opposite artery by anterior communicating artery
 - Middle cerebral artery
 - Joined to posterior cerebral artery near termination by posterior communicating artery
- Vertebral arteries
 - Ascend through transverse foramina of C1-C6 cervical vertebrae
 - Perforate dura
 - Enter posterior cranial fossa via foramen magnum
 - Unite at posterior pons to form basilar artery
 - Ascends on clivus
 - Divides into two posterior cerebral arteries
 - Unite with internal carotid artery via posterior communicating arteries
- Circle of Willis
 - Cerebral arterial circle
 - Composed of
 - Anterior communicating artery
 - Anterior cerebral arteries
 - Internal carotid arteries
 - Posterior communicating arteries
 - Posterior cerebral arteries
- Areas supplied by anterior cerebral artery
 - Medial and superior brain
 - Frontal pole
- Areas supplied by middle cerebral artery
 - Lateral brain
 - Temporal pole
- Posterior cerebral artery
 - Inferior brain
 - Occipital pole

Meninges



[Plate 100, Meningeal Arteries]



[Plate 101, Meninges and Superficial Cerebral Veins]

- Surround and protect the brain
- Are the support for arteries, veins, and venous sinuses
- Enclose the subarachnoid space
- Enclose cerebrospinal fluid (CSF)
- Are similar in name, structure, and arrangement to those around the spinal cord
- Dura mater
 - Thick fibrous layer
 - Consists of two layers (unlike the dura mater around the spinal cord)
 - Outer periosteal layer = periosteum on inner surface of calvaria
 - Inner meningeal layer
 - Tightly bound to the periosteal layer
 - Continuous with the dural of the spinal cord
- Arachnoid mater
 - Thin, nonvascular membrane
 - Loosely attached to dura mater
 - Separated from pia mater by subarachnoid space
- Pia mater
 - Adherent to brain and spinal cord
 - Highly vascular connective tissue
- Subarachnoid space
 - Real space between arachnoid and pia mater
 - Contains cerebrospinal fluid from ventricular system-cushions brain
- Subarachnoid cisterns
 - Areas where pia and arachnoid are widely separated
 - Collect large pools of CSF
 - Occur mainly at base of brain

Venous drainage of brain

- Cerebral veins
 - Superior and lateral surfaces of brain to superior sagittal sinus

- On posterior and inferior aspects of brain drain into straight, transverse, and superior petrosal sinuses
- Thin-walled and valveless
- Superior cerebellar veins to straight, transverse, and superior petrosal sinuses
- From dural venous sinuses to internal jugular vein

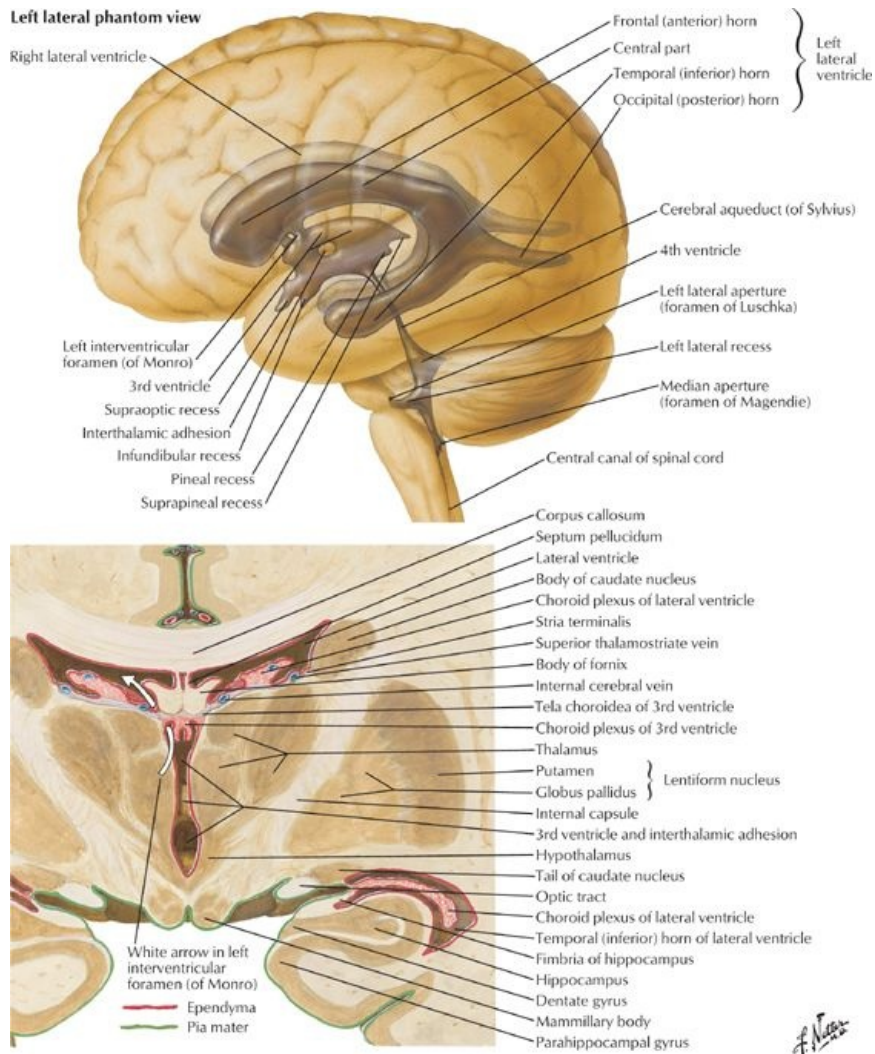
Dural infoldings

page 68
page 69

- Created by internal meningeal layer of dura mater
- Form septa that separate regions of the brain from other regions
- Falx cerebri
 - Largest of infoldings
 - Lies in longitudinal fissure
- Tentorium cerebelli
 - Second largest infolding
 - Crescent-shaped fold separating cerebral hemispheres from cerebellum
 - Attaches to
 - Anteriorly to clinoid processes of sphenoid
 - Laterally to petrous part of temporal bone
 - Posteriorly and laterally to internal occipital and parietal bones
 - Falx cerebri, which suspends tentorium
 - Tentorial notch
 - Gap in anterior border
 - Allows for passage of brain stem
- Diaphragma sellae
 - Circular sheet of dura
 - Suspended between anterior and posterior clinoid processes
 - Contains gap for passage of pituitary stalk and accompanying veins

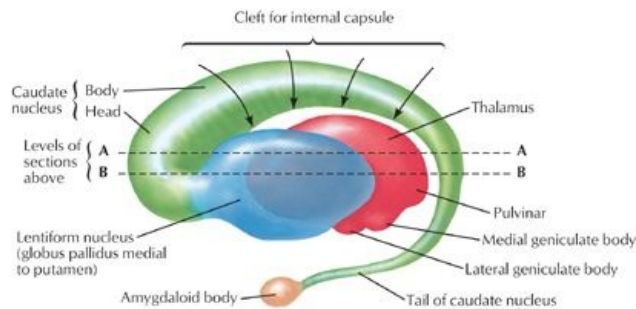
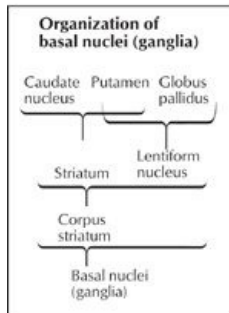
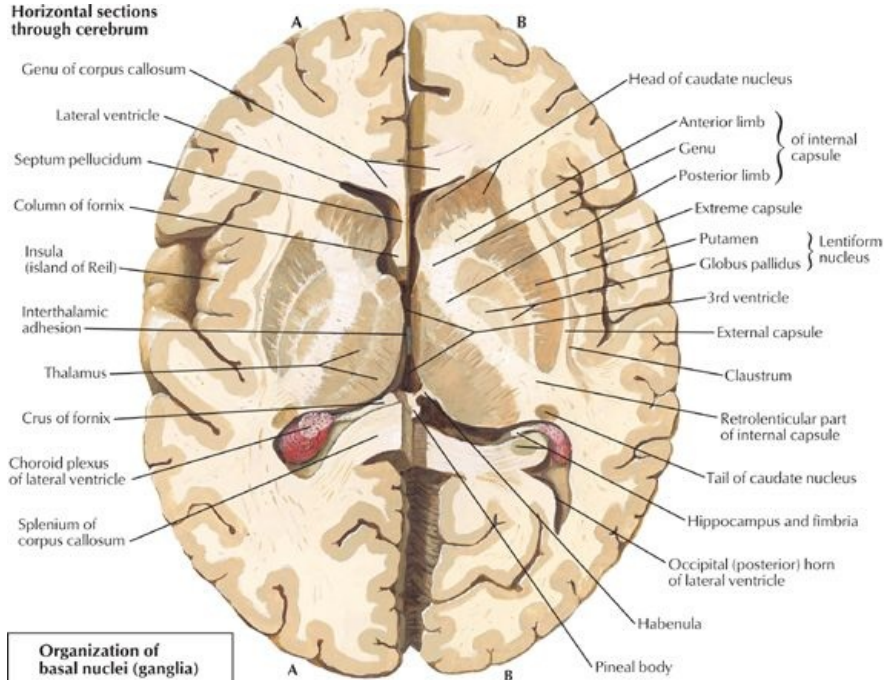
Dural venous sinuses

- Endothelium lined channels between periosteal and meningeal layers of the dura
- Thick-walled and valveless
- Formed where dura attaches
- Confluence of sinuses: where superior sagittal, straight, occipital, and transverse sinuses meet at internal occipital protuberance
- Superior sagittal sinus
 - From crista galli to confluence of sinuses
 - Communicates via slit-like openings with lateral venous lacunae
- Inferior sagittal sinus: from crista galli to straight sinus
- Straight sinus: formed by union of inferior sagittal sinus and great cerebral vein (of Galen)
- Transverse sinus
 - Drains confluence of sinuses
 - Runs along posterolateral attachment of tentorium cerebelli
 - Becomes sigmoid sinus
- Sigmoid sinus
 - Traverses jugular foramen
 - Becomes internal jugular vein
- Occipital sinus: at attached border of cerebellar falx
- Cavernous sinus
 - On either side of sella turcica
 - Is composed of a network of thin, valveless vein
 - Sinuses communicate with each other via intercavernous sinuses
 - Receives blood from
 - Superior and inferior ophthalmic veins
 - Superficial middle cerebral vein
 - Sphenoparietal sinus
 - Contains
 - Internal carotid artery
 - Oculomotor nerve (CN III)
 - Trochlear nerve (CN IV)
 - V₁ division of trigeminal nerve (CN V)
 - Abducent nerve (CN VI)
 - Sympathetic plexus around artery
- Superior petrosal sinus: from posterior ends of cavernous sinuses to transverse sinuses
- Inferior petrosal sinus: from posterior ends of cavernous sinuses to internal jugular vein
- Emissary veins connect dural sinuses with veins outside the cranium



Coronal section of brain: posterior view
 [Plate 107, Ventricles of Brain]

Horizontal sections through cerebrum



Interrelationship of thalamus, lentiform nucleus, caudate nucleus, and amygdaloid body (schema): left lateral view [Plate 109, Basal Nuclei (Ganglia)]

page 69
page 70

Sinus	Location	Comment	Drains to
Superior sagittal sinus	Upper border falx cerebri	1. Drains cerebral veins 2. Contains arachnoid villi and granulations for reabsorption CSF	Confluence of sinuses
Inferior sagittal sinus	Lower free margin falx cerebri		Joins great cerebral vein forming straight sinus
Straight sinus	Junction falx cerebri and tentorium cerebelli	Formed by union great cerebral vein with inferior sagittal sinus	Confluence of sinuses
Transverse sinus	Lateral margin tentorium cerebelli	1. Passes laterally from confluence of sinuses 2. Left is usually larger	Sigmoid sinus
Sigmoid sinus	S-shaped course in temporal and occipital bones	Continuation transverse sinus	Internal jugular vein
Cavernous sinus	Superior surface of body of sphenoid, lateral to sella turcica	1. Receives superior and inferior ophthalmic and superficial middle cerebral veins and sphenoparietal sinus 2. Contains internal carotid artery and CN III, IV, V1, and V2, sympathetic nerves	Superior and inferior petrosal sinuses
Intercavernous sinus	Runs through sella turcica	Connects cavernous sinuses	
Superior petrosal sinus	Margin tentorium cerebelli attached to petrous temporal bone	Connects cavernous sinus to transverse sinus	Transverse sinus
Inferior petrosal sinus	Medial border petrous temporal bone to jugular foramen	Connects cavernous sinus to internal jugular vein	Internal jugular vein

CSF

- Maintains balance of extracellular fluid in the brain
- Similar in content to blood

-
- Less protein
 - Different ion concentrations
 - Formed by choroids plexuses in the four ventricles of the brain
 - Are plexuses of capillaries that project into the lateral, third and fourth ventricles
 - Circulates through ventricular system
 - From lateral ventricles to interventricular foramina to third ventricle
 - From third ventricle through cerebral aqueduct to fourth ventricle
 - From fourth ventricle through paired lateral apertures and a single midline aperture in the roof into subarachnoid space
 - Absorbed through arachnoid granulations into venous blood in dural venous sinuses
 - Arachnoid granulations are tufts of arachnoid villi protruding into the dural venous sinuses
 - Subarachnoid space with CSF extends into core of the tufts
 - Approximately 400 mL/day of CSF → venous circulation

page 70

page 71

Vasculature of dura

- Primarily provides blood to calvaria
- Middle meningeal artery
 - Branch of axillary artery
 - Enters through foramen spinosum
 - Has anterior and posterior branches
- Meningeal branches of
 - Ophthalmic arteries
 - Occipital arteries
 - Vertebral arteries
- Venous drainage: meningeal veins
 - Accompany meningeal arteries
 - Occur in pairs
 - Frequently torn in skull fractures
 - Middle meningeal veins drain to pterygoid venous plexus

FACTS & HINTS

High-Yield Facts

Clinical Points

Meningitis

- Inflammation of the arachnoid and pia mater
- Can be caused by drugs or malignancy, but usually by pathogenic bacteria
- Infection can be due to meningococcal or pneumococcal bacteria
- Patient may present with fever, nonblanching purpuric rash, neck stiffness, and photophobia
- Mortality from bacterial causes can be up to 30%
- Diagnosis is by examination and lumbar puncture

Hydrocephalus

- Caused by excess cerebrospinal fluid (CSF) production or, more likely, by abnormal absorption
- Classified as obstructive, communicating or normal pressure
- Blockage usually in cerebral aqueduct by narrowing
- Can be a result of tumor, hemorrhage, and infection
- Communicating blocks movement of CSF from ventricles
- Can be caused by absence of arachnoid granulations or subarachnoid hemorrhage
- Dilates ventricles, thins cerebral cortex, separates bones of calvaria in infants

Brain tumors

- Twenty-five percent of all brain tumors arise from a different site (metastasis)
- Common sites of original tumor include: breast, bronchus, prostate, thyroid, and kidney
- Primary brain tumors can be benign, such as meningiomas and neurofibromas, or malignant, such as astrocytomas and oligodendrogliomas
- Can present as epilepsy, focal neurology, or signs of raised intracranial pressure
- Diagnosis is by history, examination, and computed tomography (CT) or magnetic resonance imaging (MRI) of the brain

12 Cranial and Cervical Nerves

STUDY AIMS

At the end of your study, you should be able to:

- Know the names and functions of the cranial nerves
- State the foramen through which the cranial nerves emerge from the skull
- Outline formation of the cervical plexus
- Know the sensory nerves arising from the cervical plexus and their distribution
- Know the muscles innervated by motor branches of the cervical plexus
- Understand the formation of the ansa cervicalis and know the muscles innervated by its branches
- Describe the formation of, and fibers composing, the phrenic nerve
- Know the structures innervated by the various components of the phrenic nerve

GUIDE

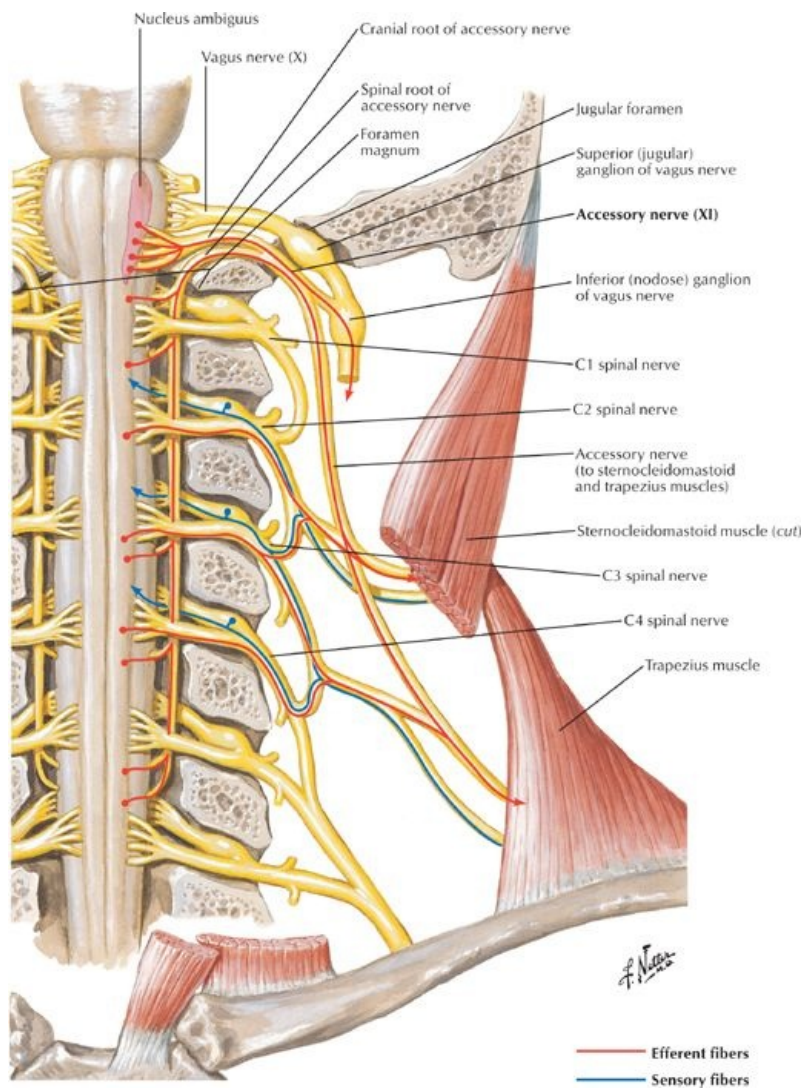
Head and Neck: Cranial and Cervical Nerves

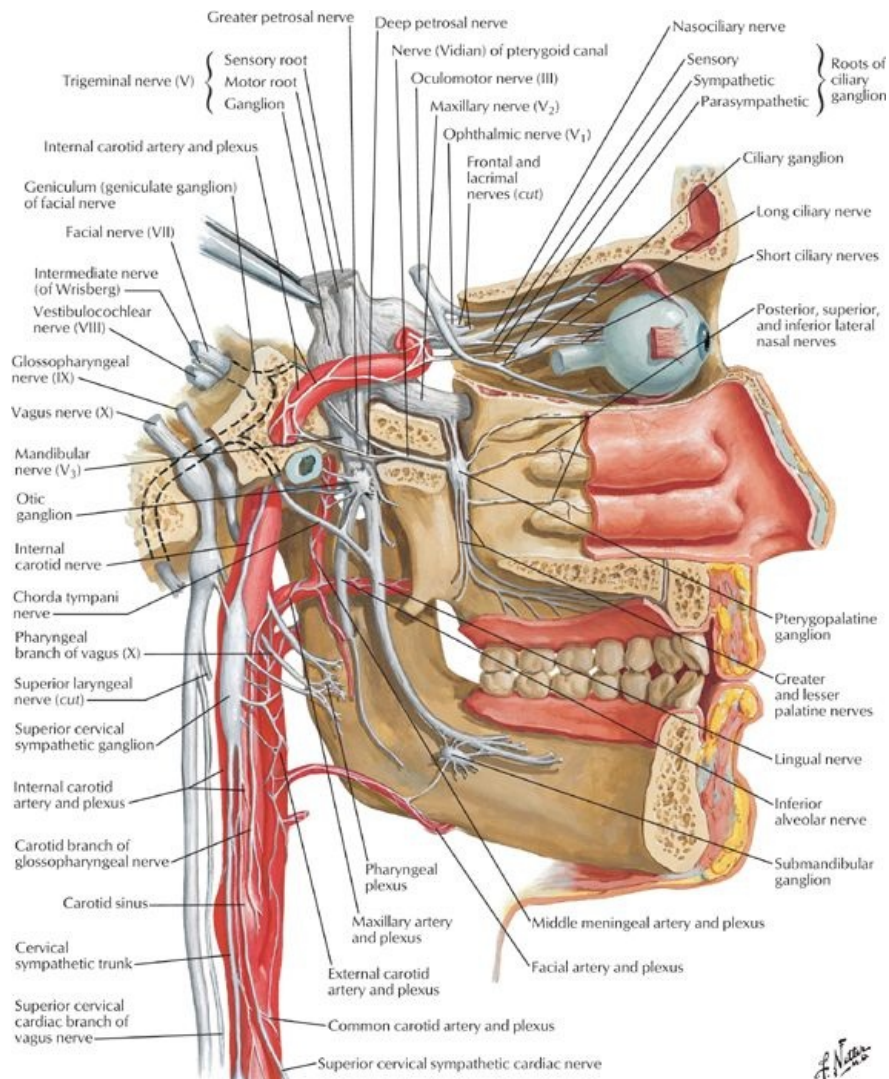
Cranial Nerves

12 pairs of cranial nerves arise from the brain, and they are identified both by their names and by Roman numerals I through XII. The cranial nerves are somewhat unique and can contain multiple functional components:

- General: same general functions as spinal nerves
- Special: functions found only in cranial nerves
- Afferent and efferent: sensory or motor functions, respectively
- Somatic and visceral: related to skin and skeletal muscle (somatic), or to smooth muscle and glands (visceral)

Hence, each cranial nerve may possess multiple functional components, such as GSA (general somatic afferents), meaning it contains nerve fibers that are sensory from the skin, not unlike those of the spinal nerve; GVE (general visceral efferents), meaning it contains motor fibers to visceral structures (smooth muscle and/or glands) like a parasympathetic fiber from the sacral spinal cord (S2-S4 gives rise to parasympathetics); or SSA (special somatic afferents), meaning it contains special sensory fibers, such as those for vision or hearing.





[Plate 130, Autonomic Nerves in Head]

page 72
page 73

Cranial Nerve	Functional Component	Cranial Opening
I Olfactory nerve	SVA (special sense of smell)	Foramina in cribriform plate
II Optic nerve	SSA (special sense of sight)	Optic canal
III Oculomotor nerve	GSE (motor to extraocular muscles) GVE (parasympathetic to smooth muscle in eye)	Superior orbital fissure
IV Trochlear nerve	GSE (motor to 1 extraocular muscle)	Superior orbital fissure
V Trigeminal nerve	GSA (sensory to face, orbit, nose, anterior tongue) SVE (motor to skeletal muscles)	three branches: ophthalmic, maxillary, and mandibular travel through multiple openings
VI Abducens nerve	GSE (motor to 1 extraocular muscle)	Superior orbital fissure
VII Facial nerve	GSA (sensory to skin of ear) SVA (special sense of taste to anterior tongue) GVE (motor to glands-salivary, nasal, lacrimal) SVE (motor to facial muscles)	Internal acoustic meatus Facial canal Stylomastoid foramen
VIII Vestibulocochlear nerve	SSA (special sense of hearing and balance)	Internal acoustic meatus
IX Glossopharyngeal nerve	GSA (sensory to posterior tongue) SVA (special sense of taste-posterior tongue) GVA (sensory from middle ear, pharynx, carotid body, and sinus) GVE (motor to parotid gland) SVE (motor to 1 muscle of pharynx)	Jugular foramen
X Vagus nerve	GSA (sensory external ear) SVA (special sense of taste-epiglottis) GVA (sensory from pharynx, larynx, and thoracic and abdominal organs) GVE (motor to thoracic and abdominal organs)	Jugular foramen

	SVE (motor to muscles of pharynx/larynx)	
XI Spinal accessory nerve	SVE (motor to 2 muscles)	Jugular foramen
XII Hypoglossal nerve	GSE (motor to tongue muscles)	Hypoglossal canal

page 73
page 74

In general, CN I and II arise from the forebrain and are really tracts of the brain for the special senses of smell and sight. CN III, IV, and VI move the extraocular skeletal muscles of the eyeball. CN V has three divisions: V₁ and V₂ are sensory, and V₃ is both motor to skeletal muscle and sensory. CN VI, IX and X are both motor and sensory. CN VIII is the special sense of hearing and balance. CN XI and XII are motor to skeletal muscle. CN III, VI, IX and X also contain parasympathetic fibers of origin (visceral), although many of the ANS fibers will "jump" onto the branches of CN V to reach their targets. The following table summarizes the types of fibers in each cranial nerve and where each passes through the cranium:

- Cranial nerves emerge through foramina or fissures in the cranium
- Twelve pairs
- Numbered in order of origin from the brain and brain stem, rostral to caudal
- Contain one or more of six different types of fibers
 - Motor fibers to voluntary muscles
 - Somatic motor fibers to striated muscles (1)
 - a. Orbit
 - b. Tongue
 - c. Neck (sternocleidomastoid and trapezius)
 - Branchial motor (or special visceral efferent fibers) to striated muscles derived from pharyngeal arches (example: muscles of mastication) (2)
 - Motor fibers to involuntary muscles = general visceral efferent (parasympathetic fibers) (3)
 - Sensory fibers
 - General visceral afferent fibers (4)
 - a. Carry sensation from viscera
 - b. Originate in carotid body, sinus, heart, lungs, and gastrointestinal tract
 - General somatic afferent fibers carrying pain, pressure, temperature, touch information (5)
 - Special sensory afferent fibers conveying taste, smell, vision, hearing, and balance (6)
- Can be sensory, motor, or mixed

Sensory Innervation of the Dura

- Dura of the cranial fossae innervated by meningeal branches of cranial and cervical nerves
- Anterior cranial fossa
 - Anterior meningeal branches of the ethmoidal nerves from ophthalmic nerves (CN V₁)
 - Meningeal branches of the maxillary nerves (cranial nerve [CN] V₂)
 - Meningeal branches of the mandibular nerves (CN V₃)
- Middle cranial fossa
 - Meningeal branches of the maxillary nerves (CN V₂)
 - Meningeal branches of the mandibular nerves (CN V₃)
- Posterior cranial fossa
 - Tentorial nerve from ophthalmic nerve (CN V₁)
 - Meningeal branches directly from C2 and C3 spinal nerves or carried by CN X (vagus) or CN XII (hypoglossal)

Cervical Plexus

page 74
page 75

- Formed from anterior rami of C1-C4 spinal nerves
- Consists of a series of loops and branches from the loops
- Lies deep to sternocleidomastoid (SCM) and anteromedial to levator scapulae and middle scalene muscles
- Cutaneous branches of the cervical plexus
 - Emerge from posterior border of SCM
 - Nerves from loop formed between anterior rami of C2 and C3
 - Lesser occipital (C2) to skin of neck and scalp posterior to auricle
 - Great auricular (C2 and C3) to skin over parotid gland, mastoid process, auricle, and between angle of mandible and mastoid process
 - Transverse cervical nerve (C2 and C3) to skin over anterior cervical region
 - Supraclavicular nerves
 - Arise from C3-C4 loop
 - Emerge from under SCM
 - Supply skin over clavicle, superior thoracic wall, and shoulder
- Motor branches
 - Are considered deep branches
 - Innervate prevertebral muscles
 - Sternocleidomastoid (C2 and C3)
 - Trapezius (C3 and C4)
 - Levator scapulae (C3 and C4)
 - Motor fibers from C1 travel with hypoglossal nerve
 - Some C1 fibers leave hypoglossal nerve and innervate
 - a. Thyrohyoid muscle
 - b. Geniohyoid muscle
 - Rest leave the hypoglossal as its descending branch

-
- Motor fibers from C1 and C2 directly innervate thyrohyoid (an infrahyoid strap muscle)
 - Motor fibers from C2, 3 form the descending cervical nerve
 - Ansa cervicalis
 - Loop formed by descending branch from hypoglossal nerve (superior root) (C1) and descending cervical nerve (inferior root) (C2,C3)
 - Branches from ansa innervate remaining infrahyoid strap muscles
 - a. Omohyoid
 - b. Sternohyoid
 - c. Sternothyroid
 - Motor fibers from C3, C4, and C5 contribute to roots of phrenic nerve
 - Phrenic nerve
 - Formed by branches of anterior rami of C3, C4, and C5 spinal nerves
 - Contains a mix of fibers
 - Sole motor supply to the diaphragm
 - Sensory fibers from the central part of the diaphragm (sensory fibers from periphery provided by intercostal nerves)
 - Sympathetic nerve fibers from the cervical sympathetic ganglia to smooth muscle of blood vessel walls

FACTS & HINTS

High-Yield Facts

Clinical Points

Facial Nerve Palsy

- Unilateral (one-sided) injury to the facial nerve or its branches
- Results in sudden weakness affecting some or all of facial muscles on affected side
- Causes include: infections such as TB, polio; brainstem lesions; tumors, such as acoustic neuromas; acute and sudden exposure of the face to cold temperatures
- Angle of mouth droops on affected side with dribbling of food and saliva
- Sad look when face is relaxed
- Lower eyelid falls away from eyeball with drying of cornea and tearing from corner of eye
- Speech affected (production of B,MP, and W sounds), because of weakened lip muscles

Trigeminal Neuralgia

- Disease affecting the sensory root of CN V
- Characterized by episodes of intense pain lasting a few seconds in areas innervated by the trigeminal nerve.
- Usually one-sided and can affect a division of CN V, usually the mandibular, maxillary nerve.
- Pain can be triggered by touching a sensitive area ("trigger point")
- The cause is not usually known
- Treatment is directed to controlling the pain.

Ocular Nerve Palsy

- Lesion of the oculomotor nerve will paralyze all extraocular muscles except the lateral rectus and the superior oblique. This leads to :
- Ptosis-drooping of the eyelid (levator palpebrae superioris)
- No constriction of the pupil in response to light (sphincter pupillae)
- Dilation of the pupil (unopposed dilator pupillae)
- Eyeball abducted and depressed ("down and out") (unopposed lateral rectus and superior oblique)
- No accommodation of the lens for near vision (ciliary muscle)

page 75
page 76

Mnemonics

Memory Aid

Names of the Cranial Nerves

"On Old Olympus Towering Tops A Few Virile Germans Viewed Ample Of Hops"		
I:	On	- Olfactory
II:	Old	- Ophthalmic
III:	Olympus	- Oculomotor
IV:	Towering	- Trochlear
V:	Tops	- Trigeminal
VI:	A	- Abducent
VII:	Few	- Facial
VIII:	Virile	- Vestibulocochlear
IX:	Germans	- Glossopharyngeal
X:	Viewed	- Vagus
XI:	Ample	- Accessory
XII:	Hops	- Hypoglossal

Memory Aid

Motor, Sensory and Mixed (Both) Cranial Nerves

"Some Say Marry Money But My Brother Says Bad Business Marry Money"		
I:	Olfactory	Sensory
II:	Optic	Sensor
III:	Oculomotor	Motor
IV:	Trochlear	Motor
V:	Trigeminal	Both
VI:	Abducent	Motor
VII:	Facial	Both
VIII:	Vestibulocochlear	Sensory
IX:	Glossopharyngeal	Both
X:	Vagus	Both
XI:	Accessory	Motor
XII:	Hypoglossal	Motor

13 Cerebral Vasculature

STUDY AIMS

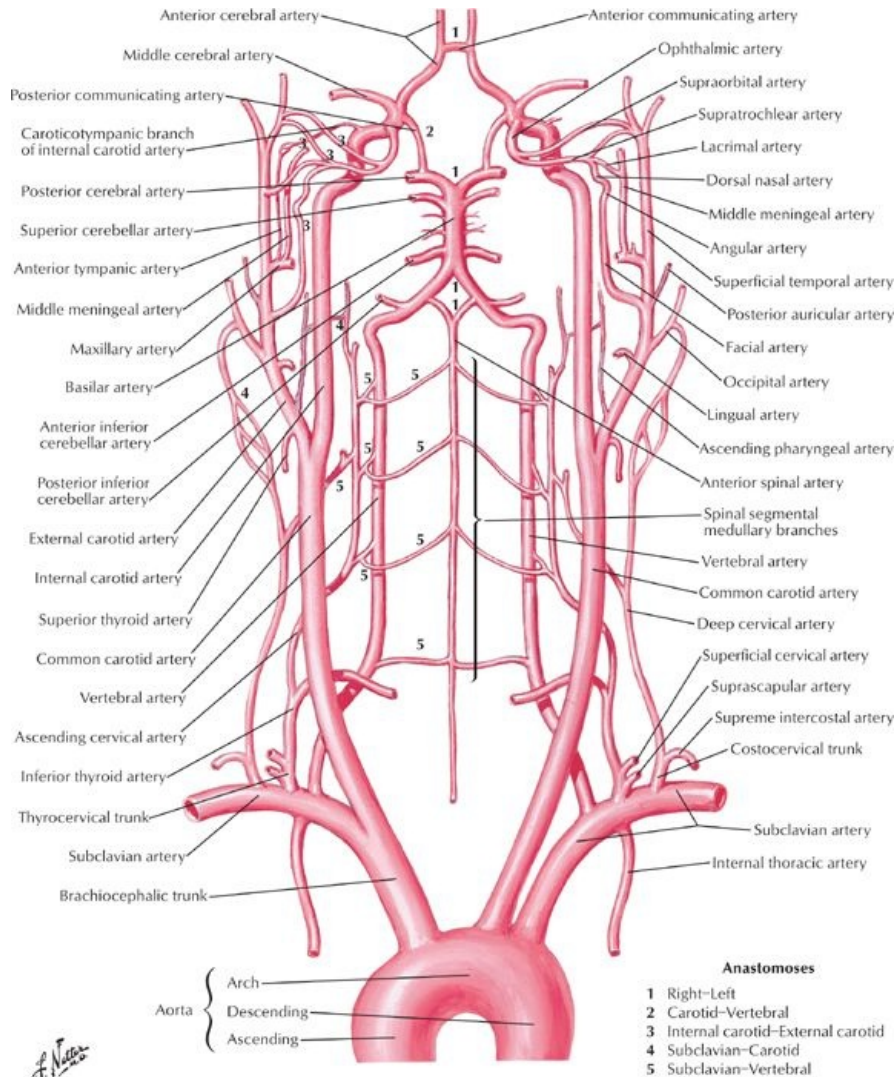
At the end of your study, you should be able to:

- State the main arteries that supply the brain
- Describe the course of the vertebral artery
- Identify the arteries contributing to the circle of Willis
- Identify the regions that each of the cerebral arteries supplies
- Describe the venous drainage of the brain
- Identify the branches of the external carotid artery and structures supplied
- Describe the division of the subclavian artery by scalene anterior and the branches given off by each part
- Understand the organization and major vessels of the venous drainage of the head and neck
- Understand the principles and organization of the lymphatic drainage of the face and head and neck
- Understand the principles and organization of the lymphatic drainage of the neck

GUIDE

Head and Neck: Cerebral Vasculature

Vascular Supply to the Brain



[Plate 136, Arteries to Brain: Schema]

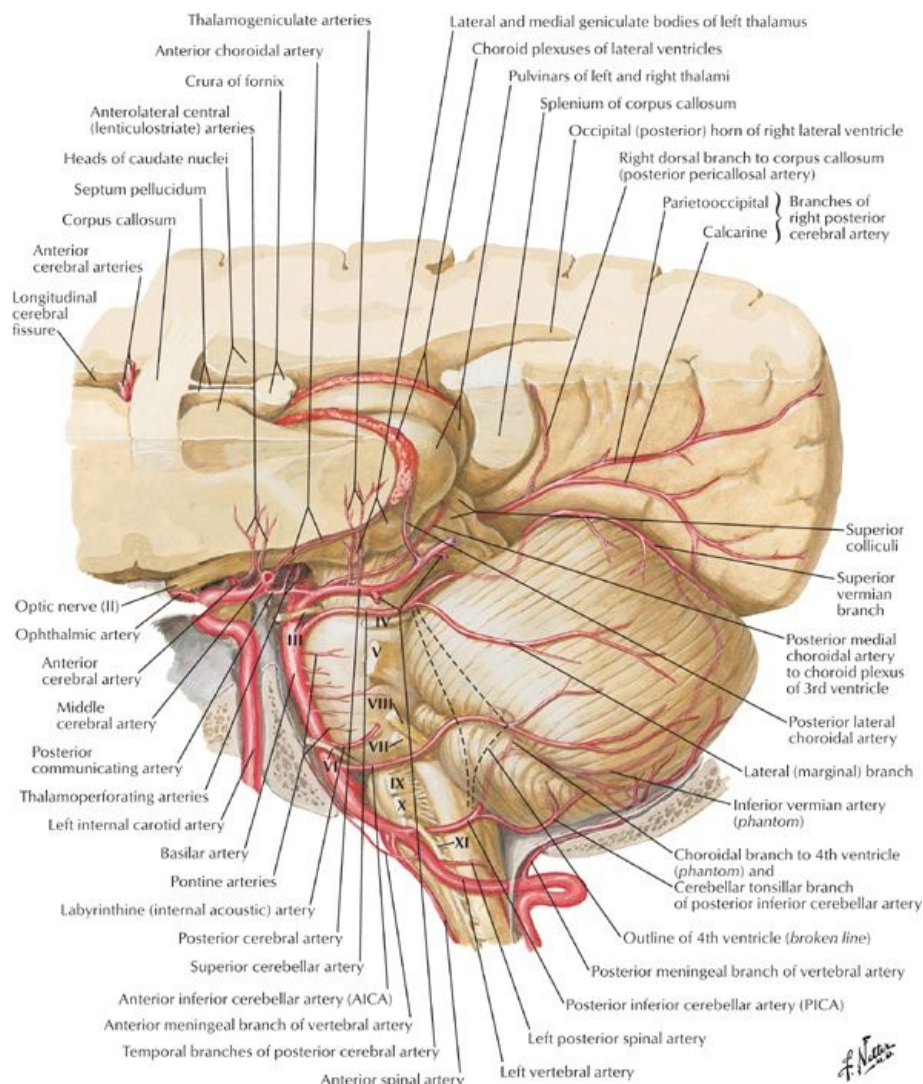
Arterial Supply

- Internal carotid arteries
 - Arise from common carotid arteries in neck
 - Begin at upper border of thyroid cartilage
 - Have no branches to face or neck
 - Enter carotid canals in temporal bone, then pass anteriorly and medially
 - Run through carotid sinuses in grooves on side of body of sphenoid
 - Terminal branches
 - Anterior cerebral artery
 - Middle cerebral artery
 - Contribute to circle of Willis
 - United to posterior cerebral artery by posterior communicating branches
 - Complete arterial circle around interpeduncular fossa
 - Provide anterior circulation of brain
- Vertebral arteries
 - First branches of subclavian arteries
 - Ascend in foramina transversaria of first six cervical vertebrae
 - Provide vascular supply to cervical spinal cord and neck
 - Pierce dura and enter cranium via foramen magnum
 - Unite as at caudal end of pons to form basilar artery
 - Ascends on clivus
 - Terminates by dividing into two posterior cerebral arteries
 - Contribute to circle of Willis

page 77
page 78

- Posterior cerebral arteries unite with anterior cerebral arteries via posterior communicating arteries
 - Provide posterior circular of brain
 - Cerebral arteries
 - Each supplies a region of the brain
 - Anterior cerebral artery
 - Medial and upper lateral surfaces of cerebral hemisphere
 - Frontal pole
 - Middle cerebral artery
 - Lower and lateral cerebral hemisphere
 - Temporal pole
 - Posterior cerebral artery
 - Inferior surface of cerebral hemisphere
 - Occipital pole
 - Cerebral arterial circle (circle of Willis)
 - Lies in subarachnoid space
 - Important anastomosis at base of brain
 - Formed by
 - Anterior communicating arteries
 - Anterior cerebral arteries
 - Internal carotid arteries
 - Posterior communicating arteries
 - Posterior cerebral arteries
 - Components supply brain via many small branches

Artery	Course and Structures Supplied
Vertebral	From subclavian artery, supplies cerebellum
Posterior inferior cerebellar	From vertebral artery, goes to posteroinferior cerebellum
Basilar	From both vertebrals, goes to brainstem, cerebellum, cerebrum
Anterior inferior cerebellar	From basilar, supplies inferior cerebellum
Superior cerebellar	From basilar, supplies superior cerebellum
Posterior cerebral	From basilar, supplies inferior cerebrum, occipital lobe
Posterior communicating	Cerebral arterial circle (of Willis)
Internal carotid (IC)	From common carotid, supplies cerebral lobes and eye
Middle cerebral	From IC, goes to lateral aspect of cerebral hemispheres
Anterior communicating	Cerebral arterial circle (of Willis)
Anterior cerebral	From IC, goes to cerebral hemispheres (except occipital lobe)



[Plate 141, Arteries of Posterior Cranial Fossa]

Venous Drainage

- Dural venous sinuses
 - Drain venous blood from superficial and deep veins of the brain
 - Sinuses drain to internal jugular vein via jugular foramen
- Veins on superior and lateral surfaces of brain drain to superior sagittal sinus
- Basal veins run laterally and dorsally around cerebral peduncle to end in great vein of Galen, which drains to straight sinus
- Veins on posterior and inferior surfaces of brain, superior cerebellar veins, and transverse sinuses drain to several sinuses
 - Straight
 - Transverse
 - Superior petrosal

Vascular Supply to Scalp, Face, and Neck

Arterial Supply

- Common carotid artery
 - Branch of aortic arch on left
 - Branch of brachiocephalic artery on right
 - Ascends neck in carotid sheath, beneath anterior border sternocleidomastoid
 - Bifurcates into internal and external carotid arteries at level thyroid cartilage
 - Internal carotid artery has no branches in the neck
- External carotid artery
 - Begins in upper border thyroid cartilage
 - Mainly supplies the face and structures external to the skull, with some branches to the neck
 - Branches
 - Ascending pharyngeal
 - a. Ascends on pharynx
 - b. Send branches to pharynx, prevertebral muscles, middle ear, and cranial meninges
 - Superior thyroid
 - a. Supplies thyroid gland, infrahyoid muscles, and sternocleidomastoid muscle

- b. Gives rise to superior laryngeal artery supplying larynx
- Lingual
 - a. Passes deep to hypoglossal nerve, stylohyoid muscle, and posterior belly of digastric
 - b. Disappears beneath hyoglossus muscle and becomes deep lingual and sublingual arteries
- Facial
 - a. Branches to tonsil, palate, and submandibular gland
 - b. Hooks around middle of mandible and enters face
- Occipital
 - a. Passes deep to posterior belly of the digastric
 - b. Grooves base of skull
 - c. Supplies posterior scalp
- Posterior auricular
 - a. Passes posteriorly between external acoustic meatus and mastoid process
 - b. Supplies muscles of region, parotid gland, facial nerve, auricle, and scalp
- Maxillary
 - a. Larger of two terminal branches
 - b. Branches supply external acoustic meatus, tympanic membrane, dura mater and calvaria, mandible, gingivae and teeth, temporal pterygoid, masseter, and buccinator muscles
- Superficial temporal
 - a. Smaller terminal branch
 - b. Supplies temporal region of scalp

Carotid Branch	Course and Structures Supplied
Superior thyroid	Supplies thyroid gland, larynx, and infrahyoid muscles
Ascending pharyngeal	Supplies pharyngeal region, middle ear, meninges, and prevertebral muscles
Lingual	Passes deep to hyoglossus muscle to supply the tongue
Facial	Courses over the mandible and supplies the face
Occipital	Supplies SCM and anastomoses with costocervical trunk
Posterior auricular	Supplies region posterior to ear
Maxillary	Passes into infratemporal fossa (described later)
Superficial temporal	Supplies face, temporalis muscle, and lateral scalp

page 79
page 80

- Subclavian artery
 - Branch of aortic arch on the left
 - From brachiocephalic trunk on the right
 - Enters neck between anterior and posterior scalene muscles
 - Supplies upper limbs, neck and brain
 - Divided for descriptive purposes into 3 parts, in relation to the anterior scalene muscle
 - First part
 - a. Medial to the anterior scalene
 - b. Has three branches
 - Second part
 - a. Posterior to the anterior scalene
 - b. Has one branch
 - Third part
 - a. Lateral to anterior scalene
 - b. Has one branch

Subclavian Branch	Course
Part 1	
Vertebral	Ascends through C6-C1 transverse foramina and enters foramen magnum
Internal thoracic	Descends parasternally to anastomose with superior epigastric artery
Thyrocervical trunk	Gives rise to inferior thyroid, transverse cervical, and suprascapular arteries
Part 2	
Costocervical trunk	Gives rise to deep cervical and superior intercostal arteries
Part 3	
Dorsal scapular	Is inconstant; may also arise from transverse cervical artery

Venous drainage

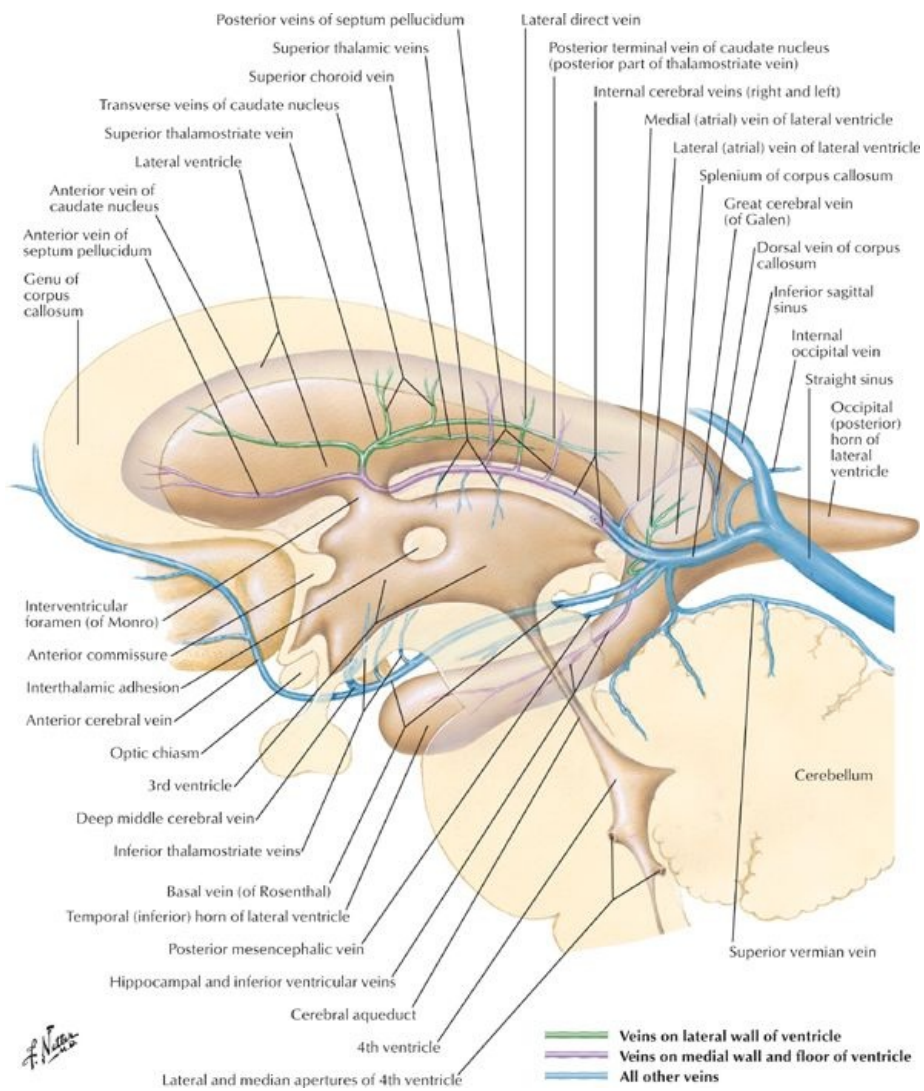
- Superficial veins
 - External jugular vein (EJV)
 - Drains most of scalp and side of face
 - Formed at angle of mandible by union of retromandibular vein with posterior auricular vein
 - Enters posterior triangle and pierces fascia of its roof
 - Descends to terminate in subclavian vein
 - Receives
 - a. Transverse cervical vein
 - b. Suprascapular vein
 - c. Anterior jugular vein
 - Anterior jugular vein

- Descends deep to investing fascia
 - Posterior to sternocleidomastoid (SCM), drains to EJV or subclavian vein
 - Commonly unites with anterior jugular on opposite side via a jugular venous arch
- Deep veins
 - Internal jugular vein (IJV)
 - Most veins in anterior neck are tributaries of IJV
 - Drains blood from brain, anterior face, cervical viscera, and deep muscles of neck
 - Begins as dilation of superior bulb just below jugular foramen
 - Runs inferiorly in carotid sheath
 - Inferior end deep to gap between two heads of SCM muscle
 - Joins subclavian vein to form brachiocephalic vein
 - Subclavian vein
 - Major vein draining upper limb
 - Passes anterior to anterior scalene muscle
 - Unites at medial border of muscle with IJV to form brachiocephalic vein
 - Tributaries of subclavian and IJV travel with arteries of same name

Lymphatic Drainage

page 80
page 81

- Drainage of face and head
 - Superficial lymphatic vessels accompany veins
 - Deep lymphatic vessels accompany arteries
 - Lymphatic drainage of face
 - Drainage from lateral face to parotid nodes
 - Drainage from upper lip and lateral lower lip to submandibular nodes
 - Drainage from chin and central lower lip to submental nodes
 - All drain to parotid, mastoid, or superficial cervical nodes
 - These drain to deep cervical nodes
- Drainage of the neck
 - Superficial drainage to superficial cervical nodes
 - Located along course of EJV
 - Also receive drainage from nodes of face and head
 - Superficial cervical nodes drain to deep cervical nodes
- Deep cervical nodes
 - Lie along course of IJV, transverse cervical artery, and accessory nerve
 - Include
 - Prelaryngeal nodes
 - Pretracheal nodes
 - Paratracheal nodes
 - Retropharyngeal nodes
 - Drain to jugular lymphatic trunk
- Jugular lymphatic trunks
 - On left
 - Joins thoracic duct on left
 - Thoracic duct enters junction of IJV and subclavian vein
 - On right
 - Empties directly into IJV or brachiocephalic vein
 - Or forms short right lymphatic duct which enters either of these vessels



[Plate 144, Subependymal Veins of Brain]

FACTS & HINTS

High-Yield Facts

Clinical Points

Stroke

- Focal neurology lasting greater than 24 hours as a result of a vascular cause
- Can be caused by an intracranial bleed
- More often (80% of cases) as a result of an infarct-ischemia, because of thrombosis or embolization from an atherosclerotic vessel
- Majority of strokes occur in the territory supplied by the internal carotid artery
- Symptoms include: hemiparesis, hemiplegia, aphasia, homonymous hemianopia
- Strokes affecting the territory supplied by the vertebral artery can present with ataxia, dysphonia, dysphagia, and homonymous hemianopia

Clinical Points

Berry Aneurysm

- Congenital defect in tunica media of arteries of circle of Willis
- Results in a saccular or Berry aneurysm
- Rupture is most common cause of subarachnoid hemorrhage
- Anterior cerebral, internal carotid, and middle cerebral most commonly affected
- Patient may present with headache, vomiting, altered consciousness, and signs of meningeal irritation

Back and Spinal Cord

page 81
page 82

14 Topographic Anatomy

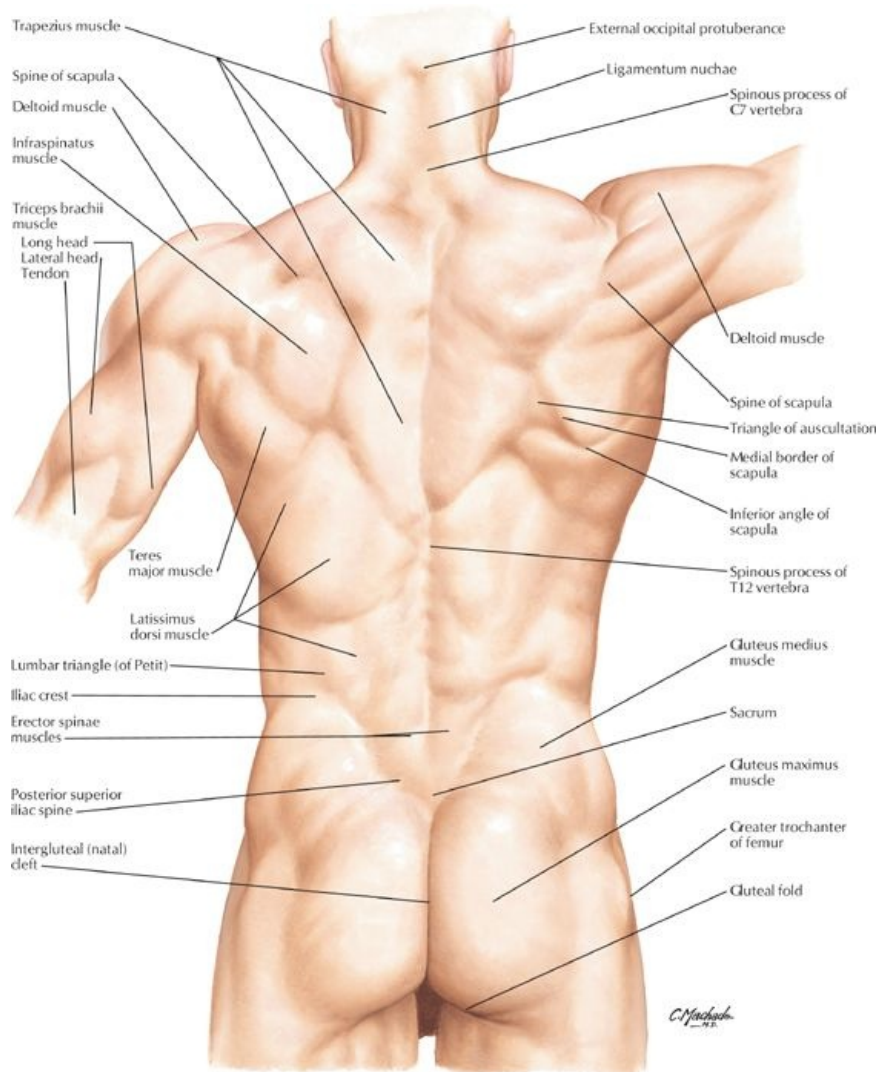
STUDY AIMS

At the end of your study, you should be able to:

- Identify posteromedian furrow
- Identify external occipital protuberance, vertebra prominens, iliac crests, posterior superior iliac spines
- Identify deltoid, latissimus dorsi, trapezius, erector spinae, teres major, infraspinatus, gluteus maximus, and medius
- Identify margins of scapula

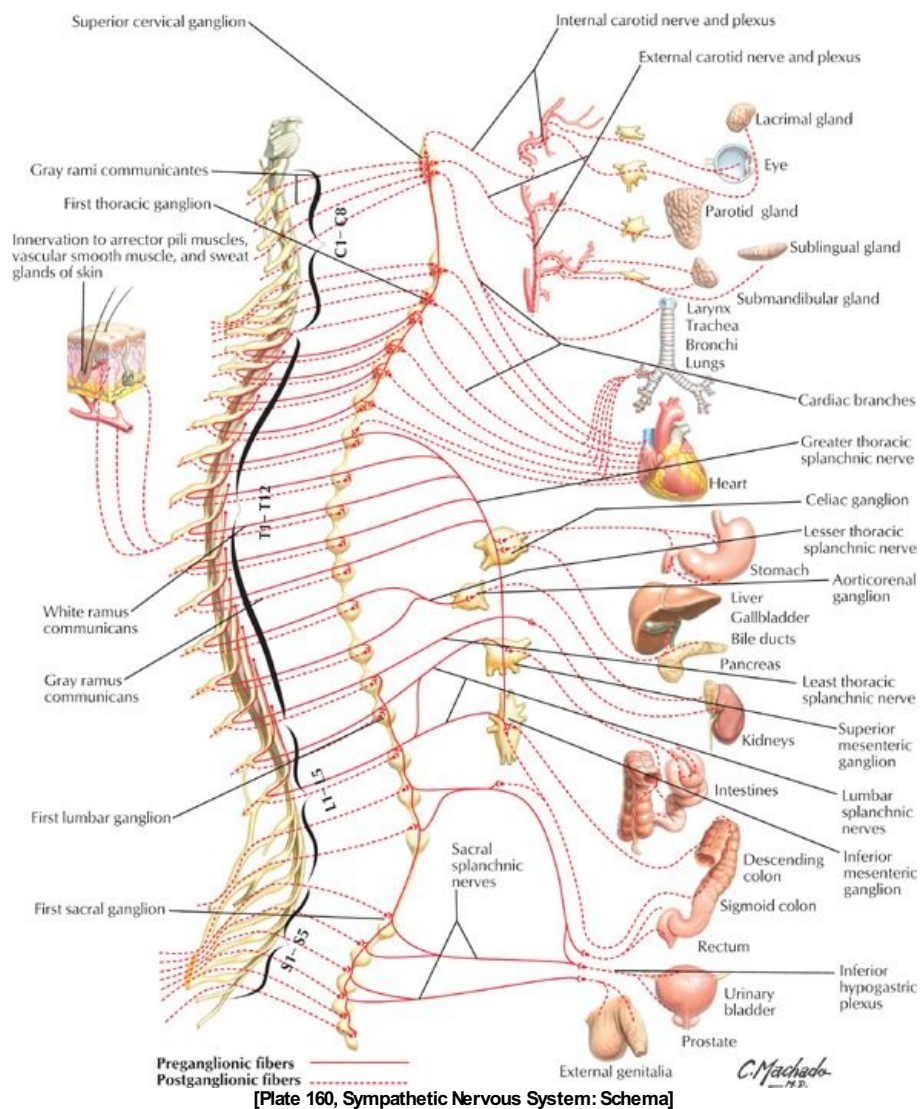
GUIDE

Back and Spinal Cord: Topographic Anatomy

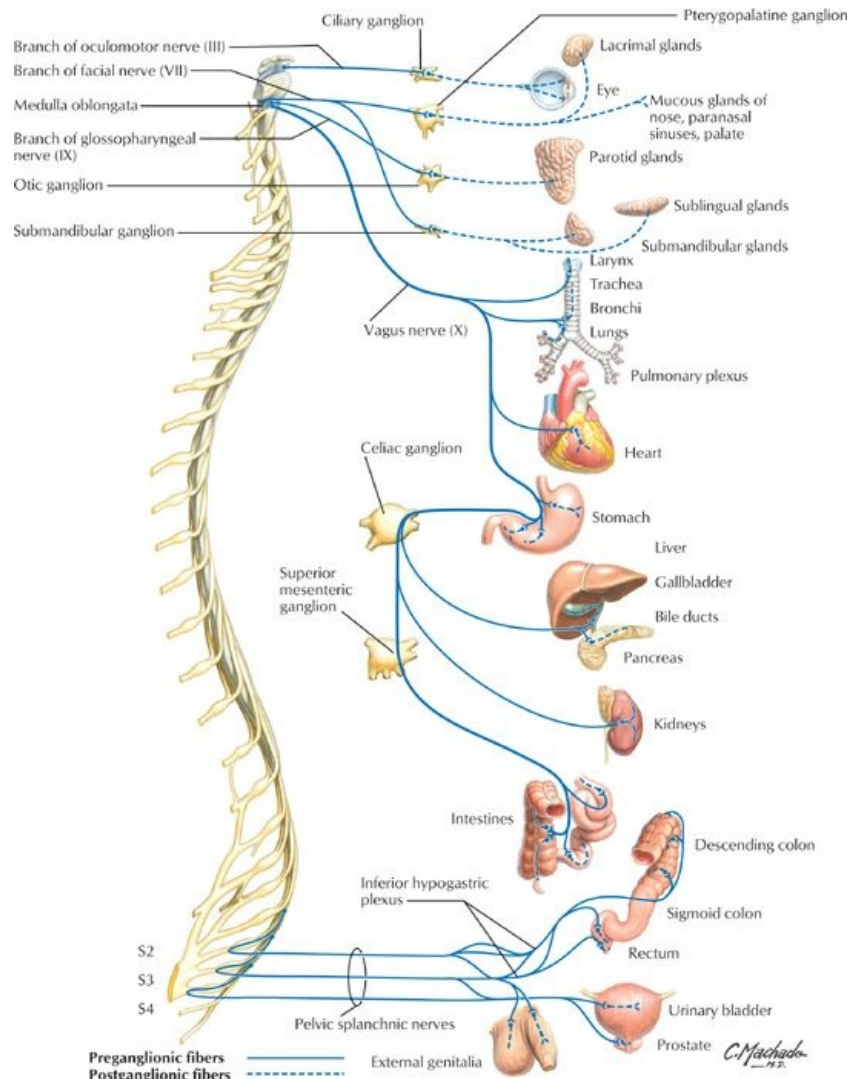


[Plate 149, Topographic Anatomy]

- Median line of back: posteromedian furrow overlies tips of spinous processes
 - Deepest in lower thoracic/upper lumbar region
 - Bordered by erector spinae
- Vertebra prominens = C7 spinous process (*T1 may be more prominent*)
- Scapula:
 - Superior angle at the level of T2
 - Medial end of scapular spine opposite spinous process of T3
 - Inferior angle at level of T7
 - Medial border of scapula parallels the sixth rib and approximates oblique fissure of lung when the arm is abducted by placing the hand on the head
- Iliac crests at level of L4 = supracristal line
- S2 spinous process lies level with a line joining the posterior superior iliac spines
- Tip of coccyx approximately 2.5 cm posterosuperior to the anus
- *Anatomy of muscles of the back are covered in Section 2-4: Back and Spinal Cord-Muscles and Nerves. (Muscles that are readily visible are trapezius, latissimus dorsi, and teres major).*



[Plate 160, Sympathetic Nervous System: Schema]



[Plate 161, Parasympathetic Nervous System: Schema]

Vertebrae and corresponding structures

Level	Corresponding Structure
C2-C3	Mandible
C3	Hyoid bone
C4-C5	Thyroid cartilage
C6	Cricoid cartilage
C7	Vertebra prominens
T3	Spine of scapula
T4/5	Sternal angle (of Louis)
T7	Inferior angle of scapula
T8	Inferior vena cava pierces diaphragm
T10	Xiphisternal junction
T10	Esophagus enters stomach
T12	Aorta passes behind diaphragm
L1/2	Spinal cord ends (<i>cauda equina starts</i>)
L3	Subcostal plane
L3-L4	Umbilicus
L4	Bifurcation of aorta
L4	Iliac crests-supracristal line
S2	End of dural sac
S2	Level of posterior superior iliac spines

FACTS & HINTS

High-Yield Facts

Clinical Points

Lumbar Puncture: Performed for retrieval of cerebrospinal fluid (CSF) from the lumbar spinal cistern. The patient is placed in the left decubitus position, flexed in the fetal posture with the supracristal line vertical. Puncture should be made at the L3/4 (immediately superior) or L4/5 (immediately inferior) interspace in the midline of the back, to avoid the spinal cord.

Mnemonics

Memory Aids

Lumbar puncture: ***To keep the cord alive, keep the needle between L3 and L5!***

15 Bones and Ligaments

STUDY AIMS

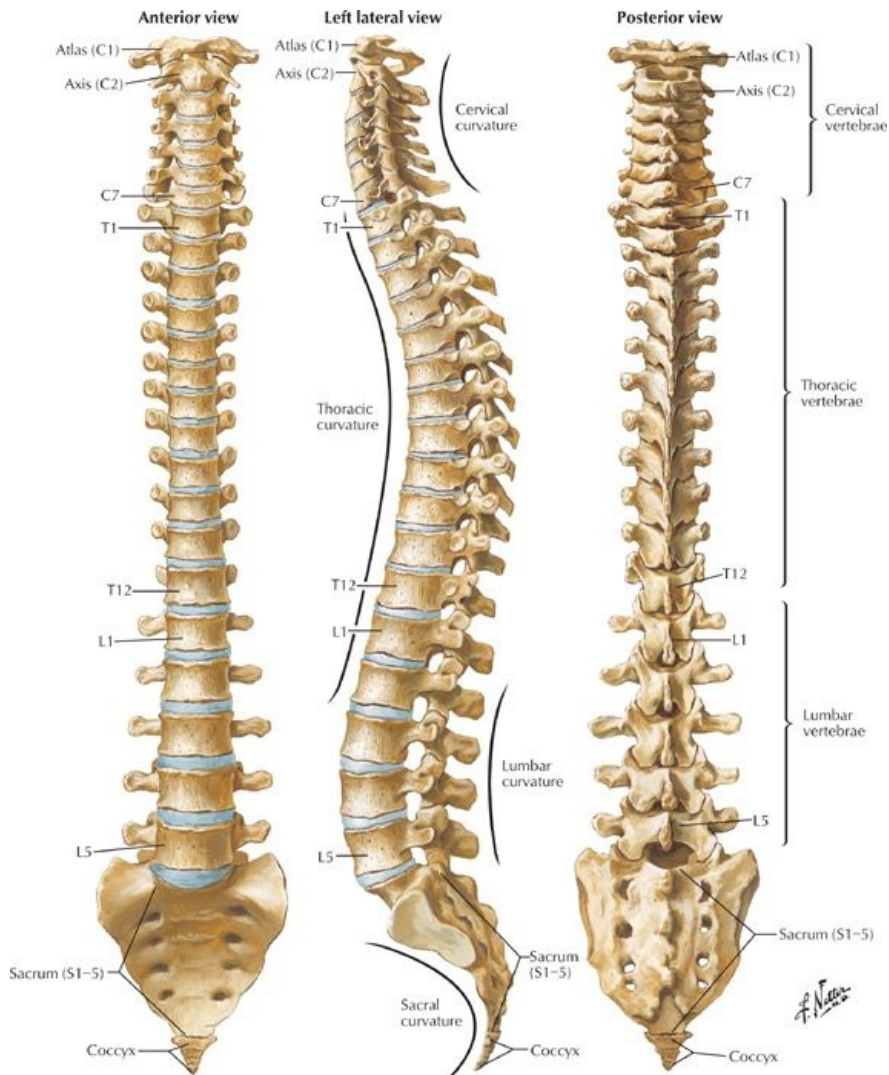
At the end of your study, you should be able to:

- Identify the significant parts of a typical vertebra and understand regional variations
- Identify the specialized vertebrae
- Know the attachments and function of the vertebral ligaments
- Describe the spine, its curvatures, and gross vertebral column movements
- Describe the type, location, and movements of the joints of the vertebral column

GUIDE

Back and Spinal Cord: Bones and Ligaments

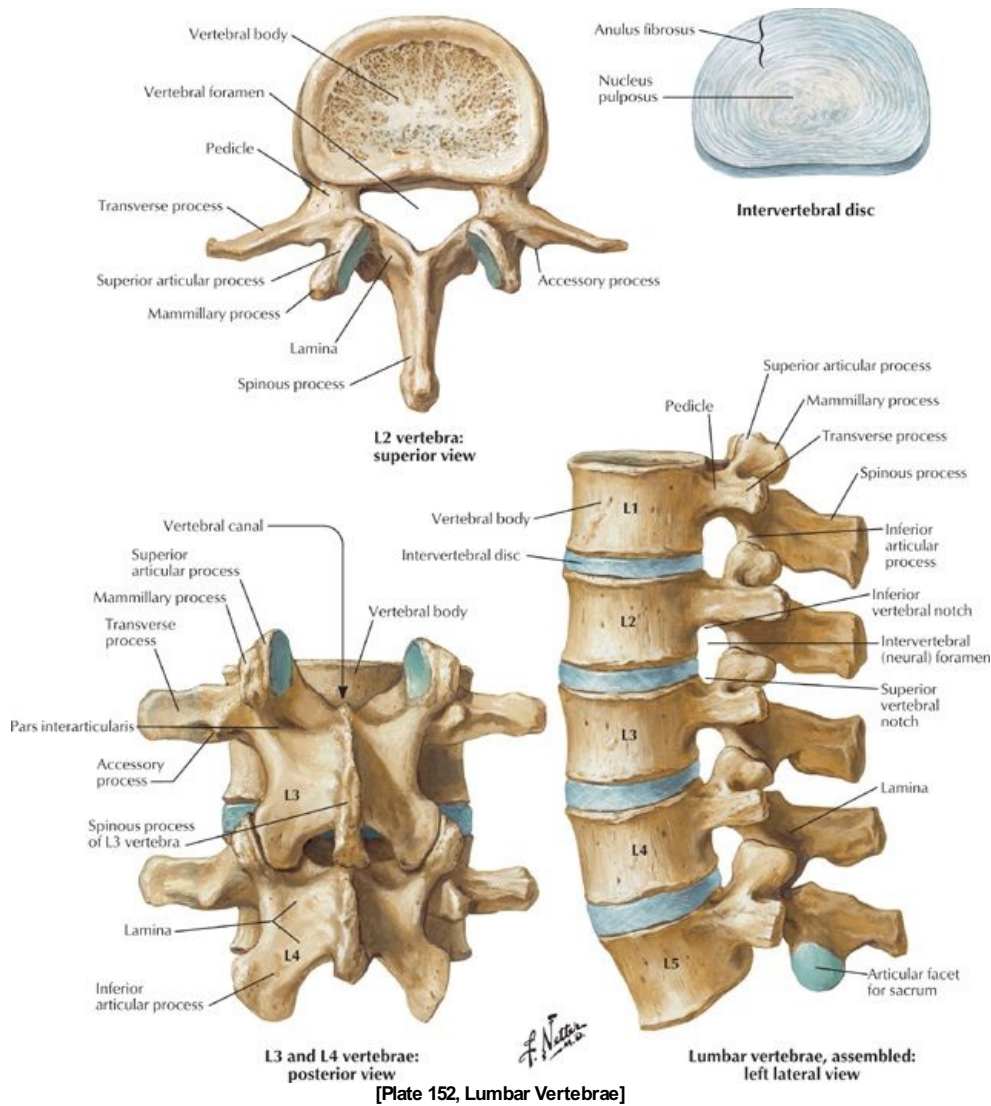
Vertebral Column



[Plate 150, Vertebral Column]

- approximately 72 to 75 cm long (25% of length because of intervertebral discs)
- 33 vertebrae (can vary 32-34)
 - 7 cervical, 12 thoracic, 5 lumbar, 5 sacral, 4 (3-5) coccygeal
 - Typically have: body, vertebral arch (2 laminae, 2 pedicles) and foramen; spinous (1) and transverse (2) processes; articular processes (4)
- Fibrocartilaginous intervertebral discs
 - Allow movement between vertebral bodies (in cervical, thoracic, and lumbar regions)
- Curvature (may be primary or secondary-see below)
 - Cervical anterior convexity (2°)
 - Thoracic anterior concavity (1°)
 - Lumbar anterior convexity (2°)
 - Sacral anterior concavity (1°)

Vertebrae



[Plate 152, Lumbar Vertebrae]

page 84
page 85

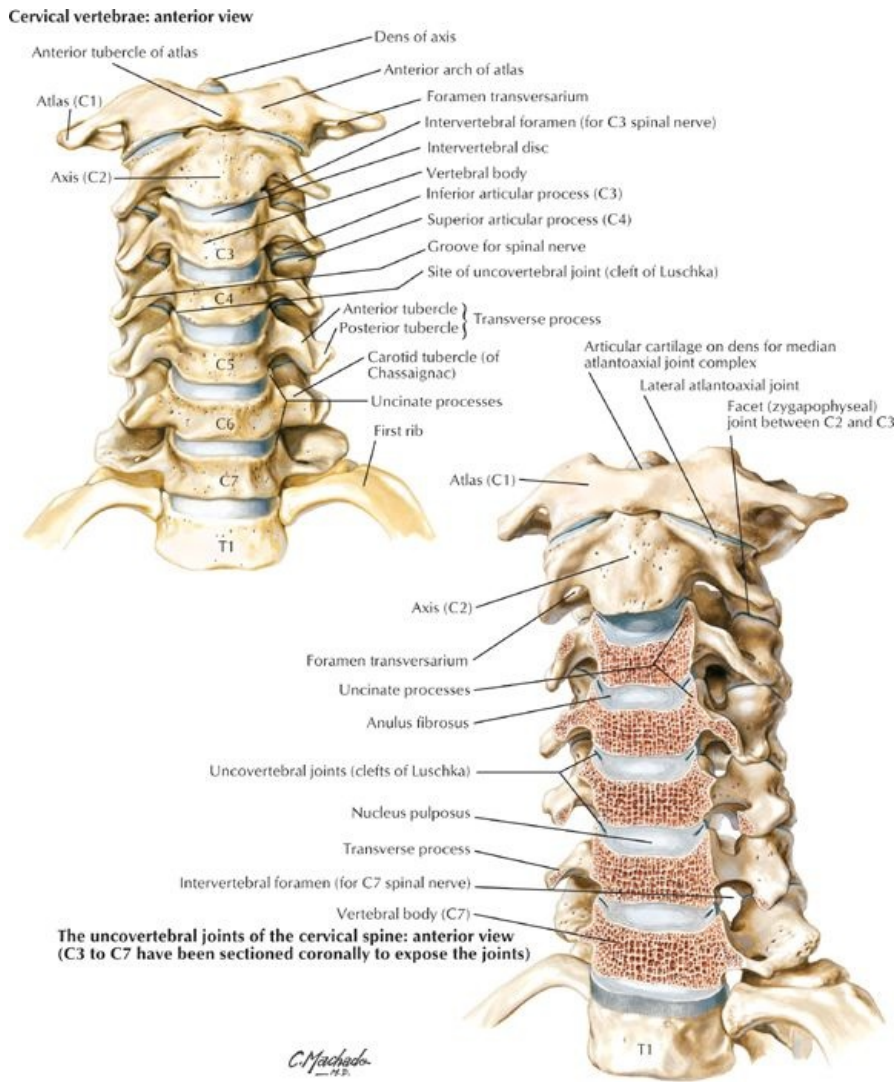
- Cervical vertebrae
 - Permit forward/lateral flexion, extension, rotation
 - C1 (Atlas): No body or spinous process; articulates with occipital condyles via paired lateral masses and with the axis via the superior articular facets and dens of the axis; groove on superior aspect of the posterior arch for vertebral arteries and dorsal ramus of C1
 - C2 (Axis): Dens (odontoid process), large superior articular facets for C1
 - C3-C5: Short bifid spinous processes (*anterior tubercle of C6 is the carotid tubercle, which the carotid artery can be compressed against to control bleeding*)
 - C6-7: long, nonbifid spinous processes
 - C7 (Vertebra prominens): long (*nonbifid*) spinous process; small transverse foramina that transmit accessory vertebral veins NOT vertebral artery
 - Have transverse processes with anterior and posterior tubercles and foramina (foramina transversaria), which transmit vertebral arteries and veins and sympathetic nerves plexuses
- Thoracic vertebrae
 - Are relatively rigid, mainly allow rotation of the trunk
 - T1-T4: Atypical-have some features of cervical vertebrae
 - T5-T8: Typical
 - T9-T12: Atypical-have tubercles similar to mammillary and accessory processes of lumbar vertebrae
 - Have long transverse processes that extend posterolaterally
- Lumbar vertebrae
 - Are relatively mobile, permit forward/lateral flexion and extension but little rotation
 - Have accessory process found on posterior surface of the base of each transverse process for attachment of medial intertransverse lumborum muscle
 - Have mammillary process for attachment of multifidus and medial intertransverse muscles
 - L5: massive body and transverse processes and is thicker anteriorly-contributes to the lumbosacral angle (usually 130°-160°) and carries the weight of the upper body
- Sacrum (sacral vertebrae)
 - Composed of five vertebrae that fuse at about 20 years of age, inferior portion is nonweightbearing
 - Articulates with "hip" bones at sacroiliac joints
 - Has concave pelvic surface

- Is wider in females than males
- Has a sacral canal (continuation of vertebral canal) that contains cauda equine
- Has the following features:
 - Sacral hiatus (termination of sacral canal) that contains filum terminale
 - Median crest: fused spinous processes
 - Paired medial crests: fused articular processes
 - Paired lateral crests: fused tips of the transverse processes
 - Sacral comeae that project inferiorly on either side of sacral hiatus
- Coccyx (coccygeal vertebrae)
 - Consist of three to five coccygeal vertebrae, inferior three fuse as coccyx in midlife
 - Has coccygeal comeae that articulate with sacral comeae
 - Provides site of attachment for gluteus maximus, coccygeus muscles, and anococcygeal ligament
 - Is joined to the sacrum by the sacrococcygeal symphysis

Summary of vertebral characteristics

Vertebrae	Distinctive Features
Cervical	Small bodies, large vertebral foramina, foramina in transverse processes, anterior and posterior tubercles, bifid spinous processes
Thoracic	Heart-shaped bodies, long spinous processes angled posteroinferiorly, costal facets for rib articulation on bodies and transverse processes
Lumbar	Large kidney-bean-shaped bodies, sturdy laminae, thick and short spinous processes, mammillary processes on the posterior surface of the superior articular facets (processes)
Sacral	Fused as sacrum, four pairs of dorsal and ventral foramina for nerve exit and triangular sacral canal
Coccygeal	Fused as small triangular bone—the coccyx

Joints

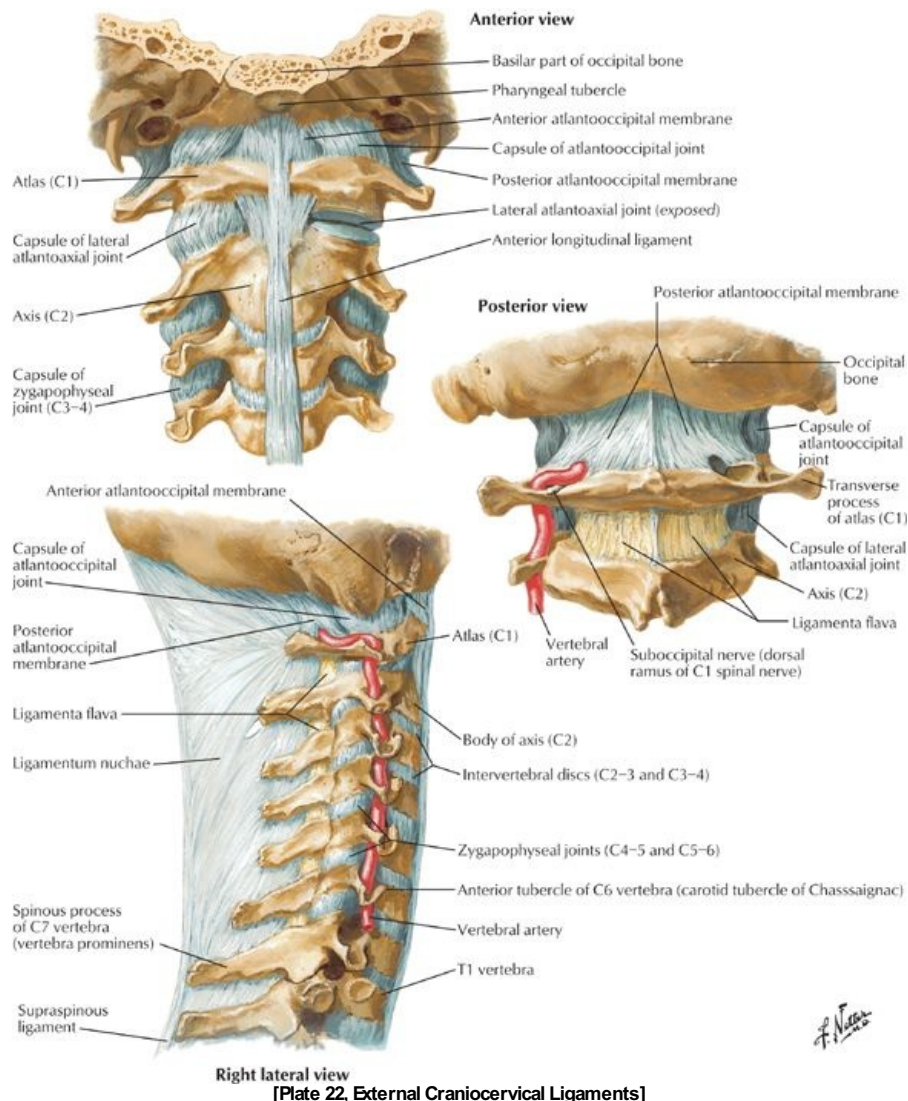


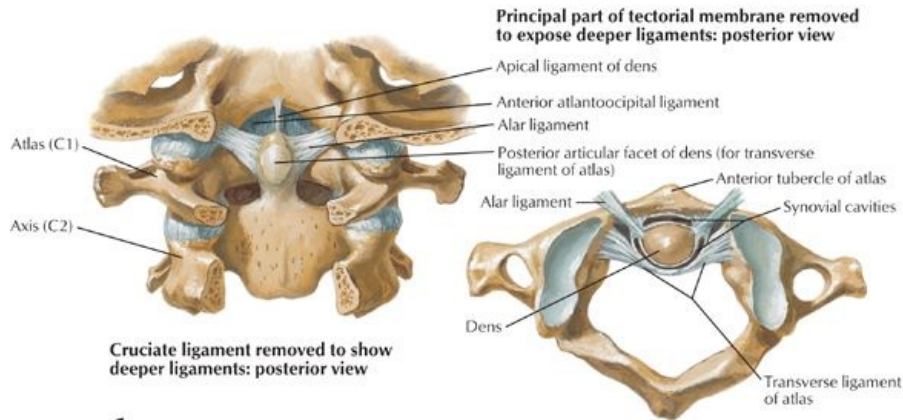
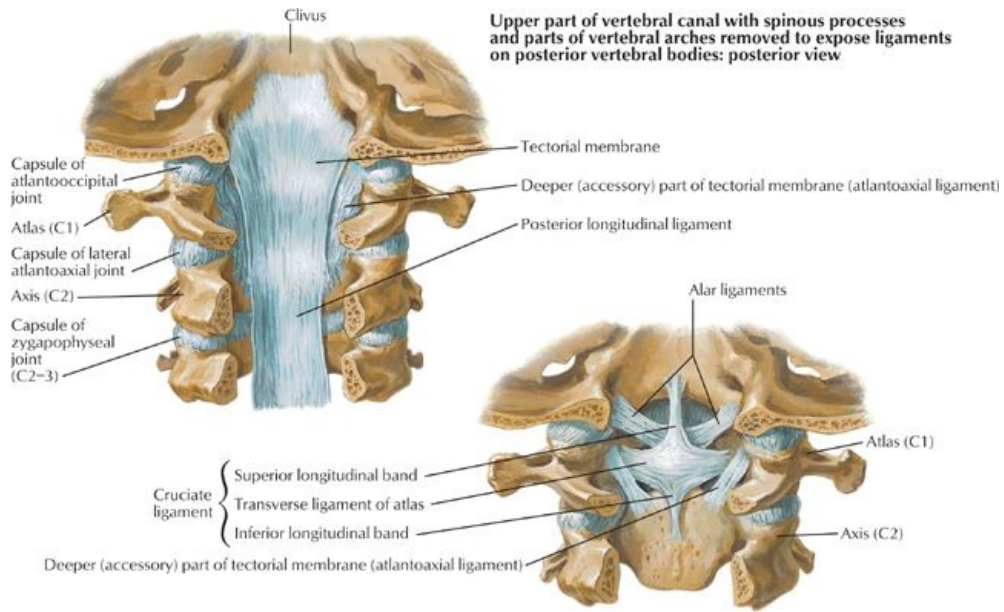
[Plate 21, Cervical Vertebrae: Uncoversbral Joints]

- Intervertebral (IV) discs
 - Connect articulating surfaces of adjacent vertebral bodies

- Are integral part of secondary cartilaginous joints between vertebral bodies (*except C1/2*)
- Are composed of a tough annulus fibrosus surrounding an avascular, gelatinous nucleus pulposus
- Act as "shock absorbers" and semifluid ball bearings to provide small movements between individual vertebrae
- Zygapophysial (or facet) joints
 - Are synovial joints between the superior and inferior articular processes
 - Are surrounded by thin, loose articular capsule
 - Permit gliding movements between vertebrae
- Atlanto-occipital joints
 - Are synovial joints between the lateral masses of atlas and occipital condyles
 - Permit flexion/extension and *some* lateral bending and rotation
- Atlantoaxial joints
 - Are three synovial joints between the inferior lateral masses of C1 and the superior facets of C2 and between the anterior arch of C1 and the dens of C2
 - Permit rotation of C1 (and the head), which is limited by the alar ligaments
- Costovertebral joints Synovial, between the vertebrae and ribs (*see: Thorax*)
- Sacroiliac (SI) joints. Synovial joints (*see: Pelvis and Perineum*)

Ligament	Features
Anterior longitudinal	Limits extension Maintains stability of IV discs
Posterior longitudinal	Limits flexion Prevents IV disc herniation
Intertransverse	Limits lateral bending
Interspinous	Limits flexion
Supraspinous	Limits flexion
Ligamenta flava	Limits flexion Preserves curvature of column Prevents injury to the IV discs
Ligamentum nuchae	Prevents cervical hyperflexion Attachment site for trapezius and rhomboid minor

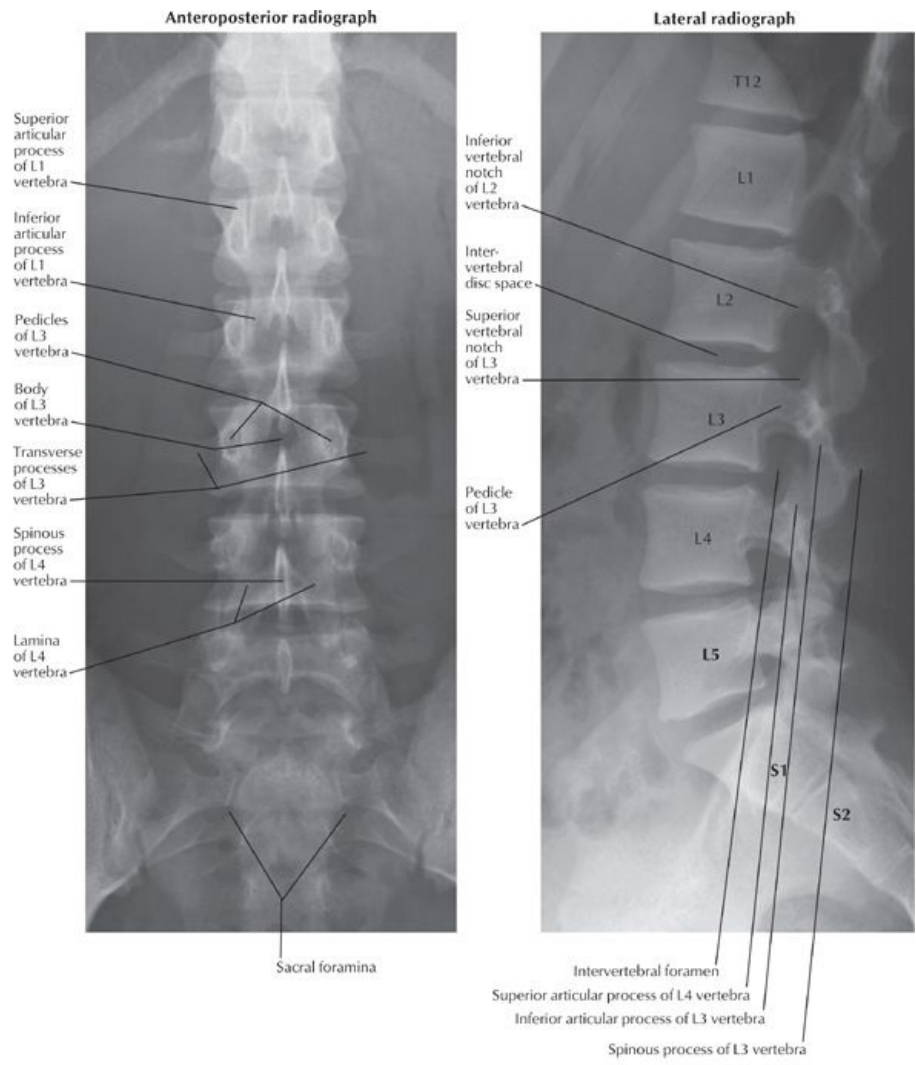




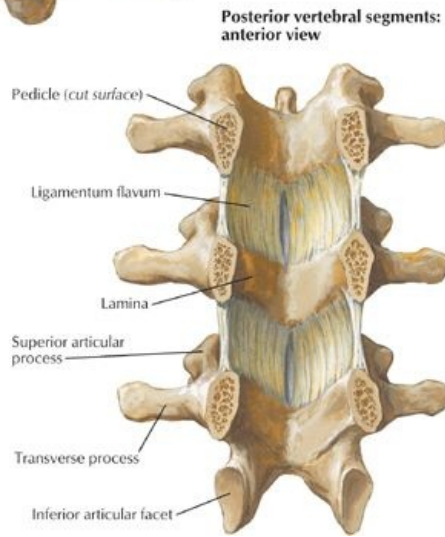
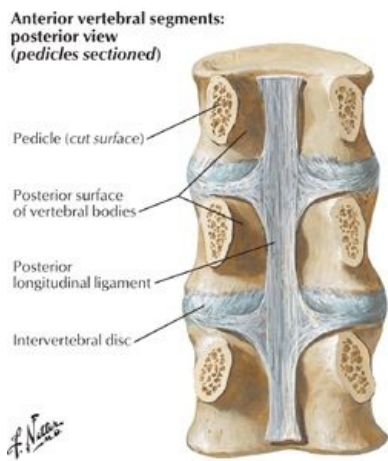
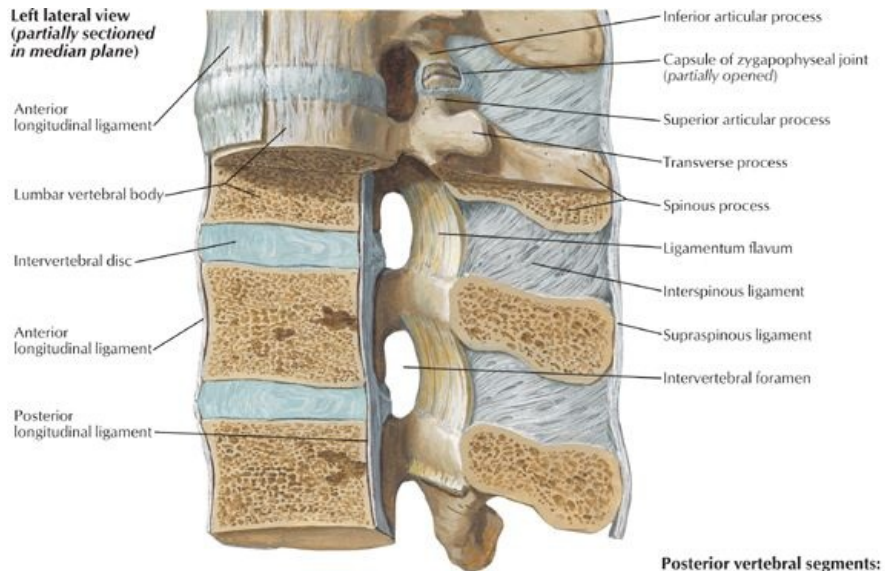
F. Netter

Median atlantoaxial joint: superior view

[Plate 23, Internal Craniocervical Ligaments]



[Plate 153, Lumbar Vertebrae: Radiographs] Note: The vertebral bodies are numbered



[Plate 156, Vertebral Ligaments: Lumbar Region]

FACTS & HINTS

High-Yield Facts

Clinical Points

page 86
page 87

Types of Vertebral Fractures

- Compression fractures
 - Vertebral body collapses
 - Caused by osteoporosis, trauma, or tumor
 - Usually occur at C7 and T1
 - Moderate to severe pain, limitation of movement, kyphosis
- Jefferson fracture
 - Four part fracture of the ring of C1
 - Caused by a fall on the vertex
 - Patients have upper neck pain but can be neurologically intact
- Hangman fracture
 - Caused by hyperextension of the head on the neck
 - Bipedicle fracture of C2
 - Anterior displacement of C2 and C3
 - Results in quadriplegia or death

Cervical Hyperextension

- Most common in young adults from trauma and sports injuries and the elderly, resulting in cord compression
- Result of whiplash from car accidents
- Results in soft tissue injury, fractures, dislocations, ligamentous tears, and disc disruption

Clinical Points

- **Spinal curvatures:** The primary curvatures of the vertebral column in the thoracic and sacral regions develop during the fetal period and are caused by differences in height between the anterior and posterior aspects of the vertebrae. The secondary curvatures are mainly a result of anterior-posterior differences in IV disc thickness. The cervical curvature is acquired when the infant begins to lift its head, and the lumbar curvature when the infant begins to walk.
- **Abnormal curvatures: Kyphosis** is an increased thoracic curvature, commonly seen in the elderly ("*Dowager hump*"). It is usually caused by osteoporosis, resulting in anterior vertebral erosion or a compression fracture. An excessive lumbar curvature is termed a **lordosis** and is seen in association with weak trunk muscles, pregnancy, and obesity. **Scoliosis** is an abnormal lateral curvature of the spine, accompanied by rotation of the vertebrae.
- **Spondylolisthesis:** The lumbosacral angle is created between the long axes of the lumbar vertebrae and the sacrum. It is primarily because of the anterior thickness of the L5 body. As the line of body weight passes *anterior* to the SI joints, anterior displacement of L5 over S1 may occur (spondylolisthesis), applying pressure to the spinal nerves of the cauda equina.
- **Sacralization:** In about 5% of individuals, the L5 vertebra is partially or totally fused with the sacrum. Because the L5/S1 level is now very strong, the L4/5 level is likely to degenerate in these cases.

page 87
page 88

Mnemonics

Memory Aids

Vertebral bodies:

- **Thoracic** are **heart-shaped** since your **heart** is in your thorax
- **Lumbar** are **kidney-bean** shaped as the **kidneys** are in the lumbar area

Craniovertebral joints:

- Atlantooccipital joint is the **yes-yes joint** because it permits nodding
- Atlantoaxial joint is the **no-no joint** because it permits turning the head from side to side

16 Spinal Cord

STUDY AIMS

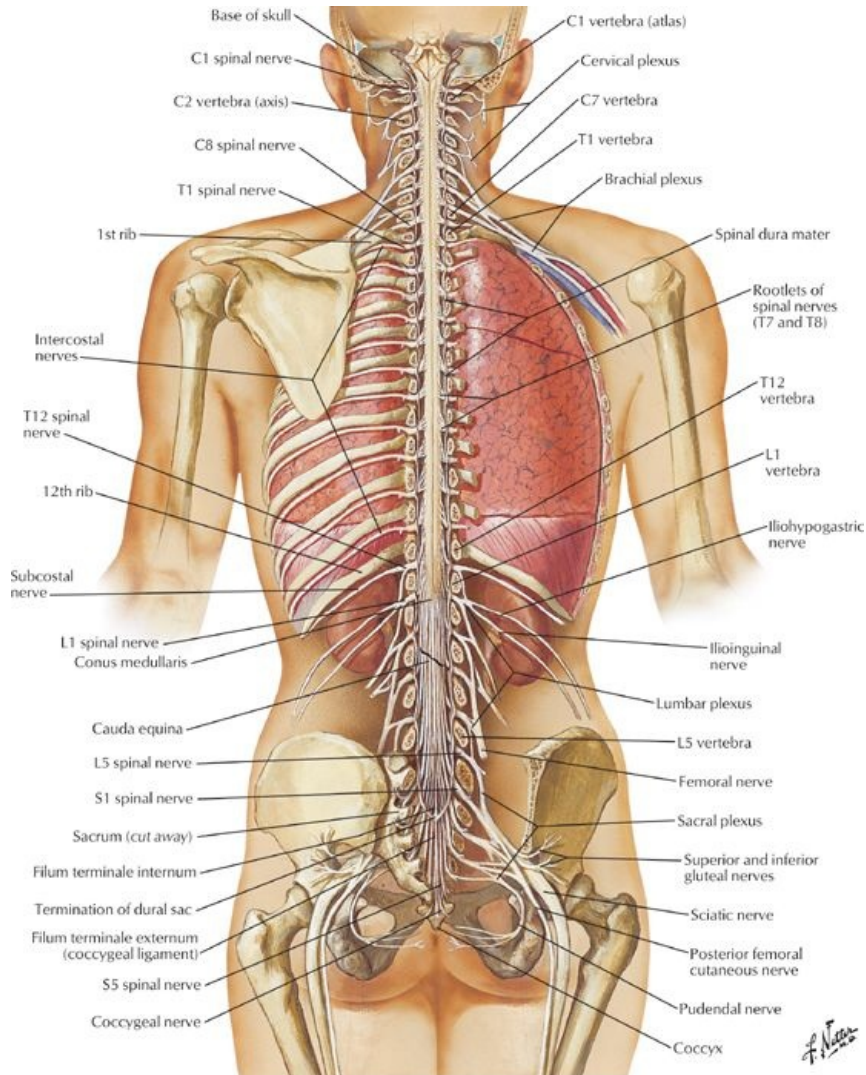
At the end of your study, you should be able to:

- Draw a schematic transverse section through the spinal cord, meninges, and vertebrae
- Understand the structure and function of the dorsal and ventral spinal nerve roots and rami
- Understand the general topography and synaptic transmitters of the autonomic nervous system
- Know the levels of the principle dermatomes
- Describe the vasculature supply of the spinal cord and vertebral column

GUIDE

Back and Spinal Cord: Spinal Cord

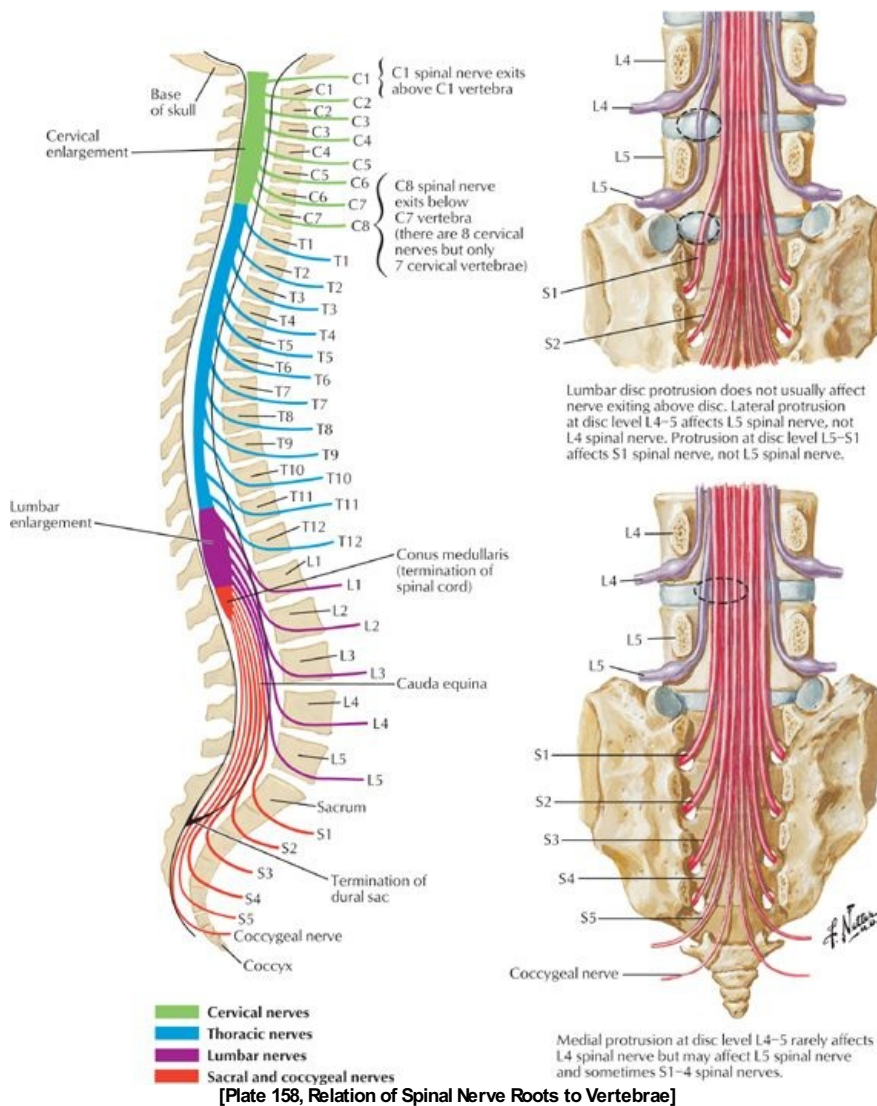
Spinal Cord



[Plate 157, Spinal Cord and Ventral Rami In Situ]

- Originates at the inferior end of the medulla oblongata and terminates as conus medullaris
- Is approximately 42 to 45 cm long from the foramen magnum to L2 (*variable from T12-L3*)
- Is connected from the conus medullaris to the coccyx by the filum terminale (a strand of connective tissue that connects exits from the dural sac and passes through the sacral hiatus)
- Has two regional enlargements
 - Cervical-origin of the brachial plexus innervating the upper limb
 - Lumbosacral-origin of the lumbar and sacral plexuses innervating the lower limb
- Has the following features in cross section
 - Dorsal median sulcus and ventral median fissure that divide cord into symmetrical halves
 - Central canal carrying cerebrospinal fluid (CSF)
 - White matter surrounding an H-shaped core of grey matter (ventral and dorsal horns)

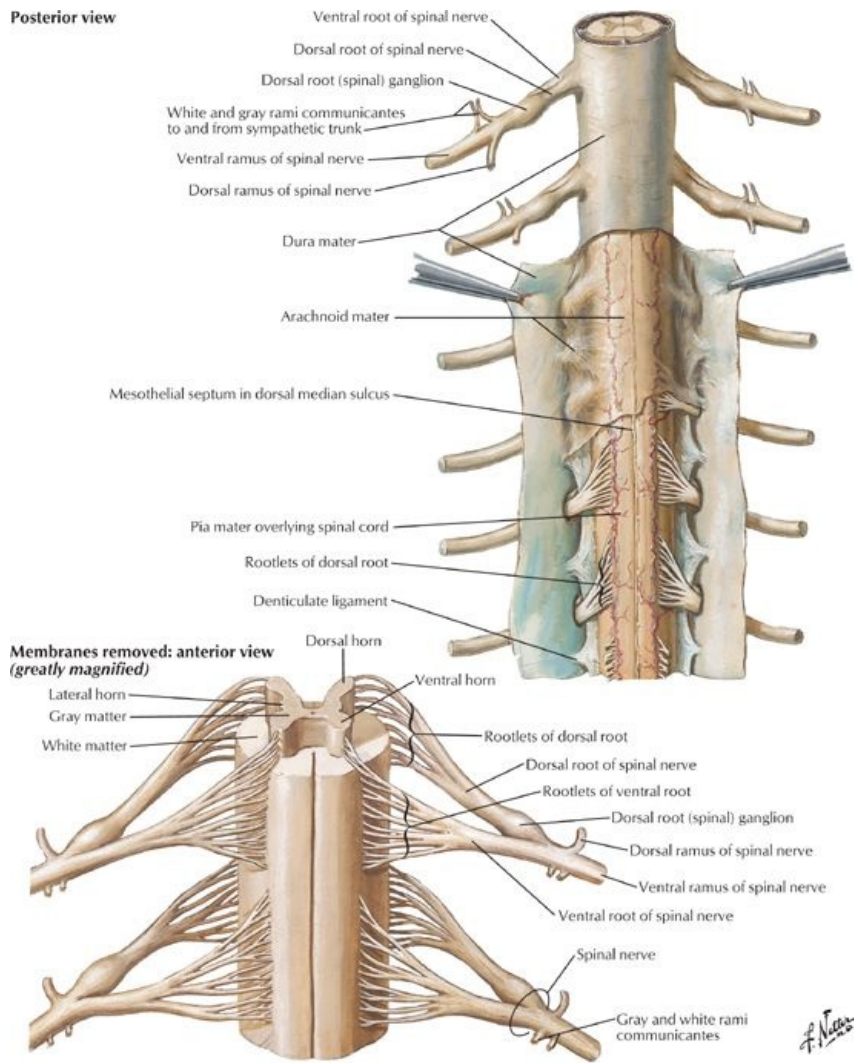
Structure of Spinal Nerves



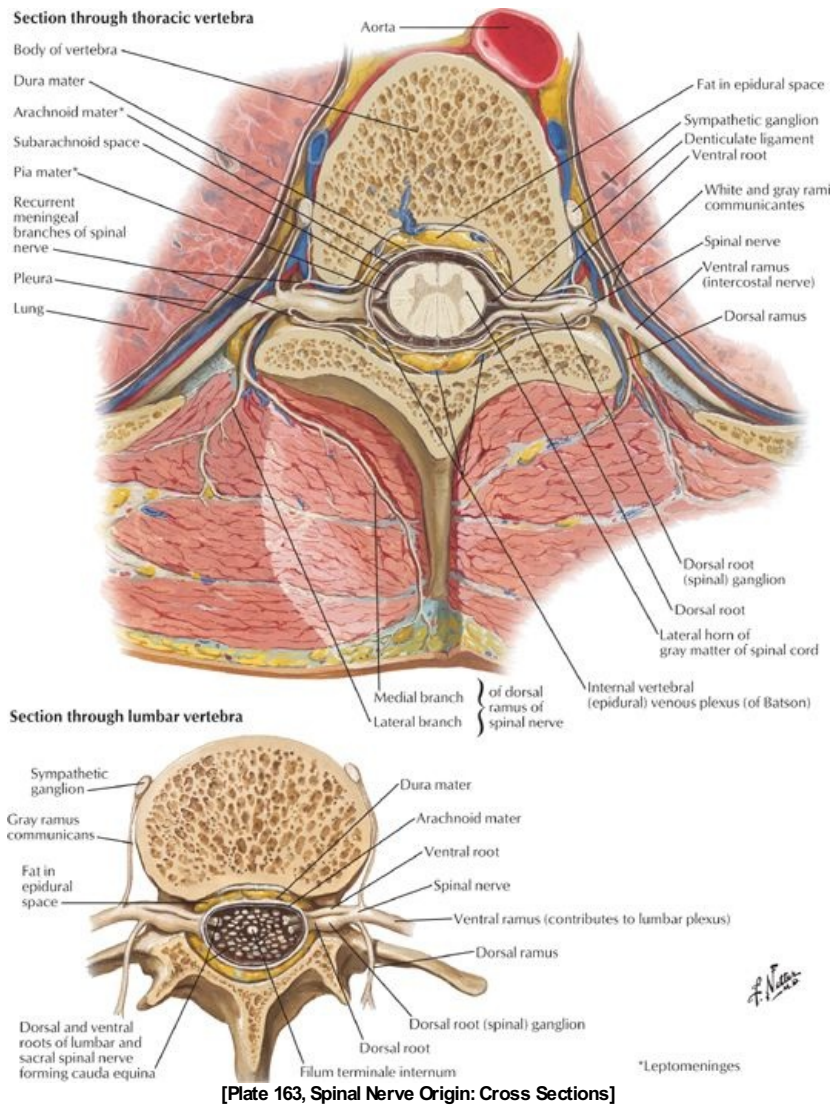
page 89
page 90

- 31 pairs of spinal nerves
 - 8 cervical, 12 thoracic, 5 lumbar, 5 sacral, 1 coccygeal
 - C1-C7 exit superior to corresponding vertebrae
 - C8 exits inferior to the C7 vertebra
 - T1-Co exit inferior to corresponding vertebrae
- Cauda equina: spinal nerve roots inferior to the conus medullaris, travelling obliquely to exit vertebral canal
- Ventral roots
 - Carry efferent (motor) fibers with their cell bodies in the ventral horn of the cord
 - May contain presynaptic autonomic fibers
- Dorsal roots
 - Carry afferent (general and visceral sensory) fibers with their cell bodies in the dorsal root ganglion (DRG)
 - May be absent in C1 and Co
- Ventral and dorsal roots: combine to form a (mixed) spinal nerve which exits through the intervertebral foramen and divides almost immediately into (mixed) ventral and dorsal rami
- Ventral rami
 - Anterior and lateral branches
 - Form plexuses and supply the limbs and trunk
- Dorsal rami
 - Medial and lateral branches
 - Supply the skin and true muscles of the back

Posterior view



[Plate 162, Spinal Membranes and Nerve Roots]



[Plate 163, Spinal Nerve Origin: Cross Sections]

Meninges

- **Dura mater:** Tough fibroelastic membrane
 - Is continuous with the inner (meningeal) layer of the cranial dura
 - Attached to the margins of the foramen magnum and posterior longitudinal ligament
 - Separated by the epidural space from vertebral periosteum
 - Extends as a sac from the margin of the foramen magnum to the level of S2
 - Pierced by spinal nerves
 - Anchored to the coccyx by the external filum terminale
 - Forms dural root sleeves covering the spinal nerves before fusing with the epineurium
- **Arachnoid mater:** Delicate, avascular, fibroelastic membrane lining dural sac
 - Opposed (*held to inner surface*) to dura by CSF pressure
 - Is external to the subarachnoid space, between arachnoid and pia, containing CSF, traversed by strands of connective tissue (arachnoid trabeculae)
 - Contains the lumbar cistern, an enlargement of subarachnoid space between L2 (*end of spinal cord*) and S2 (*end of dural sac*)
- **Pia mater:** Highly vascular innermost layer covering roots of spinal nerves
 - Continues as the filum terminale
 - Suspends the spinal cord within the dural sac by lateral extensions between the anterior and posterior roots, called denticulate ligaments

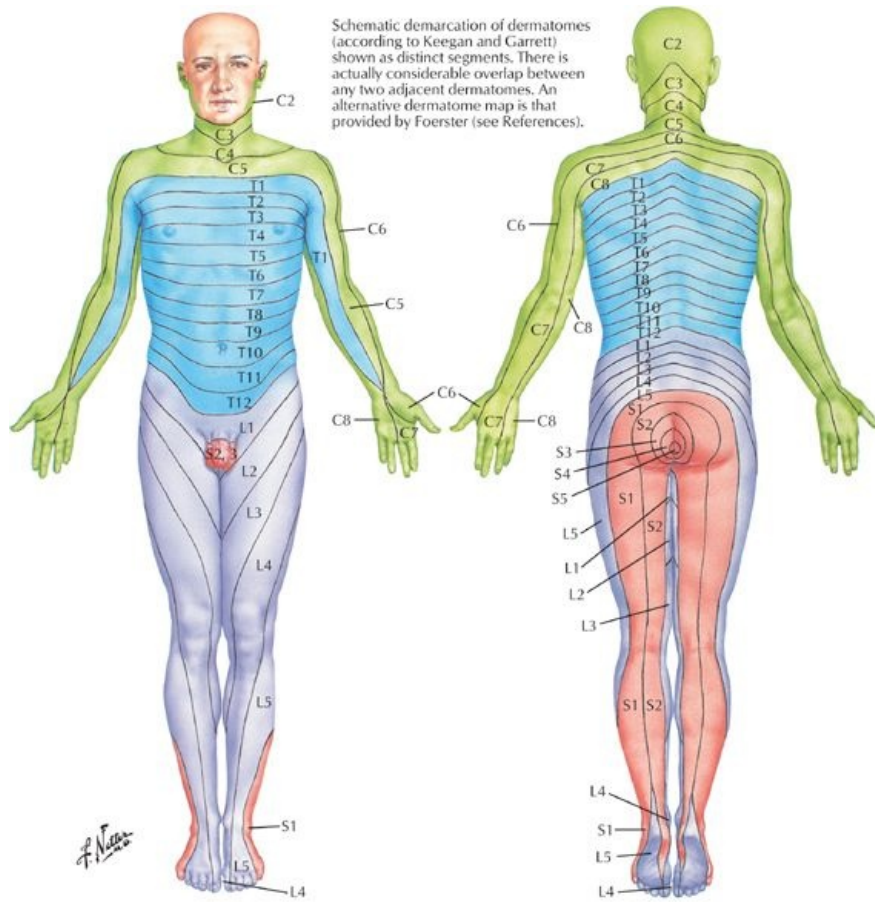
Dermatomes: a well-defined strip of skin extending from the anterior to the posterior midline, supplied by a single spinal nerve

- Cervical supply neck and upper limb
- Thoracic supply trunk (*T1 also supplies upper limb*)
- C5 abuts T1 on the superior anterior chest wall
- Lumbar predominantly supply anterior lower limb
- Sacral predominantly supply posterior lower limb

Level	Somatic Supply
C5	Clavicles
T4	Nipples

T10	Level of umbilicus
L1	Inguinal ligament
L3/4	Over the knee
S2-S4	Perineum

Dermatome levels to know:



Levels of principal dermatomes

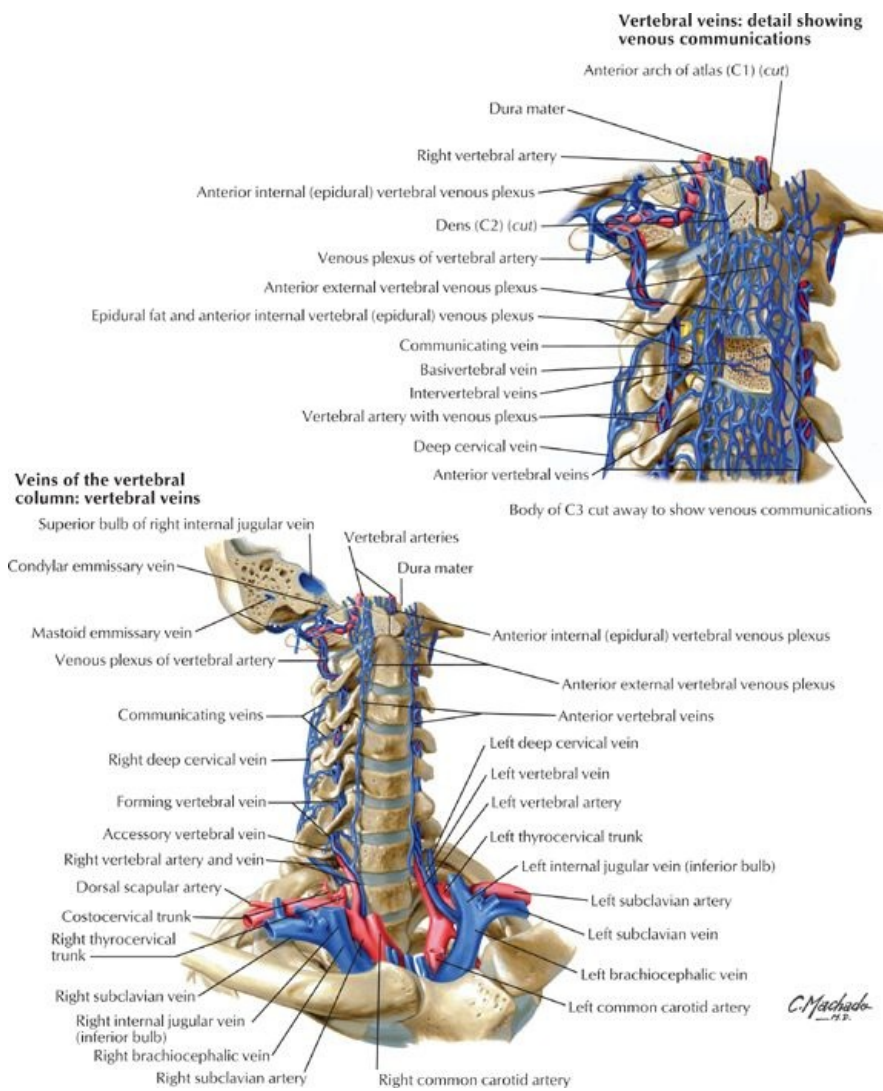
- C5 Clavicles
- C5, 6 Lateral sides of upper limbs
- C8, T1 Medial sides of upper limbs
- C6 Thumb
- C6, 7, 8 Hand
- C8 Ring and little fingers
- T4 Level of nipples

- T10 Level of umbilicus
- L1 Inguinal or groin regions
- L1, 2, 3, 4 Anterior and inner surfaces of lower limbs
- L4, 5, S1 Foot
- L4 Medial side of great toe
- L5, S1, 2 Lateral and posterior surfaces of lower limbs
- S1 Lateral margin of foot and little toe
- S2, 3, 4 Perineum

[Plate 159, Dermatomes]

page 90
page 91

Vasculature of Spinal Cord and Vertebral Column



[Plate 167, Veins of the Vertebral Column: Vertebral Veins]

- Anterior spinal artery
 - Is a single artery running in ventromedian fissure
 - Arising from branches of the vertebral arteries (*with contributions from the ascending cervical, deep cervical, intercostal, lumbar, and sacral arteries*)
 - Supplies the anterior two thirds of the spinal cord and vertebral bodies
- Posterior spinal arteries
 - Are paired, longitudinal arteries arising from vertebral or posterior inferior cerebellar arteries
 - Supply posterior one third of the spinal cord and vertebral bodies
- Radicular arteries
 - Are dorsal and ventral arteries arising from ascending cervical, deep cervical, intercostal, lumbar, and sacral arteries
 - Supply the nerve roots (*called segmental arteries if they reach the anterior or posterior spinal arteries*)
- Great anterior segmental artery (of Adamkiewicz)
 - Occurs on the left side in 65% of individuals
 - Contributes to two thirds of the circulation to the inferior spinal cord
- Veins: Usually 3 anterior and 3 posterior longitudinal spinal veins with tributaries from the posterior medullary and radicular veins. They drain into the valveless vertebral venous plexus.
- Vertebral venous plexus is continuous with the cranial dural venous sinuses and contains no valves
 - Internal vertebral plexus (lying in the extradural space) drains the spinal cord
 - External vertebral plexus connects with azygos vein, superior and inferior vena cavae

Autonomic Nervous System (ANS)

- Sympathetic NS: catabolic system for fight or flight
 - T1-L2/3 (thoracolumbar) levels
 - Presynaptic (preganglionic) neurons have cell bodies located in the intermediolateral cell columns of the spinal cord (*T1-L2 only*) and utilize acetylcholine (ACh) as their neurotransmitter and synapse in para- or prevertebral ganglia
 - Postsynaptic (postganglionic) neurons have cell bodies in the paravertebral and prevertebral ganglia
 - Paravertebral ganglia linked to form right and left sympathetic chains (*superior, middle and inferior cervical ganglia, T1-S5, ganglion impar*)
 - Paravertebral ganglia attached to spinal nerves by white (T1-L2) and grey (C1-Co) rami communicantes

page 91
page 92

-
- Long postsynaptic neurons utilize norepinephrine as their neurotransmitter
 - Prevertebral ganglia (*celiac, superior, and inferior mesenteric, aorticorenal*) are in plexuses surrounding the origins of the main branches of the abdominal aorta
 - Splanchnic nerves are presynaptic fibers that pass through the paravertebral ganglia without synapsing to enter cardiac, pulmonary, esophageal, various abdominal and pelvic plexuses, where they synapse
 - Sympathetic fibers innervate smooth muscle, modified cardiac muscle, glands, and medulla of suprarenal glands
 - Parasympathetic NS: anabolic system for homeostasis
 - S2-S4 levels and cranial nerves III, VII, IX, X (craniosacral)
 - Long presynaptic neurons (ACh) with cell bodies in the mediolateral grey matter (S2-S4)
 - Short postsynaptic neurons arising near target organs (ACh)
 - Innervation of smooth muscle, modified cardiac muscle, and glands of thoracic, abdominal, and pelvic viscera
 - Visceral afferent NS: provides sensory input from the body's internal environment
 - Provides visceral sensation
 - Can trigger both somatic and visceral reflexes

FACTS & HINTS

High-Yield Facts

Clinical Points

Disc Herniation

Protrusion of the nucleus pulposus through the annulus fibrosus:

- Ninety-five percent at the L4/5 or L5/S1 level
- Usually posterolateral herniation where annulus is thinnest
- Herniation into the vertebral canal may compress the nerve root below the disc and cause pain in the related dermatome
- Age-related dehydration of nucleus pulposus contributes to loss of height and narrowing of IV foramina

Lumbar Spinal Stenosis

- Narrowing of the vertebral canal
- Compression of spinal cord caused by age-related degenerative changes such as bulging of the IV discs or arthritis
- Surgical laminectomy or removal of the entire vertebral arch may be necessary to alleviate symptoms

Clinical Points

- **Spinal cord development:** In the fetus, the spinal cord extends down to the sacral vertebrae. As a fetus matures, the cord shortens relative to the rest of the body, so at birth the conus medullaris reaches the L2/3 level, and by adulthood only around the level of the L1/2 IV disc, where the cauda equina begins
- **Epidural block:** Anaesthetic injected into epidural space of the sacral canal either via the sacral hiatus (*caudal epidural*) using the sacral cornua as landmarks, or via the posterior sacral foramina (*transsacral epidural*). The anesthetic solution spreads superiorly to act on spinal nerves S2-Co. The height to which the anesthetic ascends is affected by the amount of solution injected and the position of the patient.
- **Spinal block:** Introduction of an anesthetic directly into the CSF (in the subarachnoid space) utilizing a lumbar puncture (*see above*). Onset of anesthesia is rapid <1 minute (*unlike epidural anesthesia that may take up to 20 minutes*). Subsequent leakage of CSF may cause a headache in some individuals.

Mnemonics

Memory Aids

Dermatomes:	<i>T-ten over your belly but-ten</i>
	<i>L3 over the knee</i>
	<i>Sit on Sacral dermatomes</i>

17 Muscles and Nerves

STUDY AIMS

At the end of your study, you should be able to:

- Describe the origins, insertions, major functions, and innervation of the superficial, intermediate, and deep muscles of the back
- Identify structures of the back as seen in transverse section
- Understand the anatomy of the suboccipital triangle
- Describe the typical organization of the thoracic spinal nerves

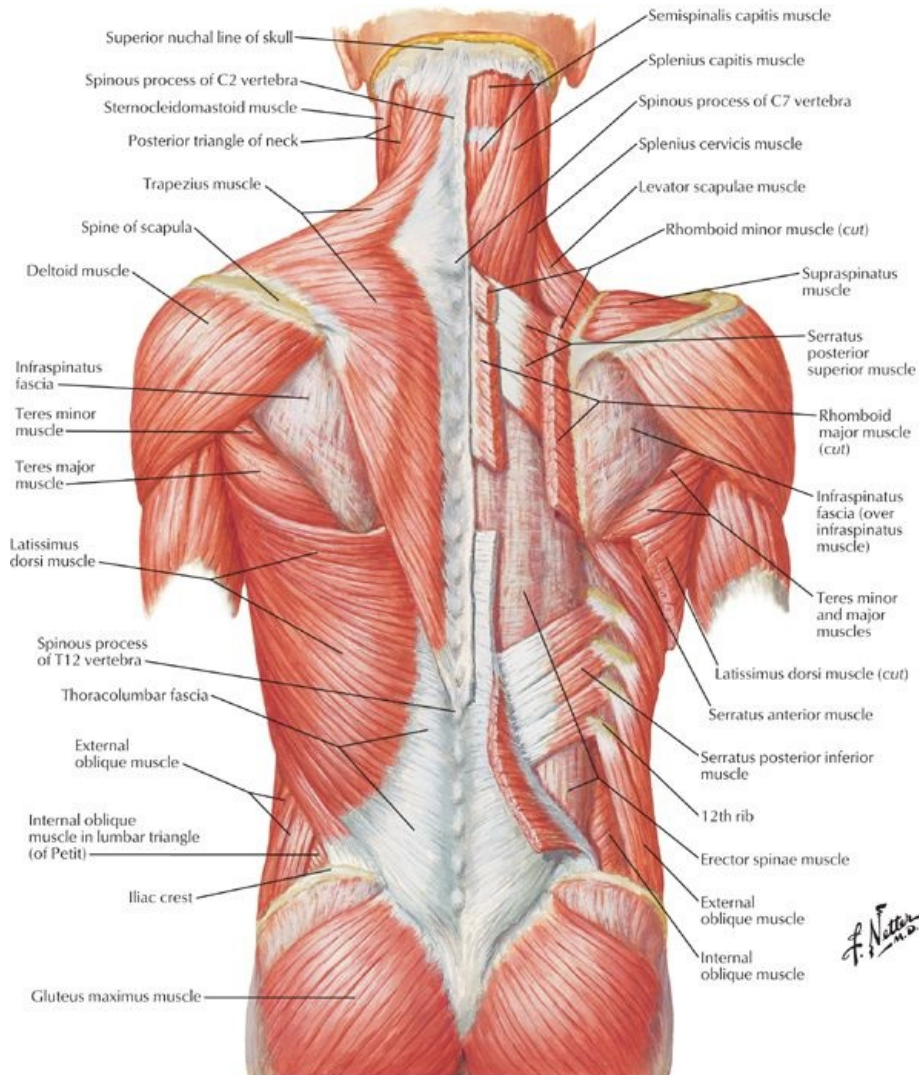
GUIDE

Back and Spinal Cord: Muscles and Nerves

The muscles of the back are divided into the extrinsic muscles that connect the upper limb to the trunk and the intrinsic (deep or true) muscles that specifically act on the vertebral column to produce movements and maintain posture.

Extrinsic muscles of the back

- Superficial: Trapezius, latissimus dorsi, levator scapulae, rhomboid minor and major
- Intermediate: Serratus posterior superior and posterior inferior (*muscles of respiration*)

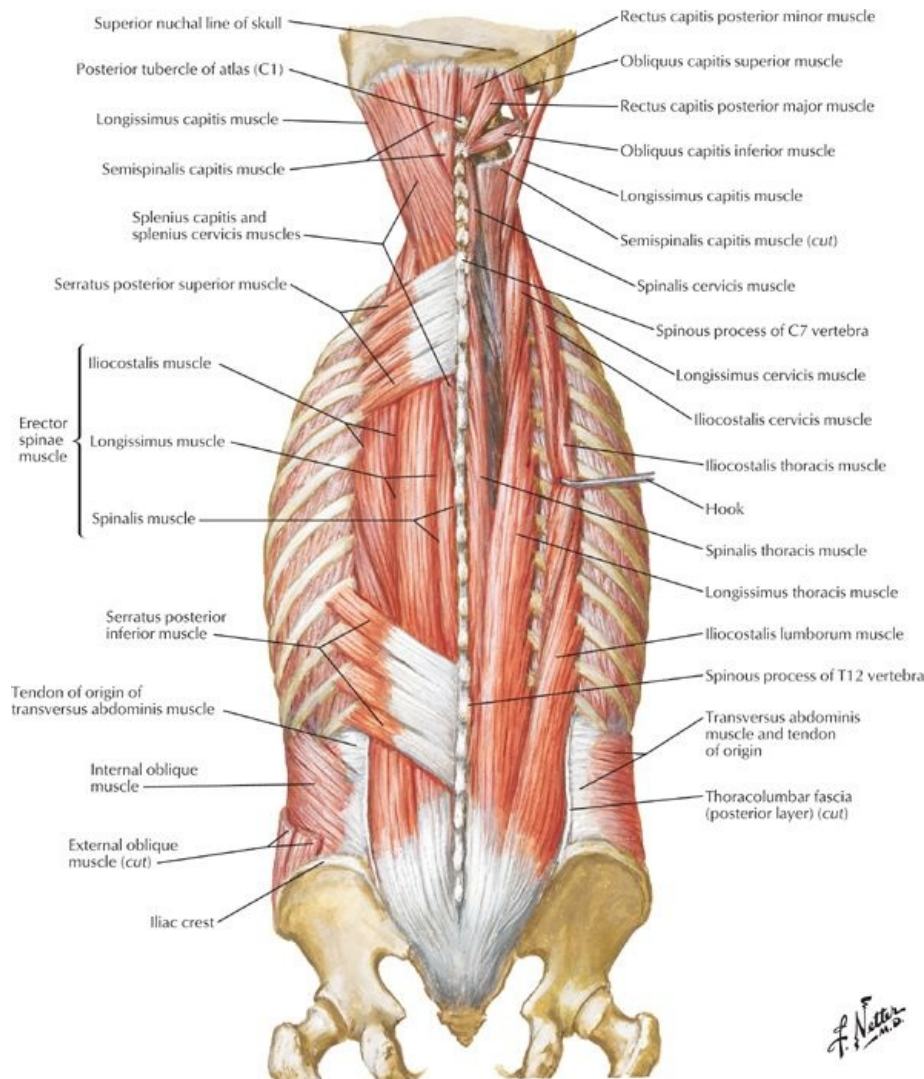


[Plate 168, Muscles of Back: Superficial Layers]

Muscle	Proximal Attachment (Origin)	Distal Attachment (Insertion)	Innervation	Main Actions
Trapezius	Superior nuchal line, external occipital protuberance, nuchal ligament, and spinous processes of C7-T12	Lateral third of clavicle, acromion, and spine of scapula	Accessory nerve (cranial nerve XI) and C3-C4 (proprioception)	Elevates, retracts, and rotates scapula; lower fibers depress scapula
Latissimus dorsi	Spinous processes of T7-T12, thoracolumbar fascia, iliac crest, and last 3-4 ribs	Humerus (intertubercular sulcus)	Thoracodorsal nerve (C6-C8)	Extends, adducts, and medially rotates humerus
Levator scapulae	Transverse processes of C1-C4	Medial border of scapula	C3-C4 and dorsal scapular (C5) nerve	Elevates scapula and tilts glenoid cavity inferiorly
Rhomboid minor and major	<i>Minor</i> : nuchal ligament and spinous processes of C7-T1 <i>Major</i> : spinous processes of T2-T5	Medial border of scapula	Dorsal scapular nerve (C4-C5)	Retract scapula, rotate it to depress glenoid cavity, and fix scapula to thoracic wall
Serratus posterior superior	Ligamentum nuchae, spinous processes of C7-T3	Superior aspect of ribs 2-4	T1-T4	Elevate ribs

Serratus posterior inferior	Spinous processes of T11-L2	Inferior aspect of ribs 9-12	T9-T12	Depress ribs
-----------------------------	-----------------------------	------------------------------	--------	--------------

Intrinsic muscles of the back



[Plate 169, Muscles of Back: Intermediate Layers]

- Superficial: Splenius (capitis/cervicis)
- Intermediate: Erector spinae (sacrospinalis) group-iliocostalis (lumborum/thoracis/cervicis) longissimus (thoracis/cervicis/capitis), spinalis (thoracis/cervicis/capitis)
- Deep: Transversospinal group-semispinalis (thoracis/cervicis/capitis), multifidus, rotatores
- Minor deep: interspinales, intertransversarii, levatores costarum (brevis and longus)

Muscle	Proximal Attachment (Origin)	Distal Attachment (Insertion)	Innervation	Main actions
Superficial Layer				
Splenius capitis	Nuchal ligament, spinous process C7-T3	Mastoid process of temporal bone and lateral third of superior nuchal line	Middle cervical nerves	<i>Bilaterally:</i> extend head <i>Unilaterally:</i> laterally bend (flex) and rotate face to same side
Splenius cervicis	Spinous process T3-T6	Transverse process (C1-C3)	Lower cervical nerves	<i>Bilaterally:</i> extend neck <i>Unilaterally:</i> laterally bend (flex) and rotate neck toward same side
Intermediate Layer				
Erector spinae	Posterior sacrum, iliac crest, sacrospinous ligament, supraspinous ligament, and spinous processes of lower lumbar and sacral vertebrae	<i>Iliocostalis:</i> angles of lower ribs and cervical transverse processes <i>Longissimus:</i> between tubercles and angles of ribs, transverse processes of	Respective spinal nerves of each	Extend and laterally bend vertebral column and head

		thoracic and cervical vertebrae, and mastoid process <i>Spinalis</i> : spinous processes of upper thoracic and midcervical vertebrae	region	
Semispinalis	Transverse processes C4-T12	Spinous processes of cervical and thoracic regions	Respective spinal nerves of each region	Extend head, neck, and thorax and rotate them to opposite side
Multifidi	Sacrum, ilium, and transverse processes of T1-T12, and articular processes of C4-C7	Spinous processes of vertebrae above, spanning two to four segments	Respective spinal nerves of each region	Stabilizes spine
Rotatores	Transverse processes	Lamina and transverse process or spine above, spanning one or two segments	Respective spinal nerves of each region	Stabilize, extend, and rotate spine

Fascia

- Encloses deep muscles of the back
- Attached medially to the nuchal ligament, tips of the spinous processes, supraspinous ligament, and median line of sacrum
- Attached laterally to the cervical and lumbar transverse processes
- Thickened as the thoracolumbar fascia toward lumbar region and extends between the twelfth rib and the iliac crest

Vascular supply to muscles and skin of the back

- Arteries
 - Cervical: branches from occipital, ascending cervical, vertebral, and deep cervical
 - Thoracoabdominal: branches of posterior intercostals, subcostal, and lumbar
 - Pelvic: iliolumbar and lateral sacral branches of the internal iliac
- Veins drain via the valveless vertebral venous plexus
- Lymph
 - Neck: Drains to the anterior, lateral, and deep cervical nodes
 - Trunk: drains to axillary nodes above umbilicus and superior inguinal nodes below it

Suboccipital region

- Inferior to the occiput, deep to the trapezius and semispinalis capitis, overlying C1 and C2
- Muscles
 - Rectus capitis posterior minor and major
 - Obliquus capitis superior and inferior
 - *All laterally flex, extend, and rotate the head*
 - *All supplied by the suboccipital nerve (dorsal ramus of C1)*
- Contains the dorsal rami of C1-C4
- Suboccipital triangle
 - Contains the vertebral artery, suboccipital nerve and suboccipital venous plexus.
 - Bounded by rectus capitis posterior major, obliquus capitis superior and obliquus capitis inferior, floor-atlantooccipital membrane, roof-semispinalis capitis

Deep Layer Muscle	Proximal Attachment (Origin)	Distal Attachment (Insertion)	Innervation	Main Actions
Rectus capitis posterior major	Spine of axis	Lateral inferior nuchal line	Suboccipital nerve (C1)	Extends head and rotates to same side
Rectus capitis posterior minor	Tubercle of posterior arch of atlas	Median inferior nuchal line	Suboccipital nerve (C1)	Extends head
Obliquus capitis superior	Transverse process of atlas	Occipital bone	Suboccipital nerve (C1)	Extend head and bend it laterally
Obliquus capitis inferior	Spine of axis	Atlas transverse process	Suboccipital nerve (C1)	Rotates atlas to turn face to same side

Branches of spinal nerves

- Ventral rami innervate the muscles and overlying skin of the anterior thoracic, abdominal and pelvic wall and contribute to
 - Cervical plexus [C1-C4] (*see: Head and Neck*)
 - Brachial plexus [C5-T1] (*see: Upper Limb*)
 - Thoracic intercostal nerves (*see also: Thorax*)
 - Lumbar plexus [T12-L4] (*see: Pelvis and Perineum and Lower Limb*)
 - Sacral plexus [L4-S5] (*see: Lower Limb*)
- Dorsal rami
 - C1: Suboccipital nerve-pierces the atlantooccipital membrane and is motor to the suboccipital muscles
 - C2: Greater occipital nerve-passes inferior to OCI and is sensory to skin over neck and occipital bone

-
- C3-Co: Segmentally innervate the intrinsic muscles of the back and overlying skin

FACTS & HINTS

High-Yield Facts

Clinical Points

- **Back pain:** A very common, usually self-limiting complaint, often affecting the lumbar region ("low back pain"). Radiation to back of the thigh and into the leg (*sciatica*) or focal neurology suggests radiculopathy. Disturbance of bladder/bowel function should prompt urgent intervention.
- **Back strain:** Stretching and microscopic tearing of muscle fibres or ligaments, often because of a sport-related injury. The muscles subsequently go into spasm as a protective response causing pain and interfering with function. This is a common cause of low back pain.
- **Whiplash:** Cervical muscle and/or ligament strain because of forceful hyperextension of the neck. Frequently caused by impacts from the rear in motor vehicle accidents. May cause herniation of the IV disc and subsequent radiculopathy.

Mnemonics

Memory Aids

Deep back muscles:	I Love Spaghetti-Some More Ragu
	= Iliocostalis, Longissimus, Spinalis-Semispinalis, Multifidus, Rotatores
Erector spinae group:	I Like Standing
	= Iliocostalis, Longissimus, Spinalis

18 Topographic Anatomy

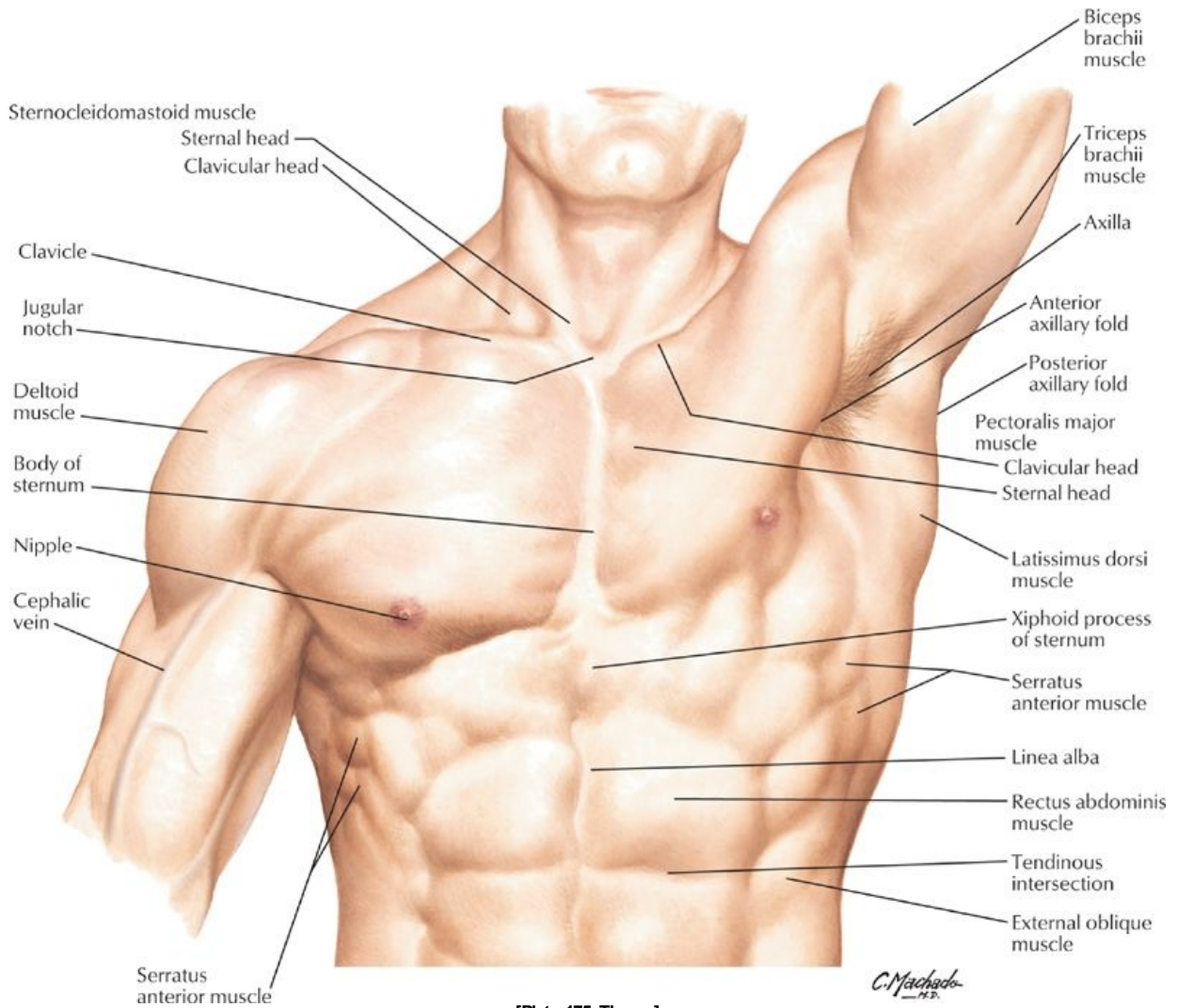
STUDY AIMS

At the end of your study, you should be able to:

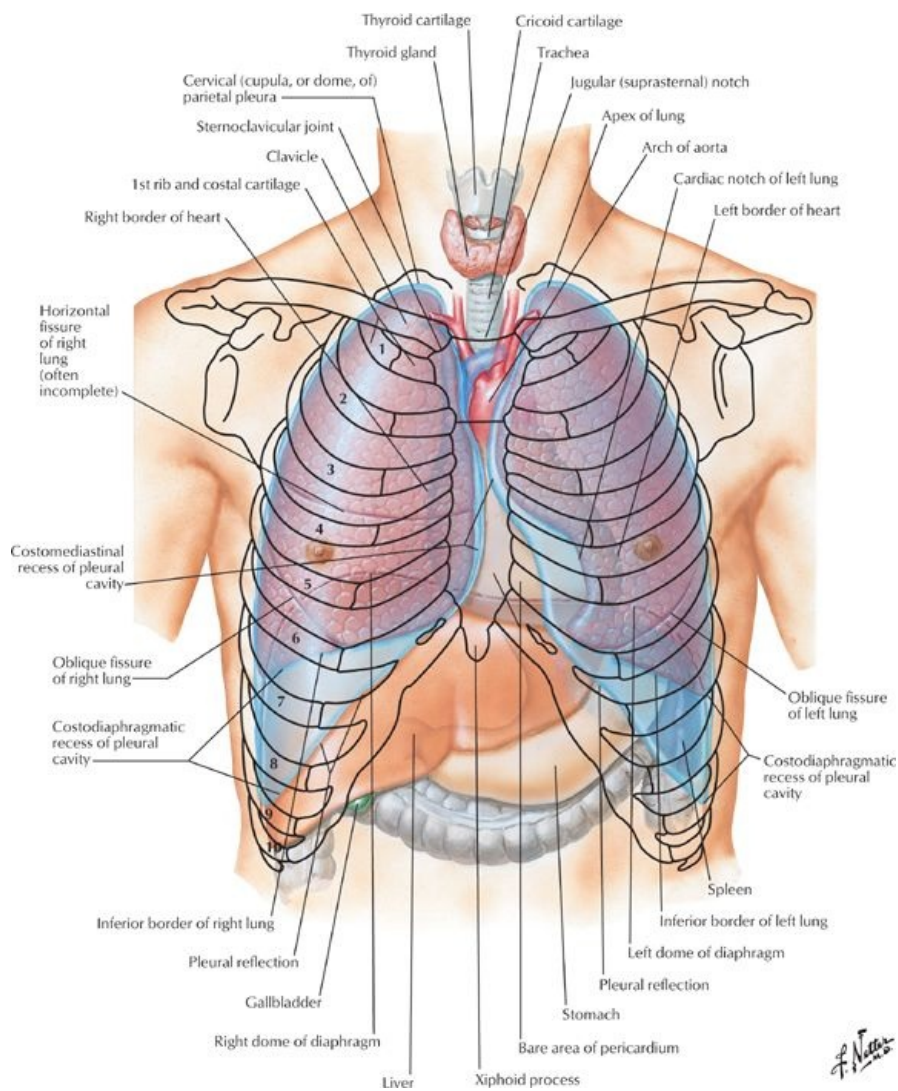
- Identify the major features of the surface anatomy of the chest wall
- Identify the location of the sternoclavicular and manubriosternal joints
- Know the types of these joints
- Palpate the sternum and its parts

GUIDES

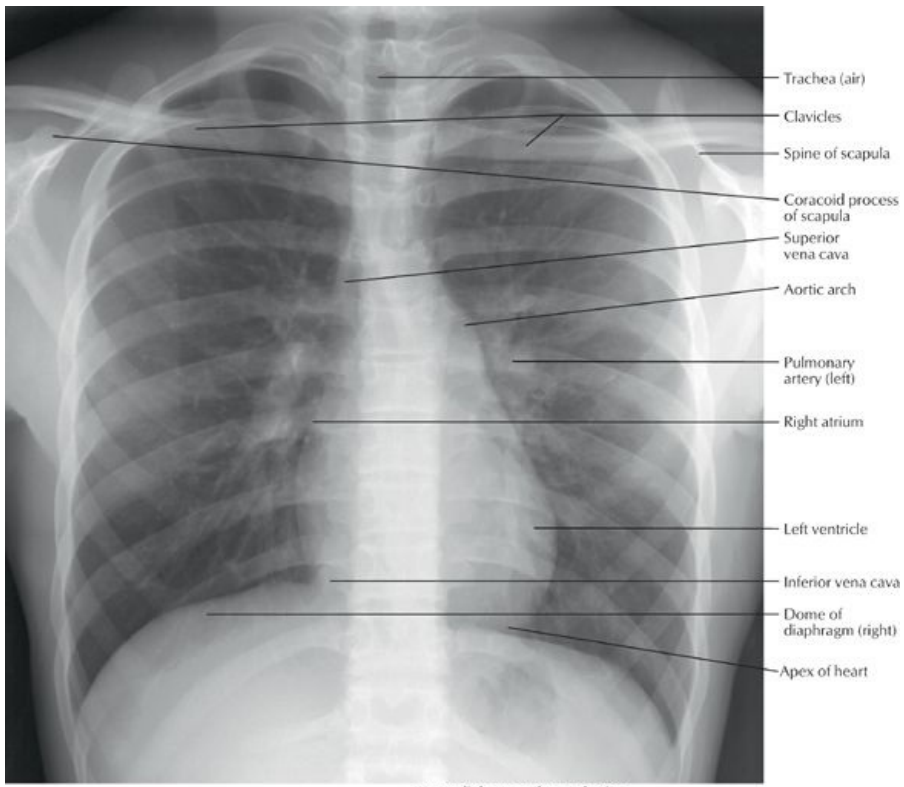
Thorax: Topographic Anatomy



[Plate 175, Thorax]

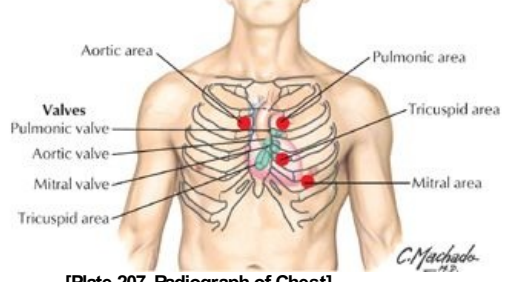


[Plate 190, Topography of Lungs: Anterior View]



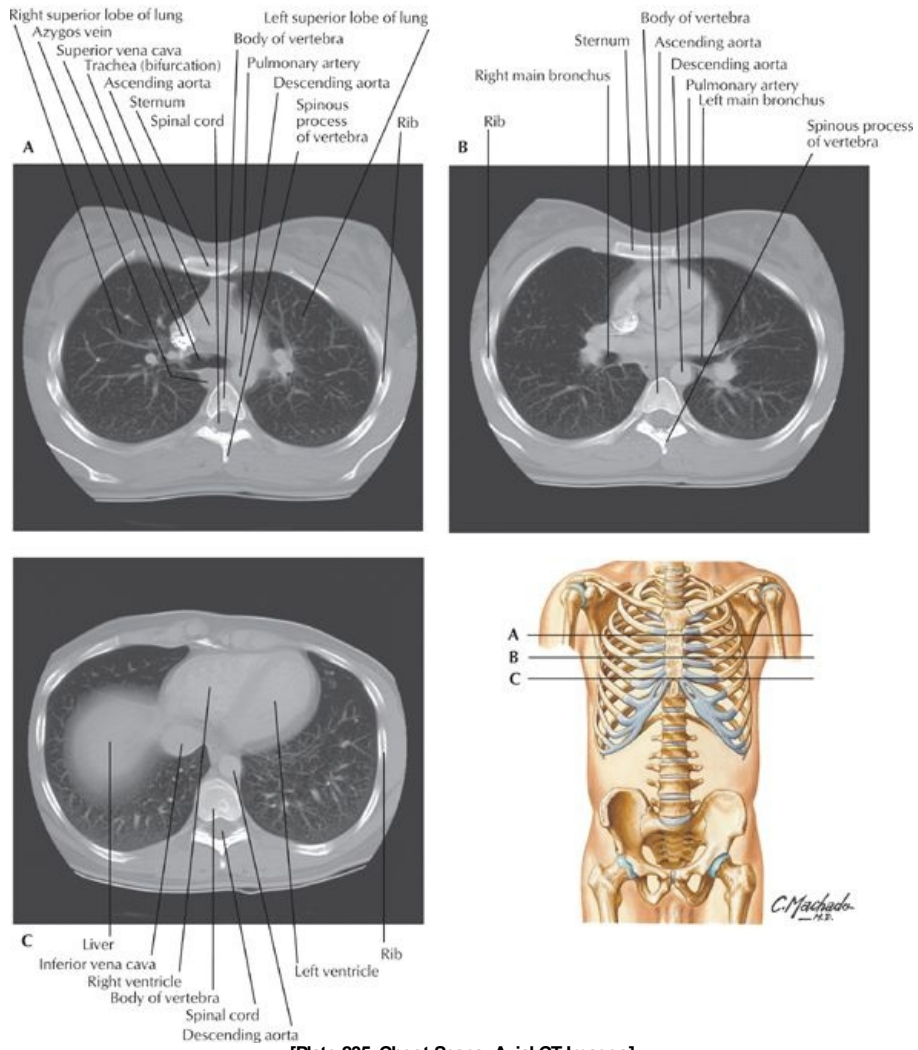
- Trachea (air)
- Clavicles
- Spine of scapula
- Coracoid process of scapula
- Superior vena cava
- Aortic arch
- Pulmonary artery (left)
- Right atrium
- Left ventricle
- Inferior vena cava
- Dome of diaphragm (right)
- Apex of heart

Precordial areas of auscultation

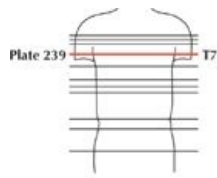


[Plate 207, Radiograph of Chest]

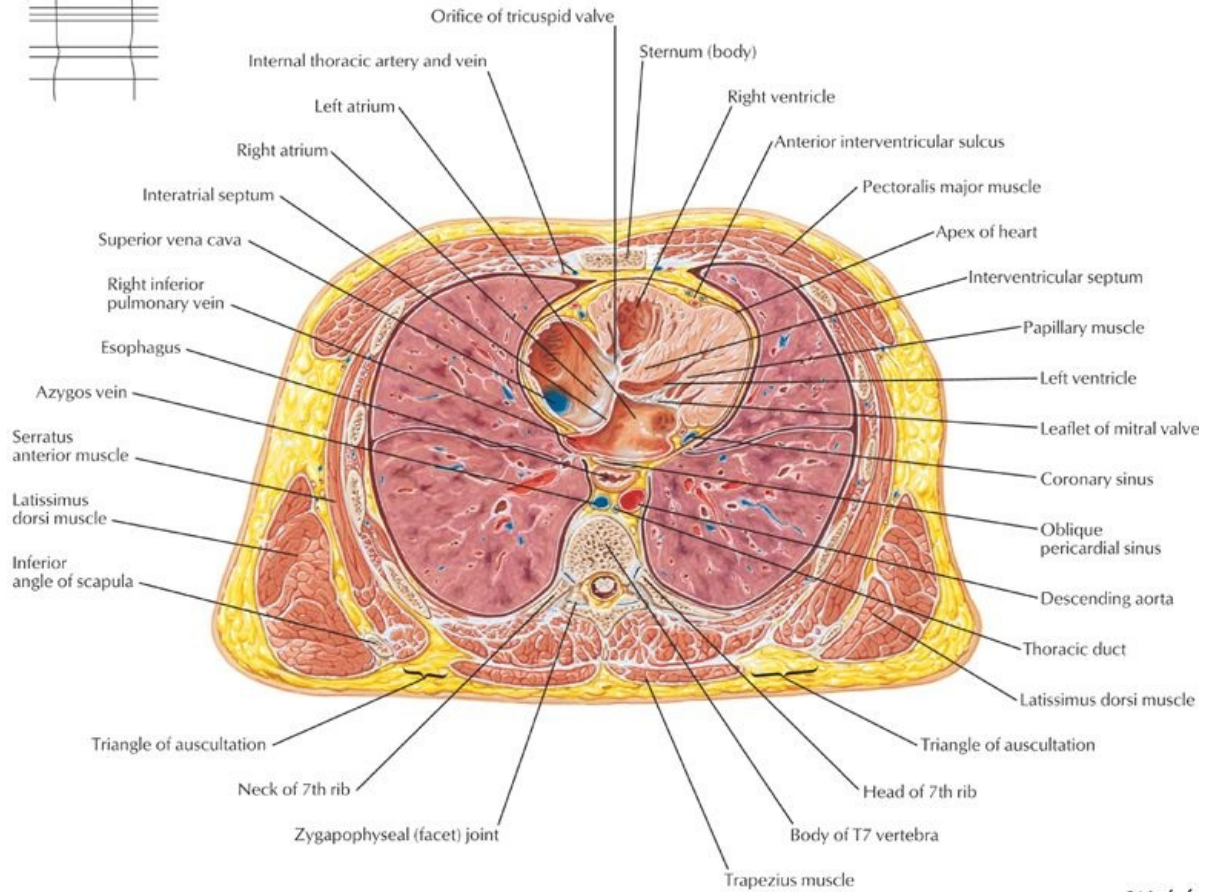
Series of chest axial CT images from superior (A) to inferior (C)



[Plate 235, Chest Scans: Axial CT Images]

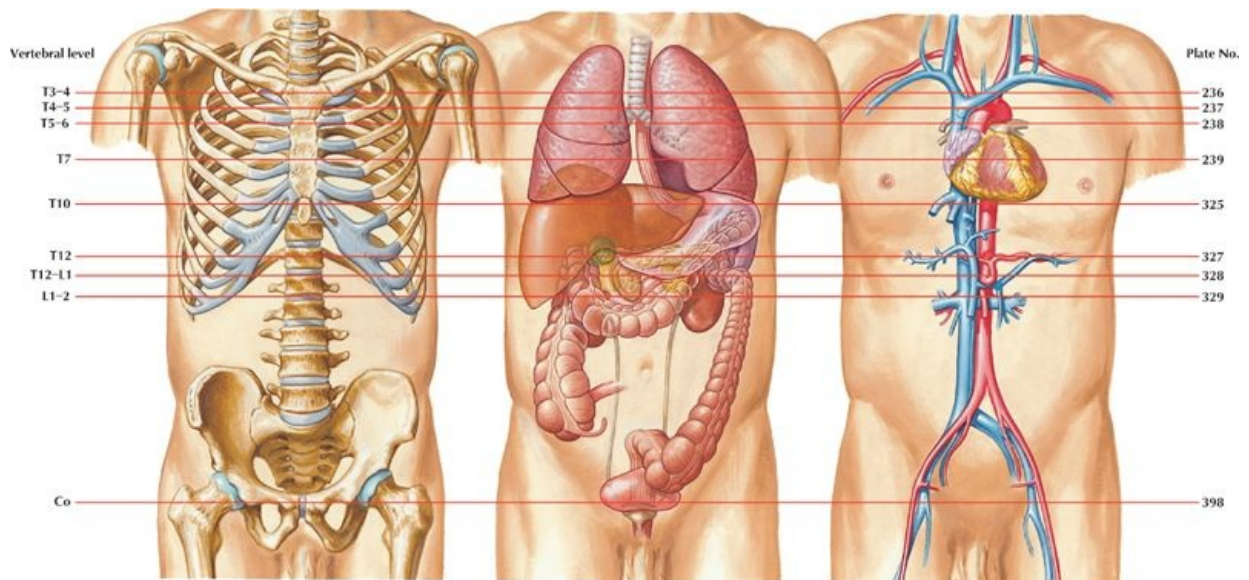


Transverse Section: Level of T7, 3rd Interchondral Space



[Plate 239, Cross Section of Thorax at T7 Level]

C. Machado



[Plate 532, Key Figures to Cross Sections]

C. Machado

- The thorax lies between the neck and the abdomen and lies within a cage formed by the vertebrae, the ribs, the sternum, the costal cartilages, and their attached muscles. The thoracic cage protects the contents of the thorax, whereas the muscles assist in breathing.
- It is important to identify and count ribs as they form key landmarks to the positions of the internal organs.
- In a fit muscular person one can identify a number of landmarks:
 - Jugular (suprasternal) notch: at the level of the inferior border of the T2 vertebra
 - Sternal angle (manubriosternal joint): at the level of the T4/5 intervertebral disc and where the second costal cartilages articulate with the sternum.
 - Manubrium: The left brachiocephalic vein runs beneath the manubrium from the upper left to lower right, where it joins the right brachiocephalic vein to form the superior vena cava

-
- Body of the sternum: Anterior to the T5 through T9 vertebrae and the right border of the heart
 - Nipple: Anterior to the 4th intercostal space in males and the dome of the right hemidiaphragm; sits on the pectoralis major muscle
 - Xiphoid process: At the level of the T10 vertebra
 - The costal margins: Comprises the 7th through 10th costal cartilages
 - On yourself, palpate the following:
 - The sternoclavicular joints, lateral to the jugular notch
 - The sternum and its parts: manubrium, body, and xiphoid process
 - The manubriosternal joint (sternal angle)
 - The second pair of ribs on either side of the sternal angle-the surface landmark for rib counting
 - Surface lines can be drawn to identify regions of the thorax
 - Imaginary perpendicular lines passing through the midpoint of each clavicle are called the midclavicular lines.
 - Midaxillary lines are perpendicular lines through the apex of the axilla on both sides
 - Cephalic vein can be seen in some subjects lying in the deltopectoral groove between the deltoid and pectoralis major muscles.

FACTS & HINTS

High-Yield Facts

Clinical Points

- The sternum can be divided to gain access to the thoracic cavity for surgical operations. This is called a median sternotomy.
- The middle ribs are most commonly fractured, and multiple rib fractures can manifest as a "flail chest," where the injured region of the chest wall moves paradoxically, that is, in on inspiration and out on expiration.

19 Mammary Gland

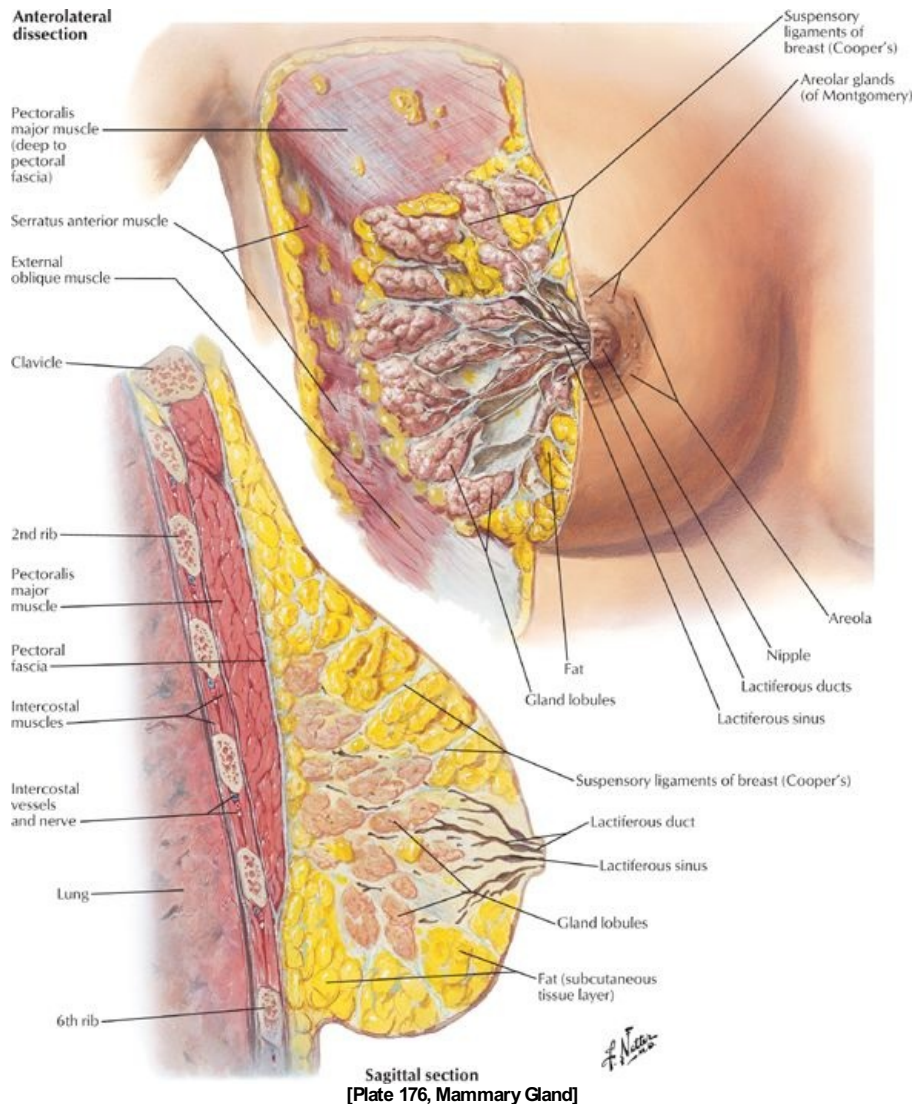
STUDY AIMS

At the end of your study, you should be able to:

- Identify the mammary gland
- Identify the location of the gland
- Locate the blood supply of the breast
- Understand the lymphatic drainage of the breast
- Know how to palpate the breast

GUIDES

Thorax: Mammary Gland



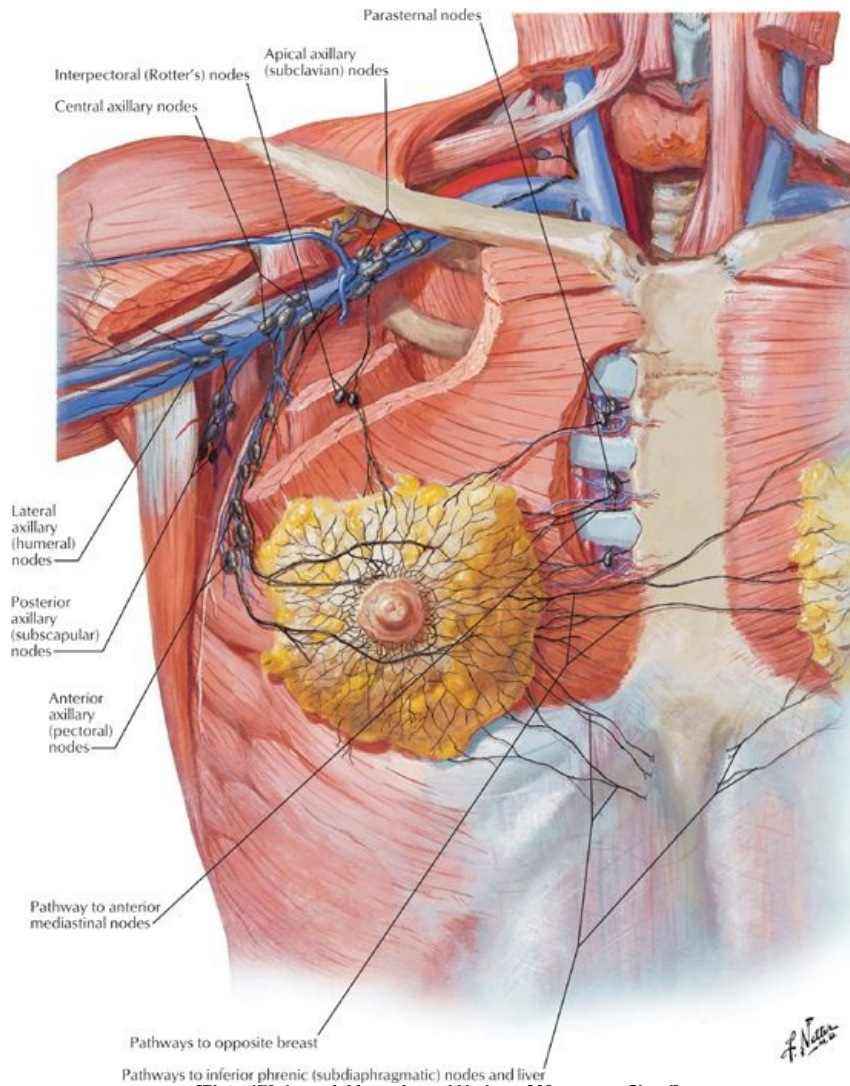
- Consists of glandular tissue in which the majority is embedded within the tela subcutanea (superficial fascia) of the anterior chest wall overlying the pectoral muscles.
- The glands are rudimentary in males and immature females.
- Size and shape of the adult female breast varies; the size is determined by the amount of fat surrounding the glandular tissue.
- The base of the breast is fairly consistent extending from the lateral border of the sternum to the midaxillary line and from the 2nd to the 6th ribs.
- The majority of the breast overlies the deep pectoral fascia of the pectoralis major muscle, with the remainder overlying the fascia of the serratus anterior.
- The breast is separated from the pectoralis major muscle by the retromammary space, a potential space filled with loose connective tissue.
- The breast is firmly attached to the overlying skin by condensation of connective tissue called the suspensory ligaments (of Cooper), which help to support the lobules of the breast.
- A small part of the mammary gland may extend toward the axilla, called the axillary tail (of Spence).

Structure of the Breast

- For descriptive purposes, the breast is divided into four quadrants: upper and lower lateral, and upper and lower medial.
- The most prominent feature of the breast is the nipple.
- The nipple is surrounded by the areola, a circular pigmented area of skin.
- The areola is pink in Caucasians and brown in African and Asian people.
- The pigmentation of the areola increases during pregnancy.
- The areola contains sebaceous glands, following a pregnancy these secrete an oily substance to protect the mother's nipple from irritation during nursing.
- The breast is composed of 15 to 20 lobules of glandular tissue, formed by the septa of the suspensory ligaments.
- The mammary glands are modified sweat glands that are formed from the development of milk-secreting alveoli, arranged in clusters.
- Each lobule is drained by a lactiferous duct
- Each lactiferous duct opens on the nipple.

- Blood supply of the breast arises from the perforating branches and anterior intercostal branches of the internal thoracic artery.
- The breast is also supplied by the branches of the thoracoacromial and lateral thoracic arteries (from the axillary artery).
- Venous drainage parallels the arterial supply and is mainly to the axillary artery and internal thoracic vein.

Lymphatic Drainage of the Breast



[Plate 178, Lymph Vessels and Nodes of Mammary Gland]

- Lymph from the nipple, areola, and lobules of the mammary glands drains to a subareolar lymphatic plexus.
- From there, a system of interconnecting lymphatic channels drains lymph to various lymph nodes.
- The majority of the lymph, especially from the lateral quadrants of the breast, drains to the pectoral nodes, and from there to the axillary nodes.
- The remaining amount of lymph, especially from the medial quadrants of the breast, drains into the parasternal lymph nodes along the internal thoracic vessels.
- Some lymph from the lower quadrants of the breast passes to the inferior phrenic nodes.
- It is important to note that lymph from the medial quadrants can cross to the opposite breast.
- Thus secondary metastases of breast carcinoma can spread to the opposite breast in this way.

FACTS & HINTS

High-Yield Facts

Clinical Points

Examination of the Breast

- Clinically the breast is divided into quadrants:
 - UI: upper inner
 - UO: upper outer (includes axillary tail)
 - LI: lower inner
 - LO: lower outer
- The breast is palpated in a circular fashion, beginning with the nipple and moving outward. The palpation should extend into the axilla to palpate the axillary tails.
- After palpation of one breast, the other should be palpated in the same way.
- Examine the skin of the breast for a change in texture or dimpling (peau d'orange sign) and the nipple for retraction, since these signs may indicate an underlying pathology.

Pathology of the Breast

- **Fibroadenoma:** benign tumor, usually a solid and solitary mass that moves easily under the skin. Often painless although sometimes tender on palpation. More common in young women but can occur at any age.
- **Intraductal carcinoma or breast cancer:** the commonest type of malignancy in women but can also occur in men. Approximately 50% of cancers develop in the upper quadrant of the breast; metastases from these cancers often spread to the axillary lymph nodes. This malignancy presents as a palpable mass that is hard, immobile and sometimes painful. Additional signs can include bloody or watery nipple discharge if the larger ducts are involved.
- **Gynecomastia:** enlargement of the breasts in males because of aging, drug treatment, and changes in the metabolism of sex hormones by the liver.

20 Body Wall

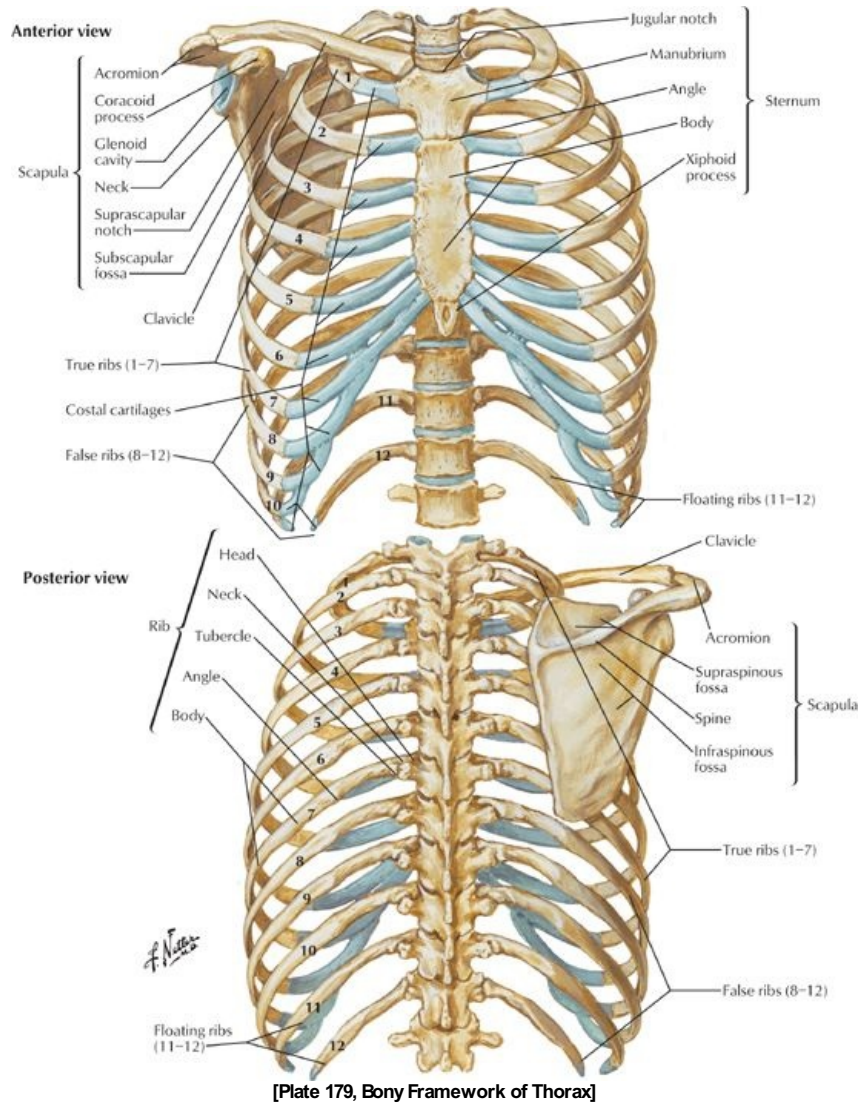
STUDY AIMS

At the end of your study, you should be able to:

- Identify muscles of the anterior chest wall and know their attachments, actions, and innervation
- Identify the intercostal muscles
- Identify the ribs and their parts
- Count ribs
- Understand the organization of a typical intercostal space and clinical significance of its contents

GUIDES

Thorax-Body Wall Organization



[Plate 179, Bony Framework of Thorax]

Layers

First and second layers

- Skin
- Tela subcutanea (superficial fascia), including the breasts

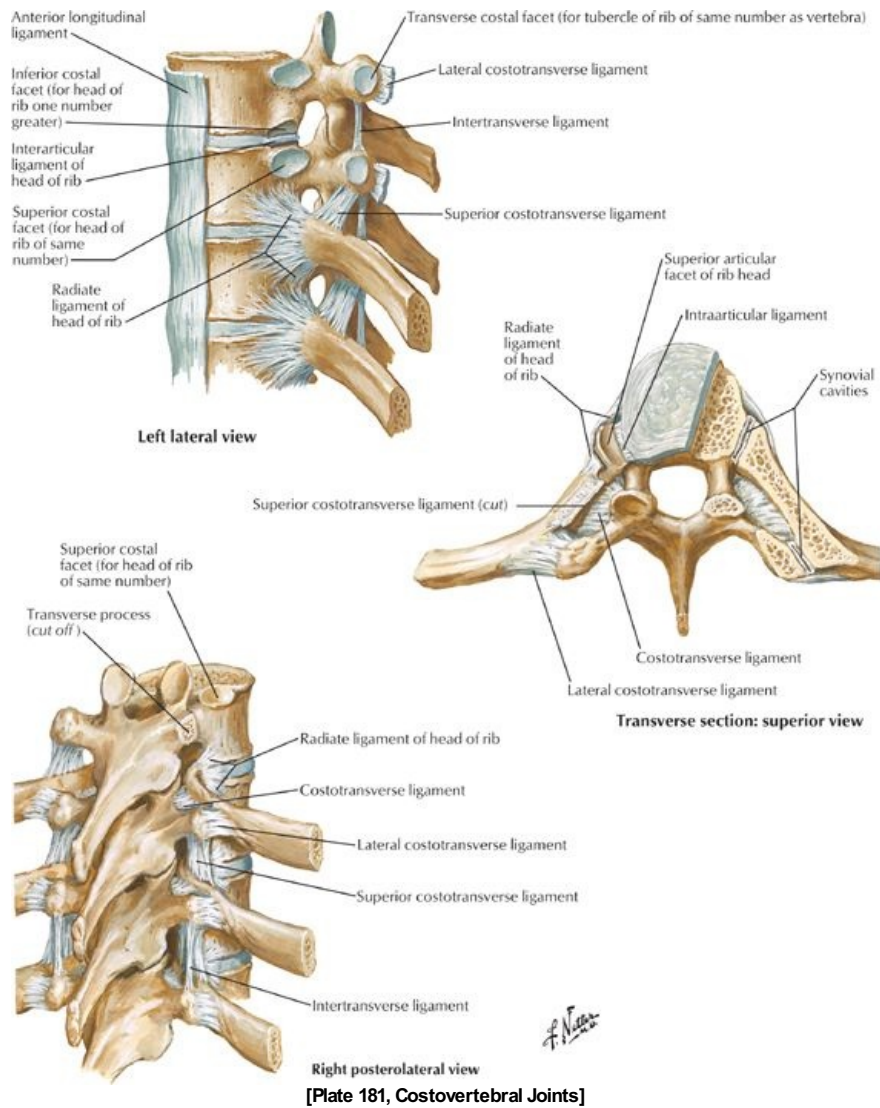
Third layer-muscles moving the upper limb

- pectoralis major
- pectoralis minor
- serratus anterior

Fourth layer-includes muscles of the chest wall

- Ribs
- Intercostal muscles
 - External intercostal muscles
 - Internal intercostal muscles
 - Innermost intercostal muscles

Intercostal muscles



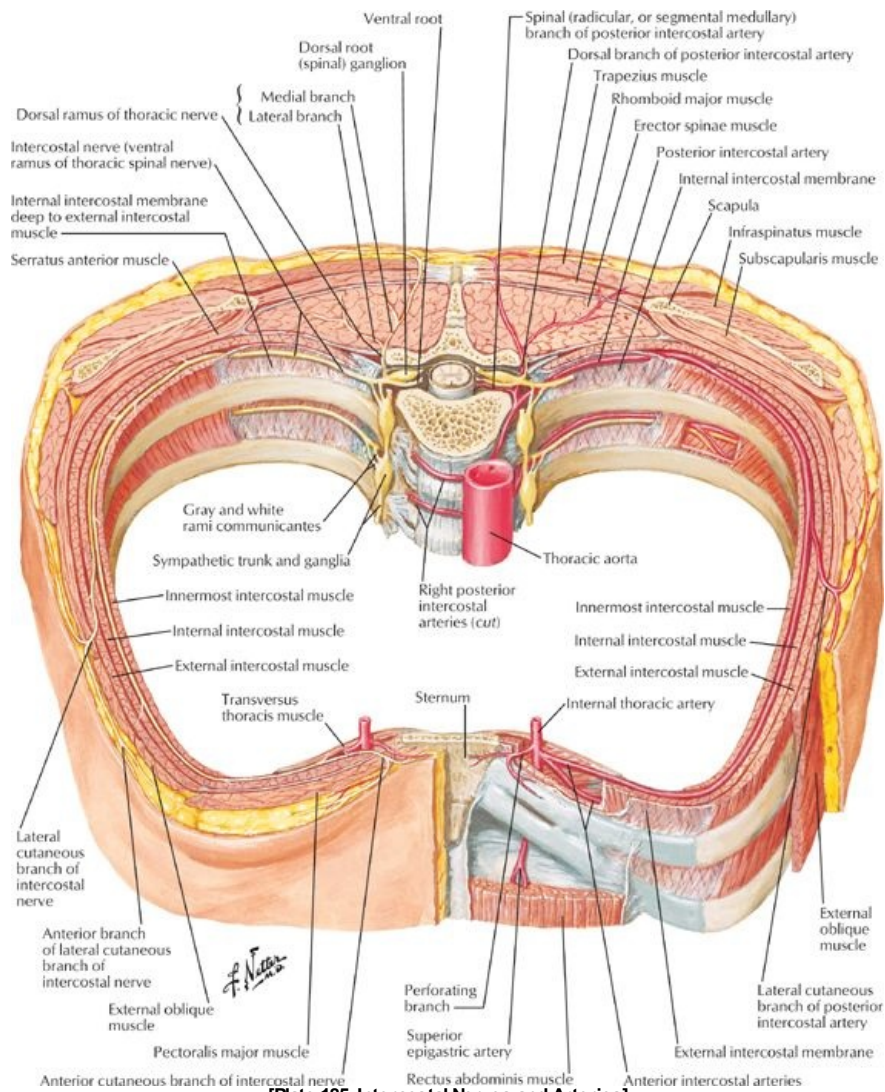
- These muscles are arranged in three layers.
- External intercostal muscles:
 - Have fibers that slope down and medially.
 - Extend from the posterior tubercle of the rib to the junction of the rib and its costal cartilage anteriorly.
 - Anteriorly, are replaced by external intercostal membranes that extend from the costochondral junctions to the sternum.
- Internal intercostal muscles:
 - Lie internal to the external intercostal muscles
 - Their fibers lie at right angles to those of the external intercostal muscles and run inferiorly and laterally.
 - Anteriorly extend to the lateral border of the sternum.
 - Posteriorly extend only to the angles of the ribs; medial to the angles, are replaced by the internal intercostal membranes.
- Innermost intercostal muscles
 - Lie deep to the internal intercostal muscles
 - Are separated from the internal intercostals by the intercostal vessels and nerves
 - Occupy the middle parts of the intercostal spaces
 - Connect inner surfaces of adjacent ribs
- All intercostal muscles are supplied by intercostal nerves corresponding in number to their intercostal space.
- Main action of the intercostals is to maintain the space between the ribs during inspiration and expiration.
- Other muscles of the rib cage
 - Subcostal muscles-internal to the internal intercostals, cross from the angle of one rib to internal surface of the rib 1 to 2 spaces below.
 - Transversus thoracis-4 to 5 slips of muscle that attach to the xiphoid process and inferior sternum and pass superiorly and laterally to attach to the 2nd through 6th costal cartilages.

Muscle	Superior Attachment (Origin)	Inferior Attachment (Insertion)	Innervation	Blood Supply	Main Actions
External intercostal	Inferior border of rib	Superior border of rib below	Intercostal nerve	Aorta, posterior intercostals and their collaterals, costocervical trunk, anterior intercostals of internal thoracic and musculophrenic arteries	Elevate ribs
Internal	Inferior border	Superior border	Intercostal	Anterior intercostals, posterior intercostals,	Elevate ribs (upper

intercostal	of rib	of rib below	nerve	musculophrenic artery and costocervical trunk	four and five); others depress ribs
Innermost intercostal	Inferior border of rib	Superior border of rib below	Intercostal nerve	Posterior intercostals and collaterals	Act similar to internal intercostals
Transversus thoracis	Internal surface of costal cartilages 2-6	Posterior surface of lower sternum	Intercostal nerve	Anterior intercostals, internal thoracic artery	Depress ribs and costal cartilages
Subcostal	Internal surface of lower rib near their angles	Superior borders of second or third ribs below	Intercostal nerve	Posterior artery, musculophrenic artery	Depress ribs
Levator costarum	Transverse processes of C7 and T1-T11	Subjacent ribs between tubercle and angle	Dorsal primary rami of C8-T11	Posterior intercostals	Elevate ribs

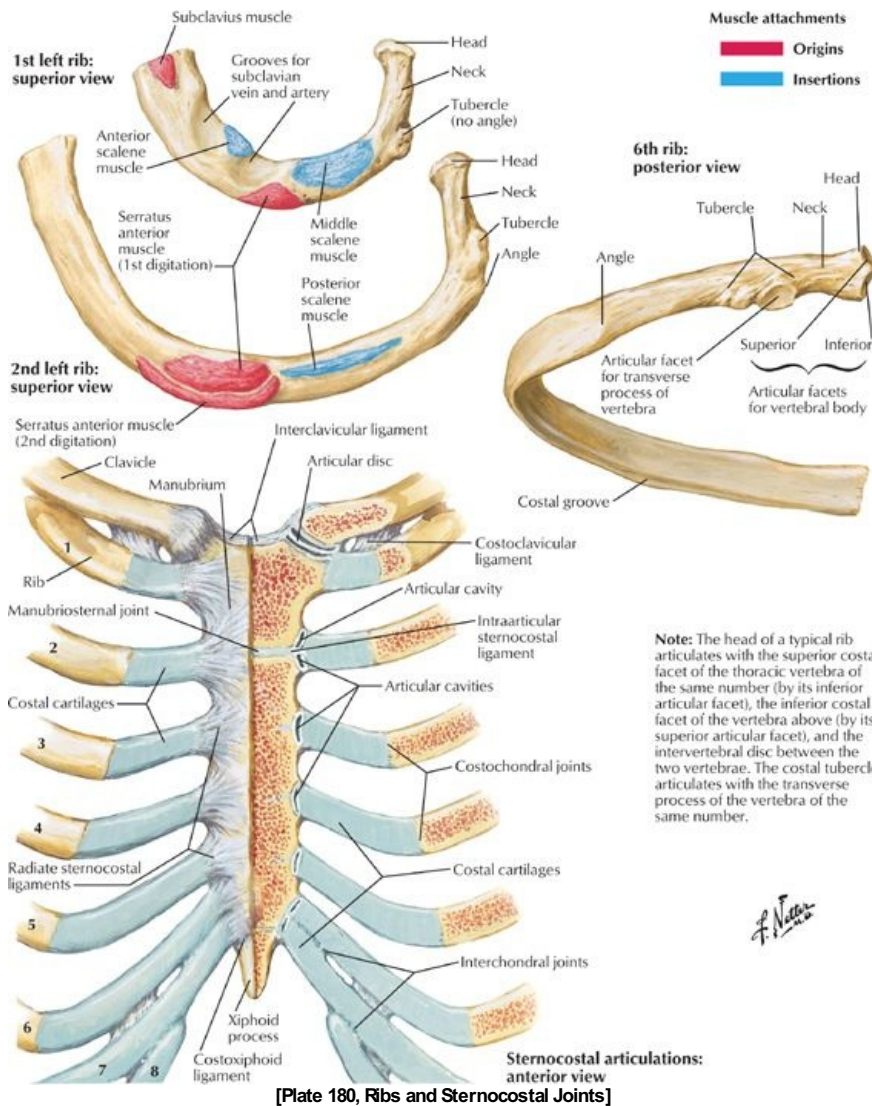
page 102
page 103

Intercostal nerves

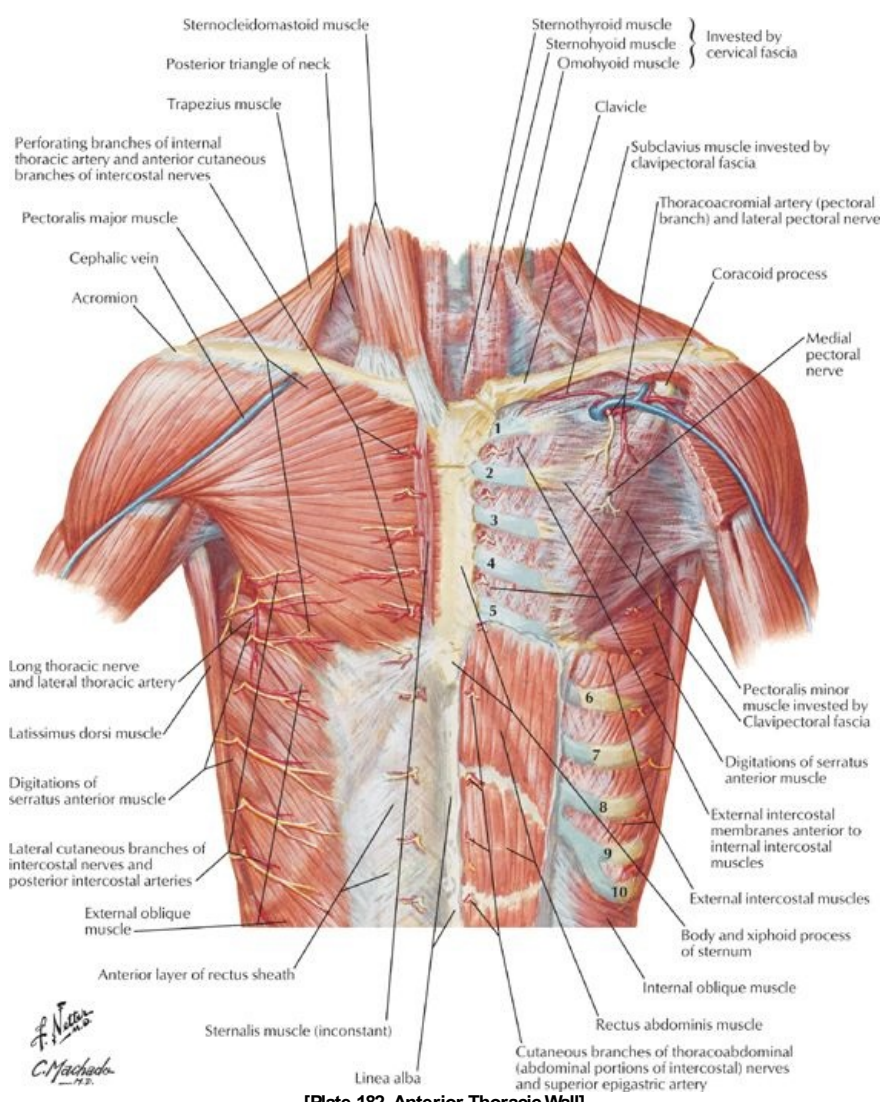


[Plate 185, Intercostal Nerves and Arteries]

- Intercostal nerves arise from the ventral rami of the upper eleven thoracic spinal nerves
- Each intercostal nerve divides to give a lateral cutaneous branch near the midaxillary line
- Anterior cutaneous branches innervate the skin on the anterior abdomen and thorax and divide into medial and lateral branches.
- Muscular branches supply the intercostal, levatores costarum, transversus thoracis, and serratus posterior muscles.
- The lower five intercostal nerves supply the skin and muscles of the abdominal wall
- Contain general somatic afferent and efferent fibers, as well as general visceral efferent fibers from the sympathetic trunk via white and grey rami communicantes and general visceral afferent fibers.

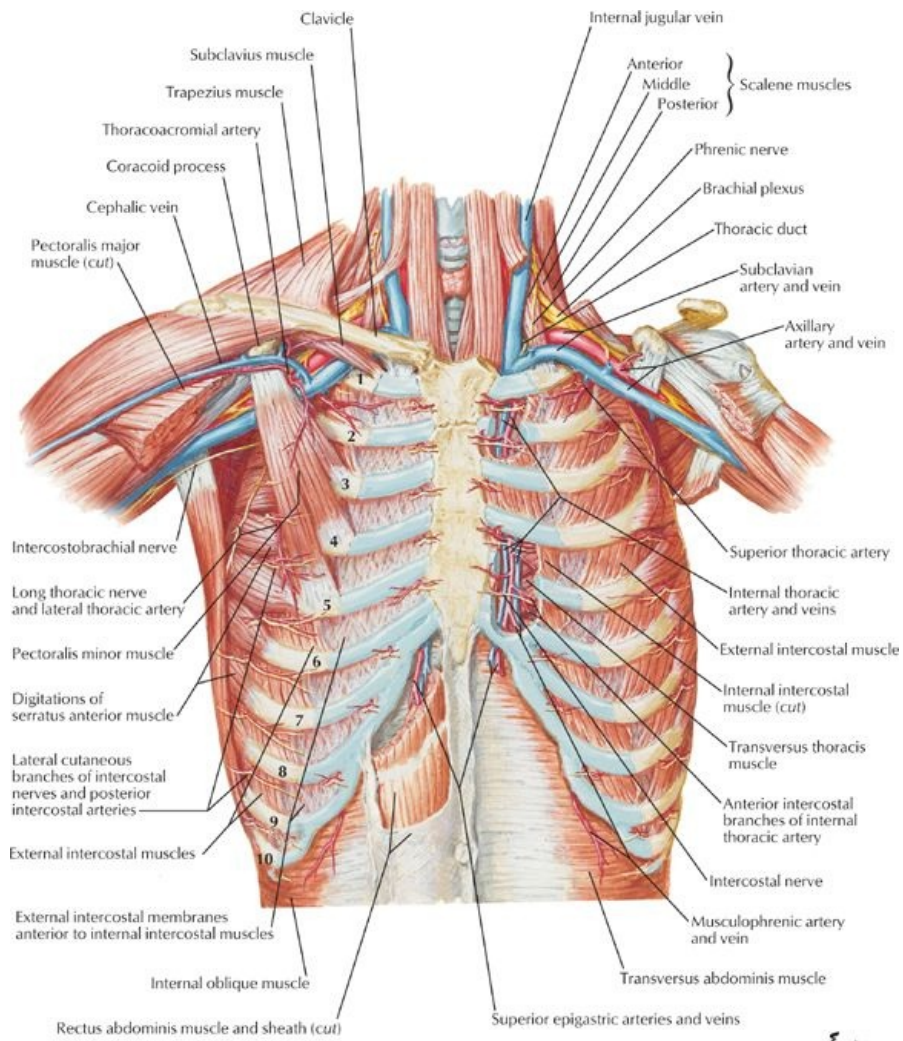


- All ribs contain bone marrow.
- Ribs 1 through 7 are vertebrocostal because they attach to the sternum via a costal cartilage.
- Ribs 8 through 10 are vertebrochondral because their cartilages are joined to the cartilage of the rib above and via that connection to the sternum.
- Ribs 11 and 12 are free or floating ribs, which do not connect even indirectly with the sternum but which have a costal cartilage on their tips.
- First rib is broad and sharply curved and has a tubercle of the attachment of scalene muscles.



[Plate 182, Anterior Thoracic Wall]

*F. Netter
C. Machado*



[Plate 183, Anterior Thoracic Wall (Continued)]

FACTS & HINTS

High-Yield Facts

Clinical Points

page 103
page 104

Important Vertebral Landmarks

- Spine of the scapula T2:
- Sternal angle (of Louis); level of the bifurcation of trachea, arch T4/T5: of aorta
- Level of the heart T5-T8:
- Aortic hiatus of the diaphragm; also transmits the thoracic duct T12:
- Esophageal hiatus of the diaphragm; also transmits the right and left T10: vagal trunks, esophageal branches of left gastric vessels and lymphatics
- Caval opening of the diaphragm; also terminal branches of the right T8: phrenic nerve

Thoracentesis

- Thoracentesis is the insertion of a needle into the pleural cavity to withdraw a sample of fluid or blood. To avoid damage to the intercostal vein, artery, and nerve that run in the costal groove on the inferior surface of each rib, the needle is inserted well below the rib. The needle also must be placed sufficiently above the rib below to avoid the collateral branches of intercostal nerve and vessels that run along the superior surface of each rib.

Importance of Certain Intercostal Spaces

- Second intercostal space at the midclavicular line: Insertion of tube for an apical pneumothorax (thoracostomy)
- Fourth to 6th intercostal space at the midaxillary line: Insertion of chest drains for a hemothorax (thoracostomy)
- Left 5th intercostal space: apex beat of the heart and this is shifted in heart enlargement

Cervical Ribs

- Cervical ribs are not common (less than 1% of all persons). They articulate with the C7 vertebra, but do not attach to the sternum. They may fuse with the first rib. If a cervical rib is present, however, it may compress the subclavian artery or inferior trunk of the brachial plexus and cause ischemic pain and numbness in the shoulder and upper limb. This condition is called **thoracic outlet syndrome**.

Bone Marrow Biopsy and Aspiration.

- Bone marrow aspiration and biopsy help diagnose many blood disorders and can be used to detect if cancer has spread to the bone marrow.
 - Bone marrow biopsy: The removal of bone and marrow for examination under the microscope. The sternum is a site of red marrow, even in adulthood, and is a good site for a bone marrow biopsy. Another common site is the posterior iliac crest. A biopsy is usually conducted before performing a bone marrow aspiration.
 - Bone marrow aspiration: The removal of a small amount of bone marrow fluid through a needle inserted into the bone. Fluid is examined to determine if there are any problems with the blood cells made in the bone marrow

Mnemonics

Memory Aids

Vertical order of the contents of the neurovascular bundle in the costal groove on the lower border of each rib:

VAN Vein, Artery, Nerve.

21 Lungs

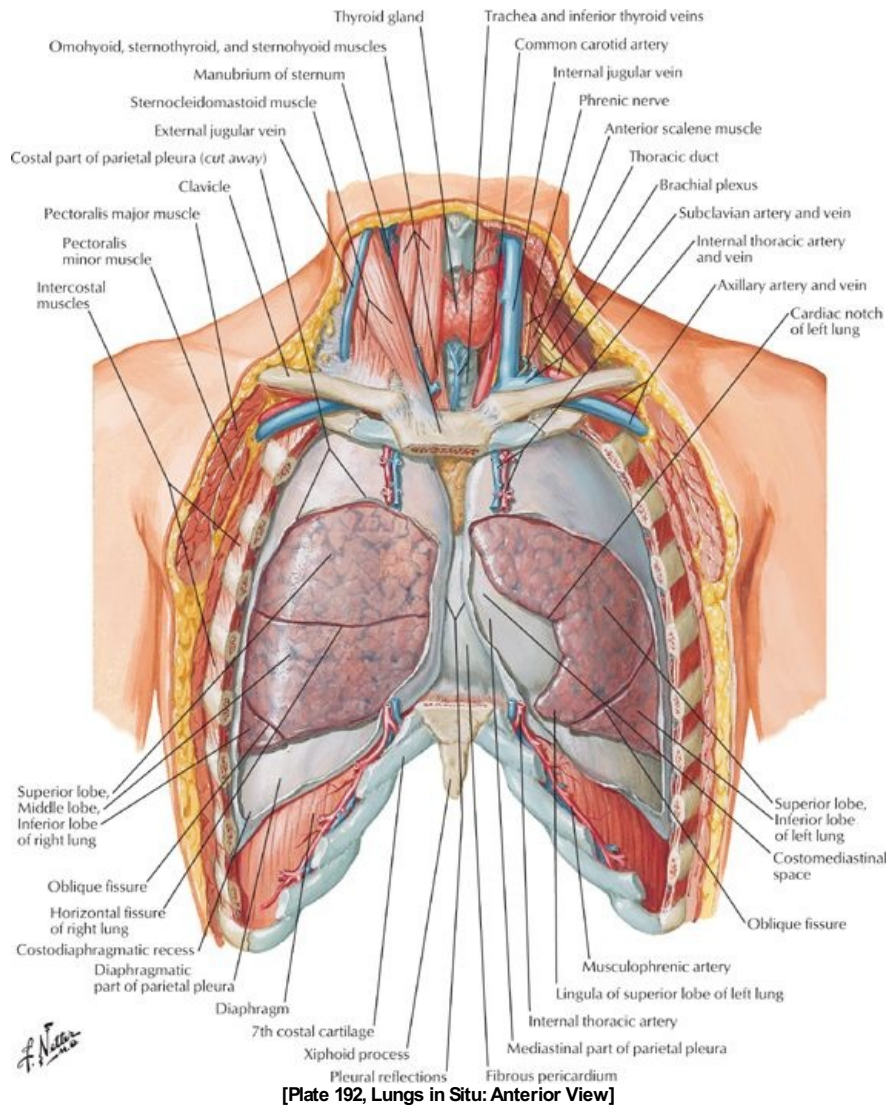
STUDY AIMS

At the end of your study, you should be able to:

- Understand the relationship of the pleural cavities to the mediastinum
- Identify the pleurae and the parts of the parietal pleura
- Understand the anatomy of the lungs
- Know the segments of the lungs
- Understand vasculature and innervation of the lungs and the pleurae

GUIDES

Thorax: Lungs



[Plate 192, Lungs in Situ: Anterior View]

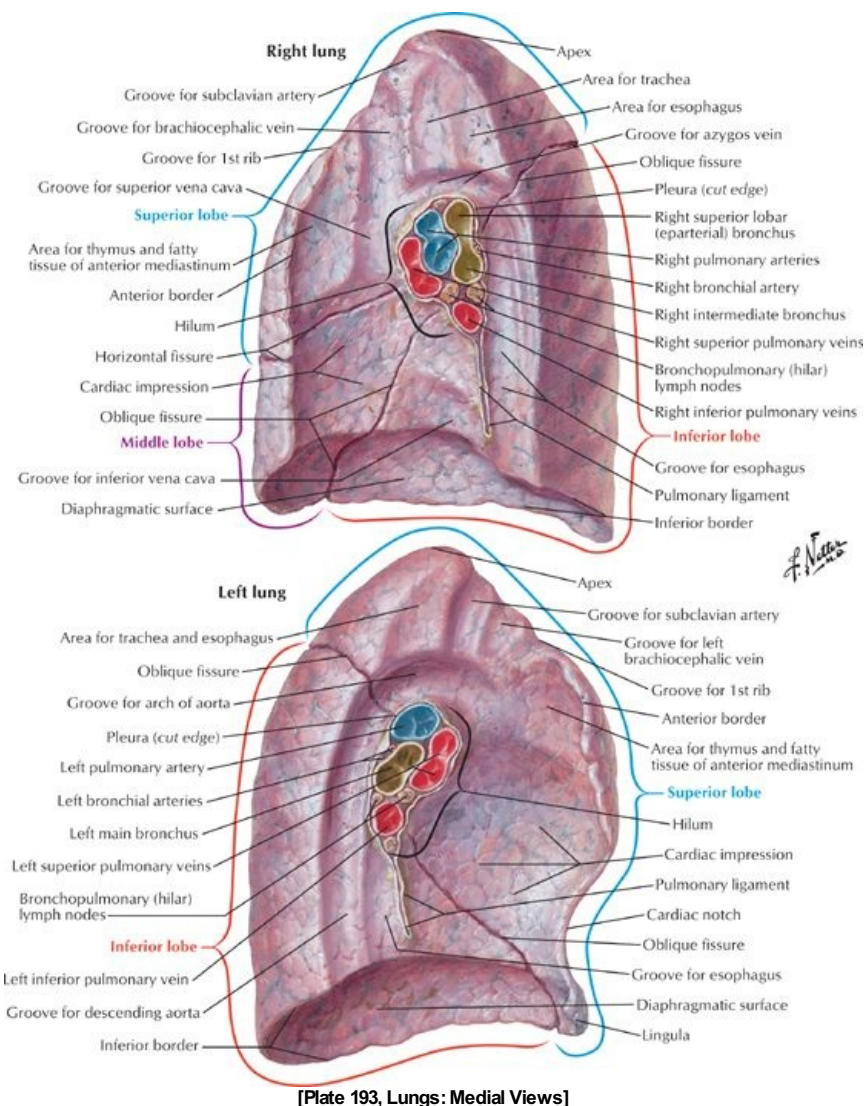
Thoracic Cavity, Pleurae and Pleural Cavity

- Thoracic cavity has
 - two lateral pleural cavities, containing the lungs and pleurae
 - a central compartment, the mediastinum, containing all the other thoracic structures
- Each lung is surrounded by, and covered with, a continuous membrane, which is defined as
 - the visceral pleura, which covers the lungs and cannot be dissected from the lung
 - the parietal pleura, which lines the pleural cavities
- The visceral and parietal pleura are continuous at the hilum of the lung where structures enter and leave the lung (bronchus, pulmonary vessels, bronchial vessels, lymphatics)
- The parietal pleura has four named parts:
 - Costal pleura lining the internal surface of the thoracic wall
 - Mediastinal pleura covering the sides of the mediastinum
 - Diaphragmatic pleura covering the superior surface of the dome of each hemidiaphragm
 - Cervical pleura—a dome of pleura extending superiorly into the superior thoracic aperture
- Visceral pleura does not have any general sensory innervation and is insensitive to pain
- The parietal pleura is very sensitive to pain because of its sensory supply by branches of the intercostal and phrenic nerves
- The pleural cavity is the potential space between the parietal and visceral pleura.
 - The pleural cavity contains a thin layer of serous pleural fluid, which lubricates and allows the pleurae to move smoothly over each other during respiration.
 - Surface tension keeps the lung surface in contact with the thoracic wall.
 - The lung expands and fills with air when the thoracic cavity expands.

Lines of pleural reflection

- Lines of pleural reflection are lines along which the parietal pleura changes directions from one wall to another.
 - The sternal line of pleural reflection is the sharp line along which the costal pleura becomes the mediastinal pleura
 - The costal line of pleural reflection is the sharp line along which the costal pleura becomes the diaphragmatic pleura
 - The vertebral line of pleural reflection is a smooth reflection of the costal pleura onto the vertebrae posteriorly.
- The lines of pleural reflection on the left side can be remembered as 4-6-8-10-12.
 - The line of pleural reflection on the left descends in the midline of the sternum to the 4th costal cartilage, where it deviates to the left margin of the sternum at the 6th costal cartilage to accommodate the pericardium and the heart (cardiac notch).
 - This line then deviates to cross the 8th rib at the midclavicular line.
 - It crosses the 10th rib at the midaxillary line
 - It then crosses the 12th rib at approximately the neck.
- On the right side, the line of pleural reflection descends at the midline of the sternum to the xiphoid process, and then deviates 8-10-12.
- The lungs do not fully occupy the pleural cavities during expiration
- There are peripheral areas where the diaphragmatic and costal pleura come in contact and these are called the costodiaphragmatic recesses.
- There are areas posterior to the sternum where the costal and mediastinal pleura come in contact with each other, and these are called costomediastinal recesses.
- The costomediastinal recess is larger on the left, because of the cardiac notch.
- During expiration, the lower limit of the lungs is two costal spaces above the line of pleural reflection:
 - 6-8-10: the sixth rib at the midclavicular line, the 8th rib at the midaxillary line, and the 10th rib at the neck.
 - Thus the costodiaphragmatic recess is approximately two costal spaces deep.

Lungs



[Plate 193, Lungs: Medial Views]

- Organs of respiration
- Light, soft and elastic
- The right lung is larger than the left and has three lobes:
 - Superior or upper
 - Middle
 - Inferior or lower
- The left lung has two lobes
 - Superior or upper
 - Inferior or lower

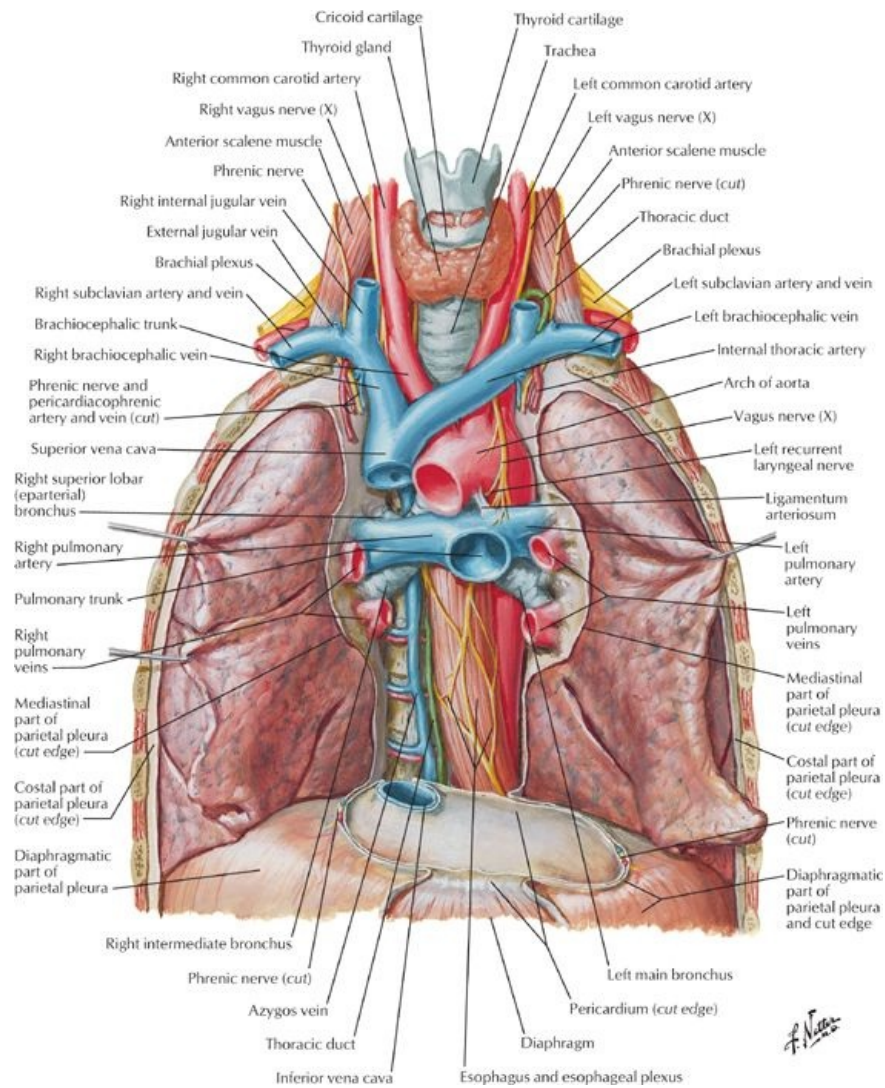
- Fissures divide the lungs into lobes
 - Each lung has an oblique fissure, separating the upper lobe from the lower lobe on the left and the upper and middle lobes from the lower lobe on the right
 - The right lung has a horizontal fissure, separating the middle lobe from the upper lobe on the right
- The oblique fissure runs from the 2nd thoracic vertebra posteriorly to the 6th costal cartilage anteriorly, or along the medial border of the scapula when the arm is raised above the head.
- The horizontal fissure runs from the oblique fissure at the midaxillary line along the 4th rib to its costal cartilage anteriorly.
- The anterior margin of the left lung has an indentation-the cardiac notch, which often creates a thin process in the upper lobe called the lingula.
- Each lung has three surfaces:
 - Costal
 - Mediastinal
 - Diaphragmatic
- Each lung is connected to the mediastinum by the root of the lung.
- Lung root contains:
 - Main stem or lobar bronchi
 - Pulmonary vessels and bronchi.
 - Bronchial vessels, lymphatics, and autonomic nerves.
- The lung root is surrounded by a pleural sleeve, from which extends the pulmonary ligament inferiorly.
- The pulmonary ligament

page 106
page 107

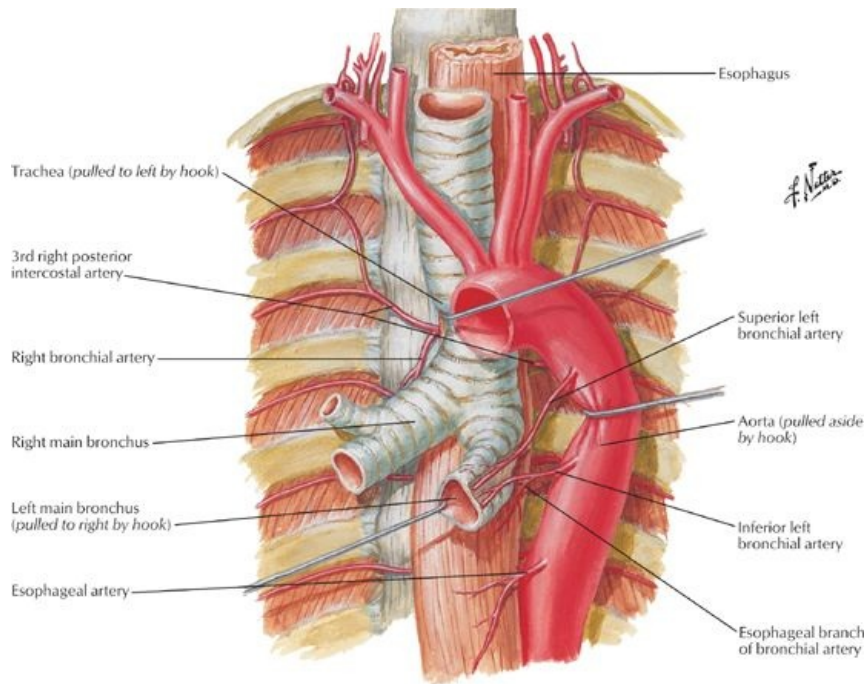
Bronchopulmonary segments

- The trachea bifurcates into two main stem bronchi, right and left, at the level of the T4/5 intervertebral disc (also the sternal angle of Louis).
- The carina is the keel-like ridge between the two openings of the main stem bronchi.
- The right main stem bronchus divides into upper and lower lobar bronchi before reaching the substance of the right lung.
- The main bronchi branch to form the bronchial tree.
- There are three lobar bronchi on the right: upper, middle, and lower
- There are two lobar bronchi on the left: upper and lower
- Each lobar bronchus branches into segmental bronchi that supply a bronchopulmonary segment.
- A bronchopulmonary segment
 - Is a pyramidally shaped section of the lung with its base covered by visceral pleura
 - Is separated from adjacent segments by connective tissue septa
 - Is named for the segmental bronchus that supplies it
 - Has its own bronchus and segmental branch of the pulmonary artery
- Each bronchopulmonary segment can be surgically resected, independent of adjacent segments
- The right lung has 10 bronchopulmonary segments
 - Upper lobe: Apical
 - Anterior
 - Posterior
 - Middle lobe: Medial
 - Lateral
 - Lower lobe: Superior
 - Anterior basal
 - Posterior basal
 - Medial basal
 - Lateral basal
- The left lung has 8 to 10 bronchopulmonary segments
 - Upper lobe: Apical (may be combined with posterior to form apicoposterior)
 - Posterior
 - Anterior
 - Superior lingular
 - Inferior lingular
 - Lower lobe: Superior
 - Anterior basal (may be combined with medial to form anteromedial basal)
 - Medial basal
 - Lateral basal
 - Posterior basal
- The right main stem bronchus is wider and shorter than the left one and descends in a more vertical plane, so aspirated foreign objects are more likely to lodge in it or one of its branches
- Because the posterior segmental bronchus of the right lower lobe runs directly posterior, foreign objects that are inhaled when the person is lying down, such as food, may end up in this segmental bronchus.

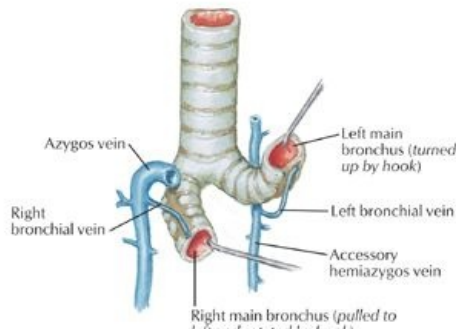
Vasculature of the lungs



[Plate 200, Great Vessels of Superior Mediastinum]



Bronchial veins



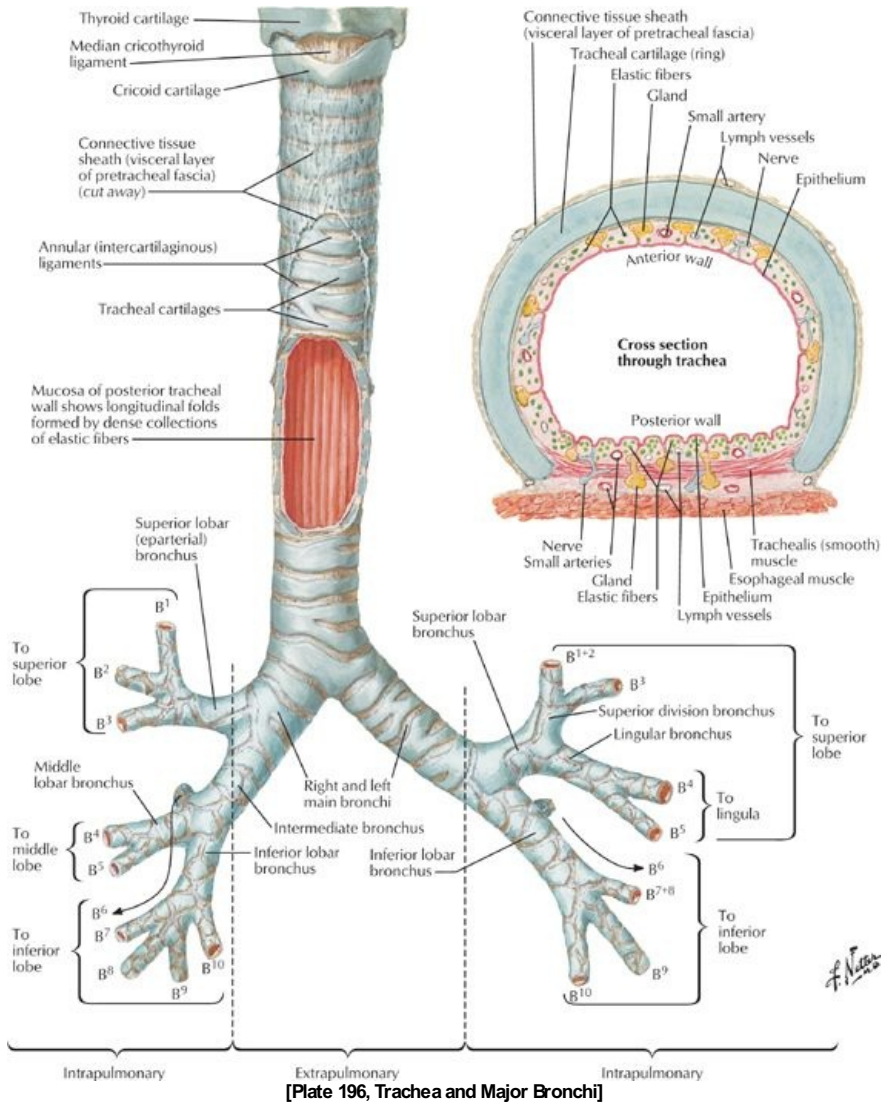
[Plate 201, Bronchial Arteries and Veins]

page 107
page 108

- Each lung is supplied by a pulmonary artery, which carries unoxygenated blood from the pulmonary trunk from the right ventricle of the heart.
- Each pulmonary artery gives rise to lobar and segmental arteries.
- Intrasegmental veins drain to intersegmental veins in the pulmonary septa, which run a separate course from the pulmonary and segmental arteries and which drain to two pulmonary veins for each lung.
- Pulmonary veins carry oxygenated blood to the left atrium of the heart.
- Bronchial arteries from the thoracic aorta carry oxygenated blood to the tissue of the lungs, traveling along the posterior surface of the bronchi.
- The left bronchial arteries come from the thoracic aorta; the single right bronchial artery may also arise from the superior posterior intercostal or a left superior bronchial artery.
- The bronchial arteries anastomose with branches of the pulmonary arteries.
- Pulmonary veins drain the blood to the lungs supplied by the bronchial veins and empty into the azygos and accessory hemiazygos veins.
- The lungs have a rich, freely connecting network of lymphatic vessels.
- Lymph from the lungs drains to
 - Pulmonary lymph nodes (along the lobar bronchi)
 - Bronchopulmonary lymph nodes (along the main stem bronchi)
 - Superior and inferior tracheobronchial lymph nodes (superior and inferior to the bifurcation of the trachea)

Innervation of the lungs

- Innervation is via the pulmonary plexuses located anterior and posterior to the lung roots.
- The plexuses contain postganglionic sympathetic fibers from the sympathetic trunks that innervate the smooth muscle of the bronchial tree, pulmonary vessels, and glands of the bronchial tree.
- Sympathetic fibers are bronchodilators, vasoconstrictors, and inhibit glandular secretion.
- The plexuses contain preganglionic parasympathetic fibers from the vagus nerve (CN X), small parasympathetic ganglia, and postganglionic parasympathetic nerves that innervate the smooth muscle of the bronchial tree, pulmonary vessels, and glands of the bronchial tree.
- Parasympathetic fibers are bronchoconstrictors, vasodilators, and secretomotor to the glands.
- Visceral afferent fibers carry information involved in cough reflexes, stretch reception, blood pressure, chemoreception, and nociception



[Plate 196, Trachea and Major Bronchi]

FACTS & HINTS

High-Yield Facts

Clinical Points

- Diseases such as tuberculosis and sarcoidosis and lymphoma cause hilar lymphadenopathy that is visible in chest radiographs.
- Pneumonia: a bacterial or viral infection of the lung that can lead to widespread systemic infection and lung collapse. Pneumonia is frequently confined to a single lobe of one lung and is called lobar pneumonia. It can be clearly seen circumscribed to one lobe in a chest radiograph.
- The entry of air into a pleural cavity because of a penetrating wound or a fractured rib is called a pneumothorax and results in partial or total collapse of the lung.
- The escape of fluid into the pleural cavity (pleural effusion) is called hydrothorax; if the fluid is blood, the condition is known as a hemothorax, and if it is chyle from the thoracic duct, it is called a chylothorax.
- Inflammation of the pleurae is called pleuritis or pleurisy; resulting friction between the two pleurae (pleural rub) is very painful and can be heard with a stethoscope.
- The inflamed pleurae may adhere to each other (pleural adhesion)
- Squamous cell or oat cell carcinoma is a common cancer of the lung, usually caused by smoking, that may be indicated by a persistent cough or spitting of blood (hemoptysis).

page 108
page 109

Mnemonics

Memory Aids

Let's play the violin: L = lung pleura, P = parietal V = visceral

3 Ps: Parietal Pleura innervated by the Phrenic nerve

Victor has no sensation: Visceral pleura has no sensory innervation

Causes of Hilar Lymphadenopathy: Tell Some Lies: Tuberculosis, Sarcoidosis, Lymphoma

Bronchopulmonary segments: Apes And Possums Might Light LAMPS: (Upper lobe: Apical, Anterior, Posterior; Middle lobe: Medial and Lateral; Lower lobe: Lateral, Anterior, Medial, Posterior, Superior)

22 Heart

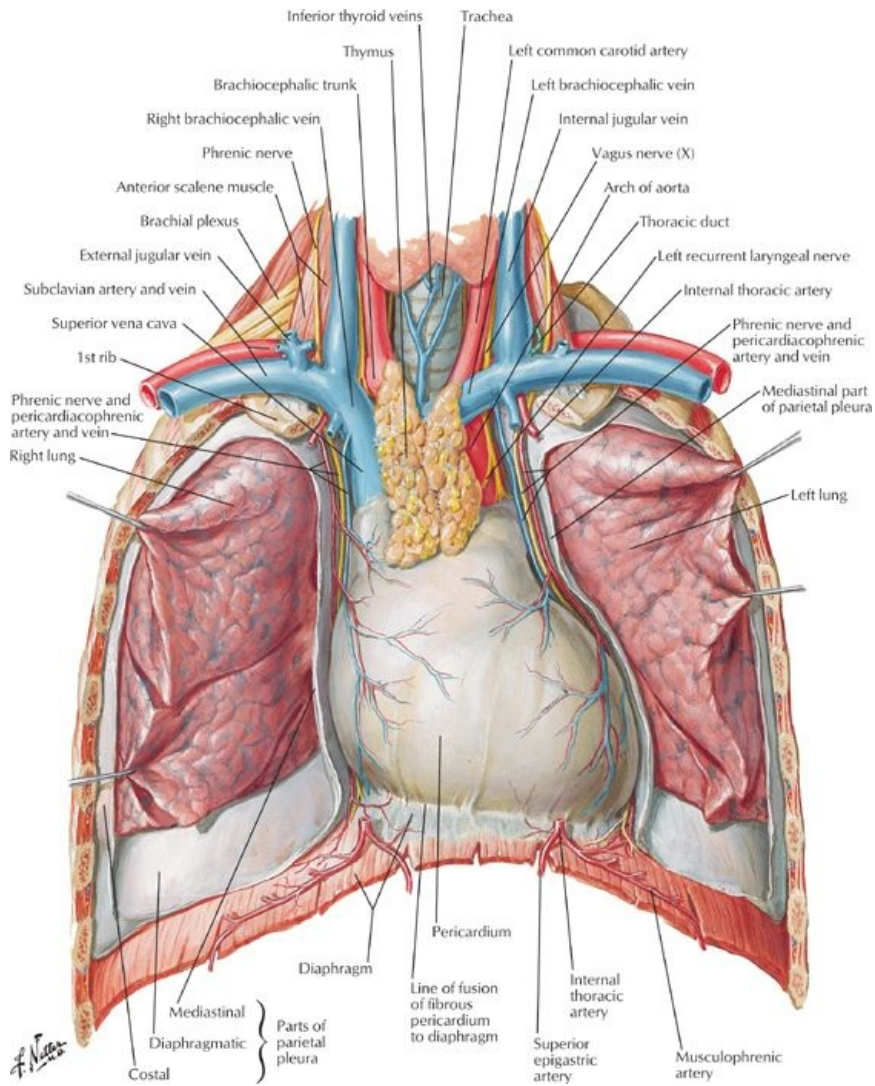
STUDY AIMS

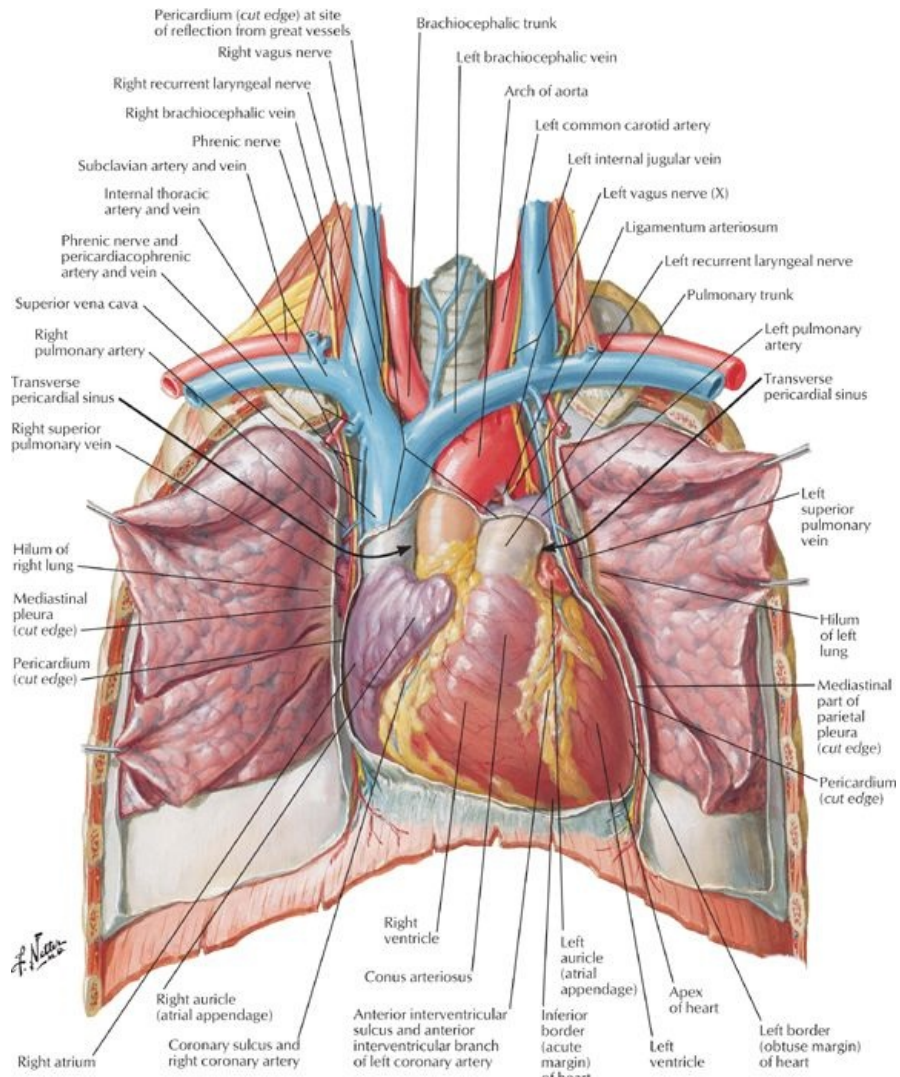
At the end of your study, you should be able to:

- Identify the pericardium and its relationships
- Know the layers of the pericardium
- Understand the surface projection of the heart and its chambers
- Know the internal features of the atria and ventricles
- Understand coronary circulation
- Know the innervation and conduction system of the heart

GUIDES

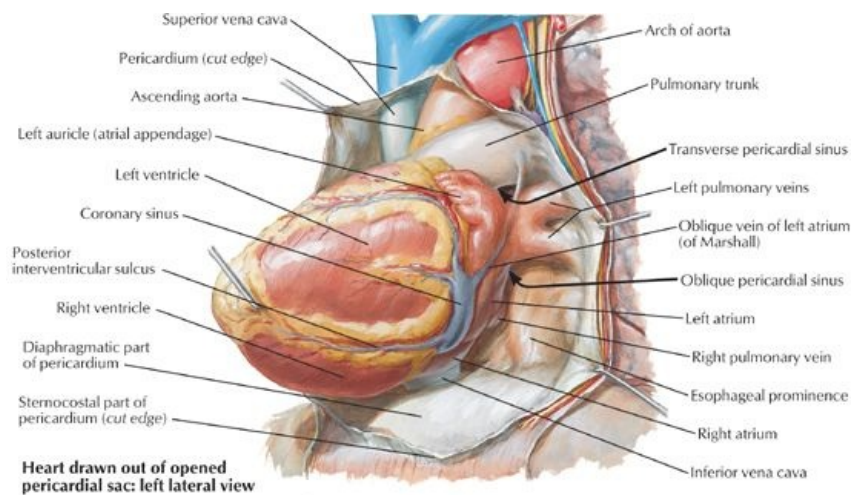
Thorax: Heart



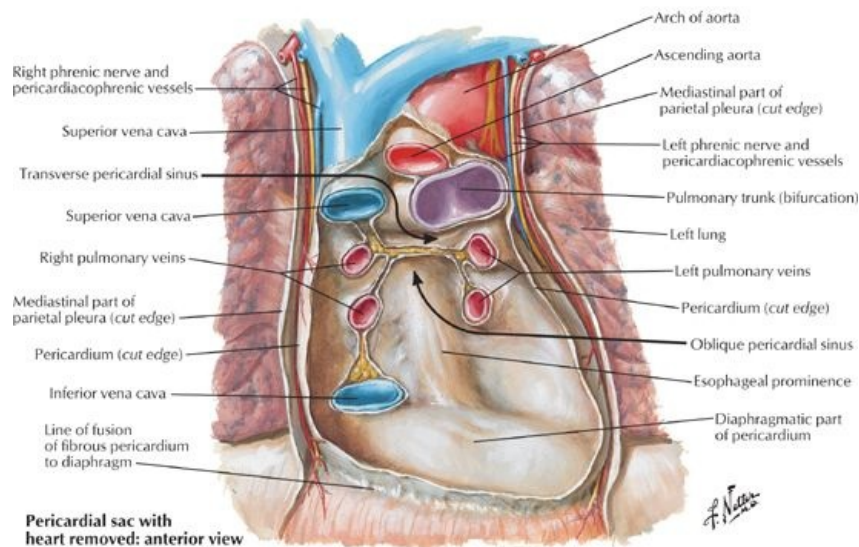


[Plate 206, Heart: Anterior Exposure]

Pericardium



Heart drawn out of opened pericardial sac: left lateral view



Pericardial sac with heart removed: anterior view

[Plate 209, Pericardial Sac]

- The pericardium is a double-layered sac that encloses the heart and the roots of the great vessels.
- The fibrous outer layer of the pericardium (the fibrous pericardium) consists of dense connective tissue.
- The fibrous pericardium is attached to the central tendon of the diaphragm by the pericardiophrenic ligament.
 - It blends with the tunica adventitia of the vessels entering and leaving the heart.
 - It has ligamentous attachments to the sternum
 - It is thus affected by movements of the heart, the great vessels, the sternum, and the diaphragm.
 - It protects the heart against overfilling because it is fibrous and unyielding
- The inner layer of the pericardium is a serous membrane that lines the fibrous pericardium: the serous pericardium, also called the parietal pericardium.
- The serous pericardium is a mesothelial layer that reflects onto the roots of the great vessels and is continuous over the external surface of the heart, where it is called the epicardium or visceral pericardium.
- Between the serous pericardium (parietal pericardium) and the epicardium (visceral pericardium) is a potential space: the pericardial cavity.
- The pericardial cavity normally contains a thin film of fluid that allows the two layers to move over each other without friction or rubbing.
- There are two sinuses within the pericardial cavity: the transverse sinus and the oblique sinus.
 - The transverse pericardial sinus runs transversely in the pericardial sac between the origins of the great vessels: posterior to the ascending aorta and pulmonary trunk and anterior to the superior vena cava.
 - The oblique pericardial sinus is a wide recess in the posterior wall of the pericardial sac bounded laterally by the entrances of the pulmonary veins and inferiorly by the orifice of the inferior vena cava.
- Blood supply to the layers of the pericardium is mainly from the pericardiophrenic vessels, from the internal thoracic arteries and veins.
- The nerve supply to the pericardium is from the phrenic nerves, primarily sensory fibers for pain, and the sympathetic trunks (vasomotor).

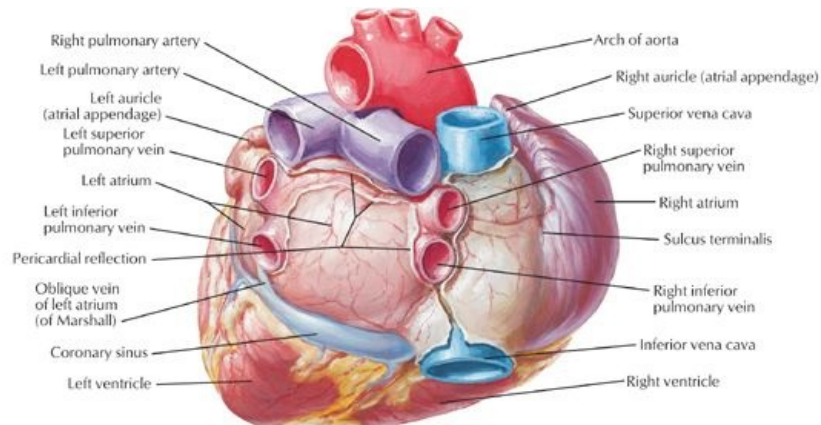
page 110
page 111

Heart

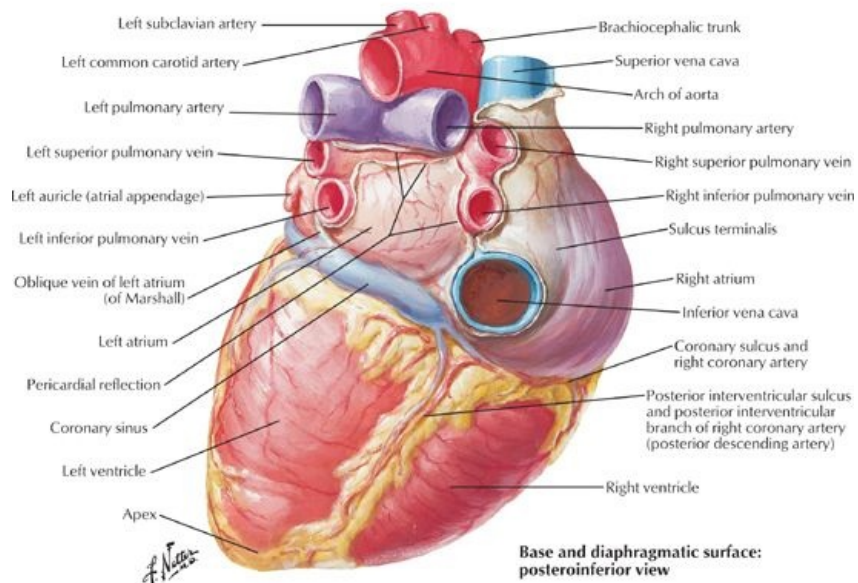
- The heart is a muscular pump for the propulsion of blood to all parts of the body.
- The right side of the heart receives poorly oxygenated blood from the superior and inferior vena cava and pumps it to the lungs for oxygenation.
- The left side of the heart receives oxygenated blood from the lungs via the pulmonary veins and pumps it to the body via the aorta and its branches.
- The heart consists of four chambers: the right and left atria and the right and left ventricles.
- The chambers of the heart have walls that consist of three layers:

- Endocardium: internal layer of endothelium and connective tissue
- Myocardium: the middle, thick muscular layer of the heart
- Epicardium, or visceral pericardium
- The fibrous skeleton of the heart is a framework of dense collagen that encircles the orifices of the four valves (pulmonary, aortic, tricuspid and mitral).
- The functions of the fibrous skeleton are:
 - Maintains the patency of the atrioventricular valves
 - Provides a fixed site for the attachment of the leaflets and cusps of the valves
 - Provides a fixed site for the attachments of the cardiac muscle fibers
 - Insulates the atria from the ventricles so that they can contract independently
- The cardiac cycle consists of
 - Relaxation of the ventricles (diastole) followed by
 - Contraction of the ventricles (diastole)
- Heart sounds heard with a stethoscope:
 - "lub"-blood from the atria fills the ventricles
 - "dub"-ventricles contract and push blood out of the heart

Orientation of the Heart: Border and Surfaces



Base of heart: posterior view



Base and diaphragmatic surface: posteroinferior view

[Plate 208, Heart: Base and Diaphragmatic Surfaces]

- The heart lies obliquely between the 3rd and the 5th ribs, mainly on the left side of the midline of the thorax, but with roughly a third of it slightly to the right.
- The base of the heart is its posterior surface, which is the left atrium.
- The apex of the heart is formed from the most inferior and lateral part of the left ventricle and lies beneath the left 5th intercostal space at approximately the midclavicular line.

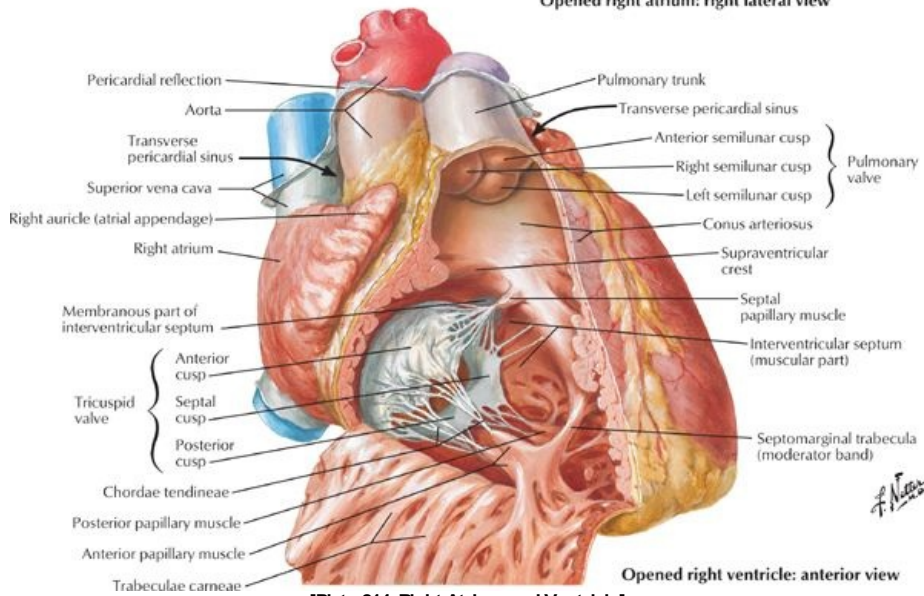
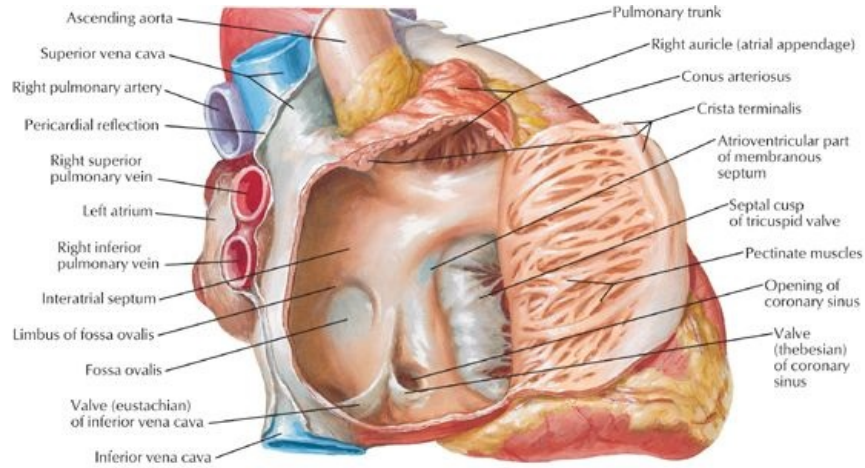
Borders

- Right border: the right atrium between the superior and inferior vena cavae
- Left border: left auricle and left ventricle
- Inferior border: mainly right ventricle with some contribution from the left ventricle
- Superior border (anterior view): right and left atria and their auricles

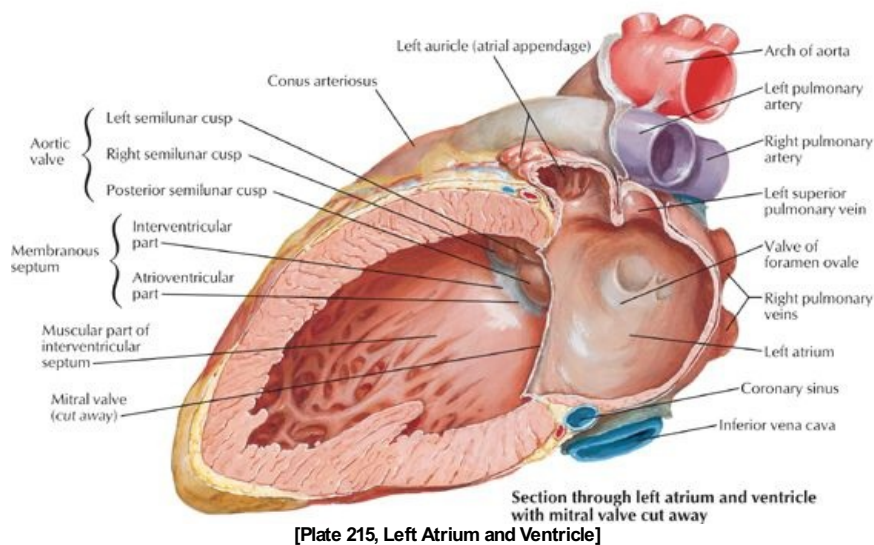
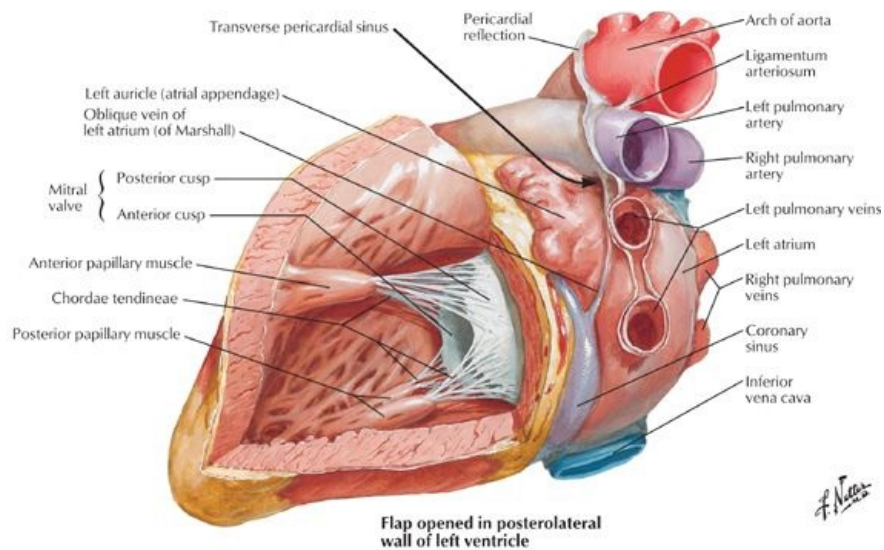
Surfaces (in normal anatomic position)

- Anterior (sternocostal): right ventricle
- Diaphragmatic (inferior): mainly by the left ventricle with some contribution by the right ventricle
- Pulmonary surface (left, filling the cardiac impression in the left lung): left ventricle

Chambers of the Heart



[Plate 214, Right Atrium and Ventricle]



page 111
page 112

Right atrium

- The posterior wall of the right atrium is smooth (sinus venarum) and contains the orifices of the superior vena cava and coronary sinus.
- The anterior wall is ridged with the pectinate muscles.
- The smooth and rough parts of the right atrium are separated internally by a smooth ridge, the crista terminalis, which presents externally as shallow groove, the sulcus terminalis.
- The superior vena cava opens into the superior aspect of the right atrium.
- The inferior vena cava opens into the inferior part, in a direct line with the superior vena cava.
- An interatrial septum separates the right and left atria.
- An oval depression in the interatrial septum, the fossa ovalis, represents the fetal foramen ovale and its valve.
- Aright atrioventricular (AV) orifice opens into the right ventricle

Right ventricle

- The right ventricle is situated in front and to the left of the right AV orifice.
- The interior has prominent muscular ridges, the trabeculae carneae.
- The tricuspid valve or right AV valve usually consists of three leaflets.
 - The bases of the leaflets or cusps are attached to the fibrous ring around the orifice.
 - The free edge of each leaflet is attached to two of the three papillary muscles by tendinous cords (chordae tendineae).
- The papillary muscles are three in number: septal, anterior and posterior.
- These muscles contract before the ventricle itself contracts, tightening the chordae tendineae and drawing the cusps of the valve together to prevent backflow of blood into the right atrium.
- The septomarginal trabecula, or moderator band, is a free band of muscle extending from the interventricular septum to the anterior wall of the ventricle, and it contains Purkinje fibers from the right bundle branch (see conducting system).
- The outflow tract of the ventricle is separated from the inflow tract by a smooth crest, the supraventricular crest.
- The outflow tract, or conus arteriosus, is smooth walled and leads to the pulmonary trunk and the valve that guards its orifice, the pulmonary valve.
- The pulmonary valve has three cusps, which open like pockets to catch regurgitated blood during ventricular diastole

Left Atrium

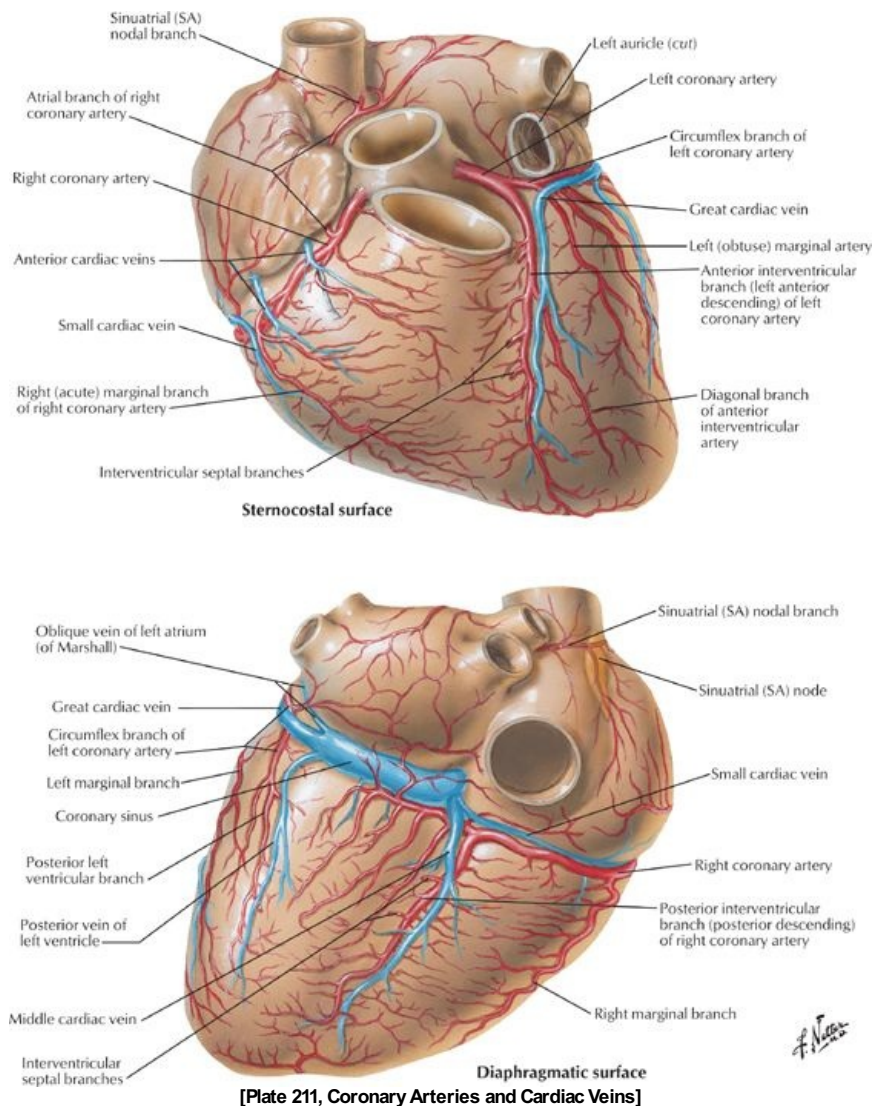
- The left atrium forms the base of the heart.
- It has a smooth walled portion from the developmental incorporation of a portion of the pulmonary veins and an auricular appendage which is ridged with pectinate muscles and which was the primitive left atrium.
- Four pulmonary veins empty into the left atrium.
- The interatrial septum is nearly transverse, sloping posteriorly and to the right
- The left atrioventricular orifice leads to the left ventricle.

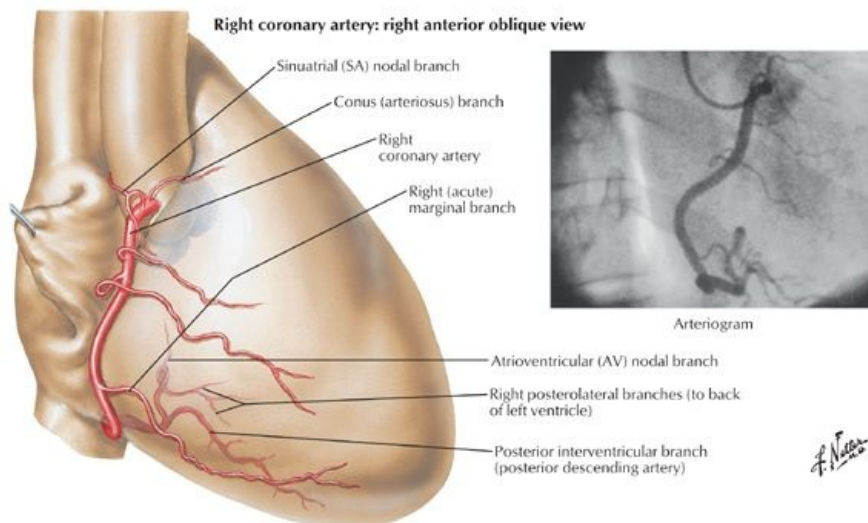
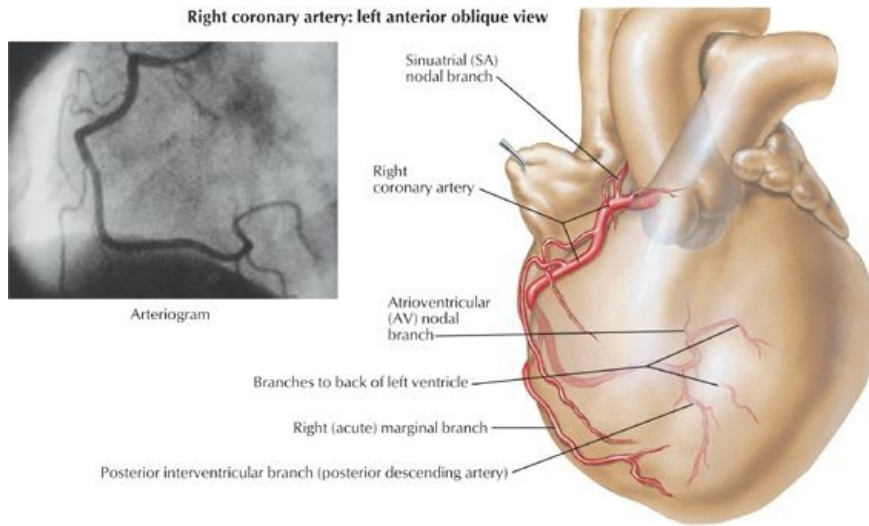
Left Ventricle

page 112
page 113

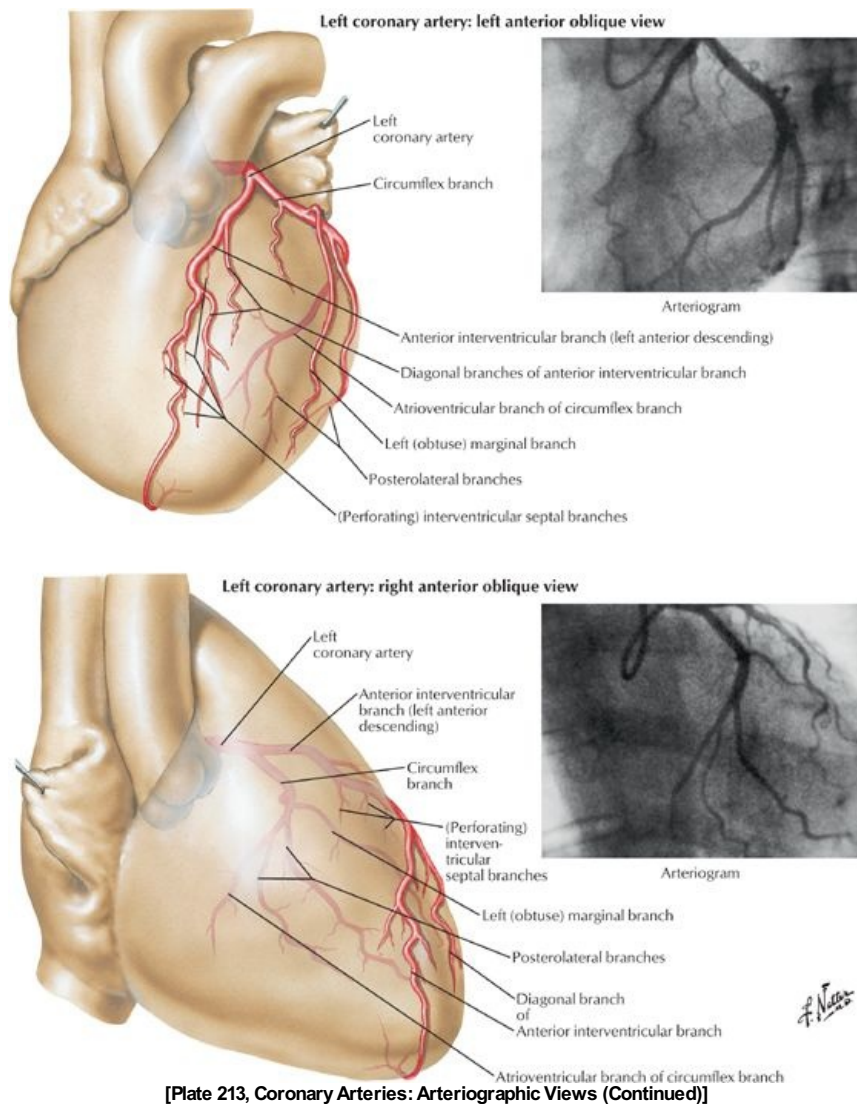
- The left ventricle is nearly twice as thick as the right ventricle, since it performs more work to circulate blood to the body.
- It has a conical cavity, the apex of which is the apex of the heart.
- Its walls are lined with trabeculae carneae, which are more numerous and not as massive as the ones in the right ventricle.
- It contains only two papillary muscles, anterior and posterior, which both attach to the two leaflets of the left atrioventricular, or mitral, valve via chordae tendineae.
- These muscles contract before the ventricle itself contracts, tightening the chordae tendineae and drawing the cusps of the valve together to prevent backflow of blood into the left atrium.
- The aortic orifice is located posteriorly and superiorly and, like the pulmonary orifice, is surrounded by a fibrous ring to which the three cusps of the aortic valve are attached.
- The aortic valve has three cusps, which open like pockets to catch blood that backflows from the aorta during ventricular diastole.
- There are dilations in the wall of the aorta beneath each cusp: the aortic sinuses.
- The right coronary artery originates in the right aortic sinus, while the left coronary artery originates in the left aortic sinus.

Coronary Circulation





[Plate 212, Coronary Arteries: Arteriographic Views]



[Plate 213, Coronary Arteries: Arteriographic Views (Continued)]

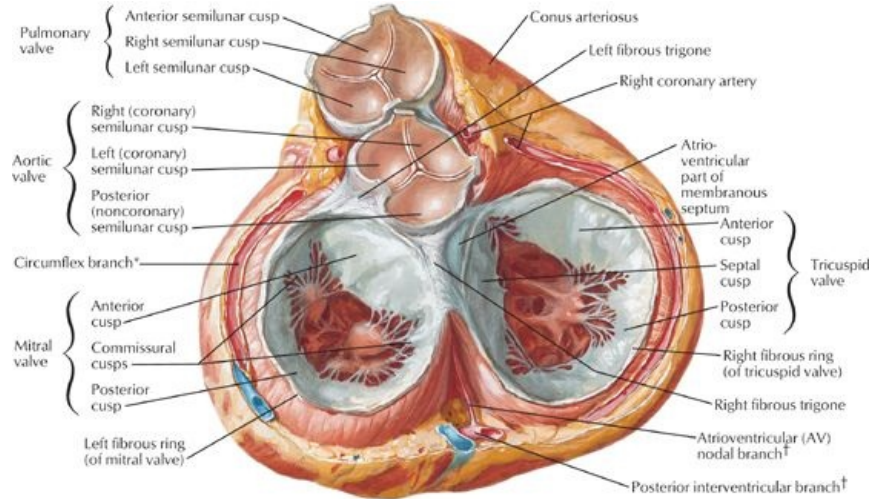
Arteries

- The arterial supply to the heart is the right and left coronary arteries, the first branches of the aorta.
- They arise from the corresponding aortic sinuses, just distal to the origin of the aortic valve.
- The left coronary artery passes between the left auricle and the pulmonary trunk. Its main branches are
 - A circumflex branch, which reaches the posterior surface of the heart by traveling in the atrioventricular groove around the left side of the heart
 - In slightly less than half of all people, a sinoatrial (SA) nodal branch from the circumflex branch will supply the SA node.
 - An anterior interventricular branch (left anterior descending artery or LAD), which descends in the anterior interventricular groove to the apex of the heart and then anastomoses with the posterior interventricular artery.
- The right coronary artery runs in the atrioventricular groove to the right and around to the posterior surface of the heart. It gives rise to
 - The SA nodal branch near its origin (in most people)
 - A right marginal branch to the right margin of the heart
 - An AV nodal branch to the atrioventricular node, at the junction of the septa and four chambers of the heart on the posterior side of the heart
 - A posterior interventricular branch that runs in the posterior interventricular groove.
- The left coronary artery supplies
 - Left atrium
 - Most of left ventricle
 - Some of the right ventricle
 - Interventricular septum
 - SA node (40% of people)
- The right coronary artery supplies
 - Right atrium
 - Most of right ventricle
 - Diaphragmatic surface of left ventricle
 - Some of the interatrial and interventricular septa
 - SA node (60% of people)
 - AV node

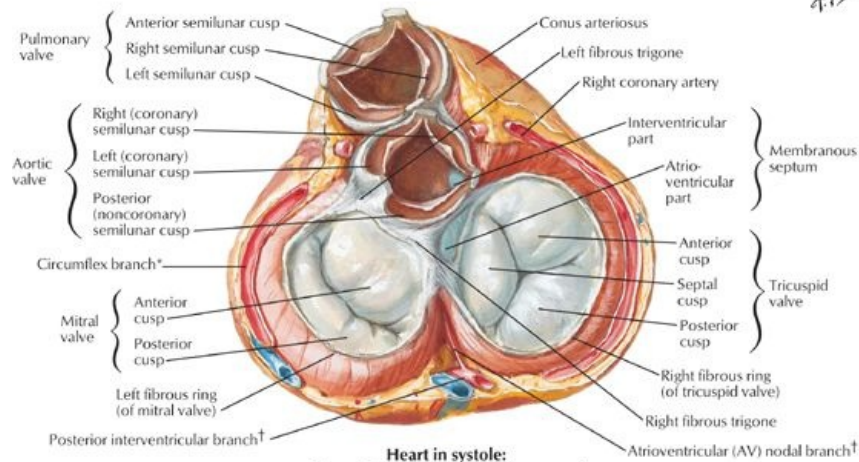
Veins

- The coronary sinus is a wide vein that runs transversely across the posterior surface of the heart in the coronary groove.
- The coronary sinus receives blood from
 - The great cardiac vein that ascends in the anterior interventricular groove and enters the coronary sinus at its left end
 - The middle cardiac vein (posterior interventricular vein) that ascends in the posterior interventricular groove and enters the coronary sinus at its right end
 - Small cardiac veins
 - Left marginal vein
 - Left posterior ventricular vein(s)
- Anterior cardiac veins that enter the right atrium directly
- Venae cordis minimae (smallest cardiac veins) that open directly into the chambers of the heart

Innervation and Conducting System of the Heart



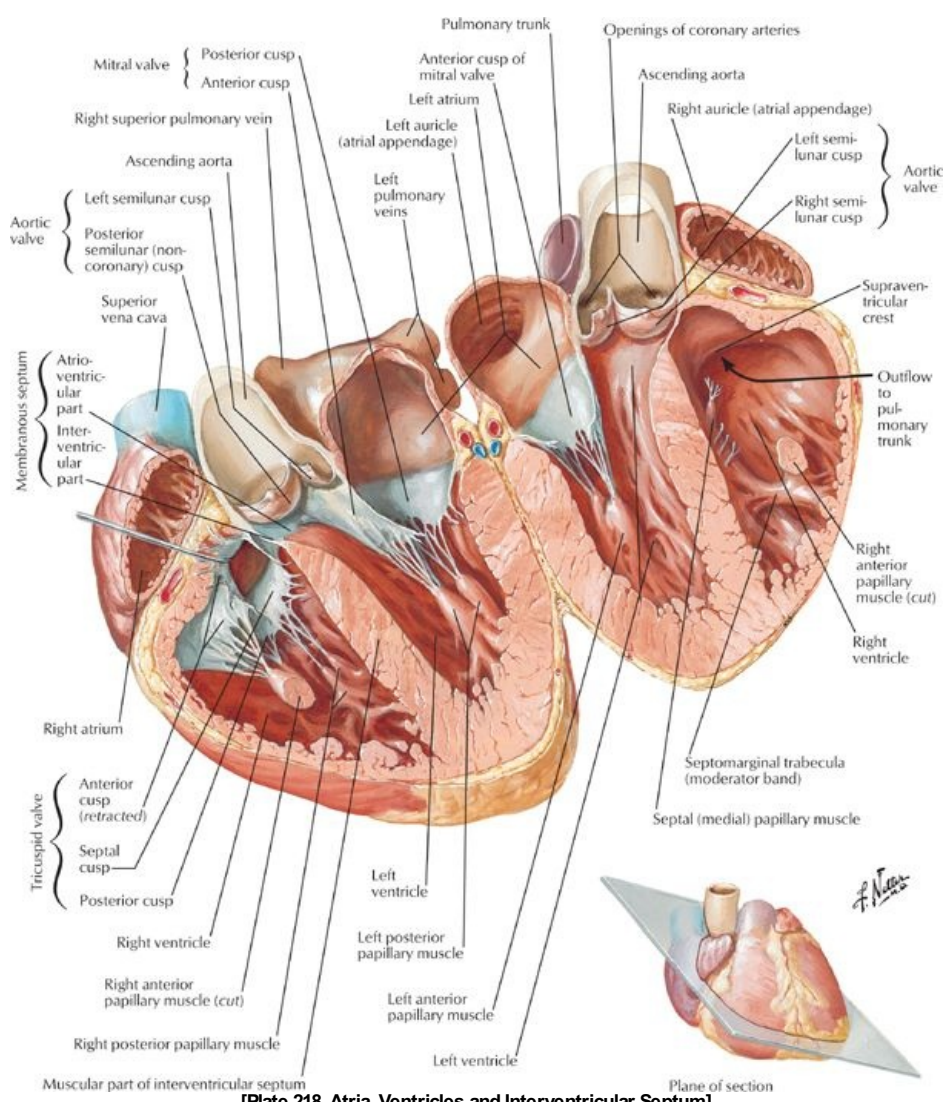
**Heart in diastole:
viewed from base with atria removed**



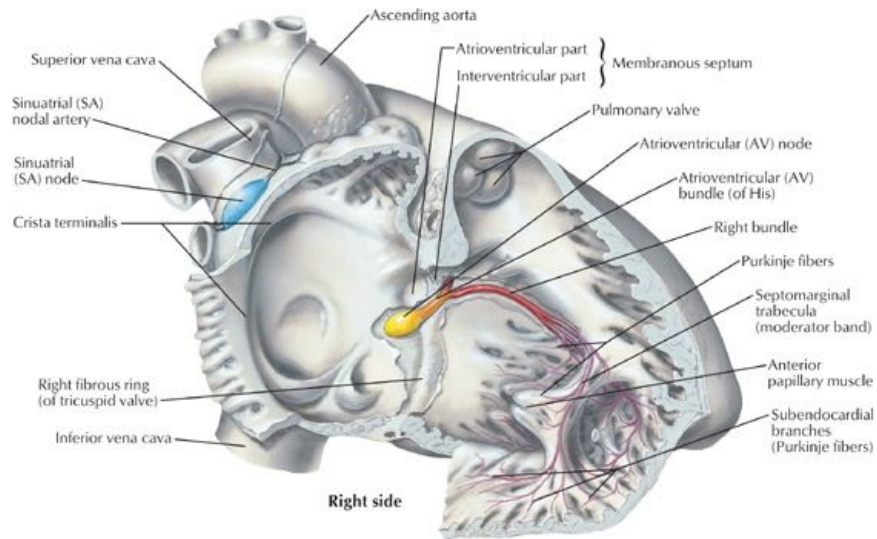
**Heart in systole:
viewed from base with atria removed**

*Of left coronary artery
†Of right coronary artery

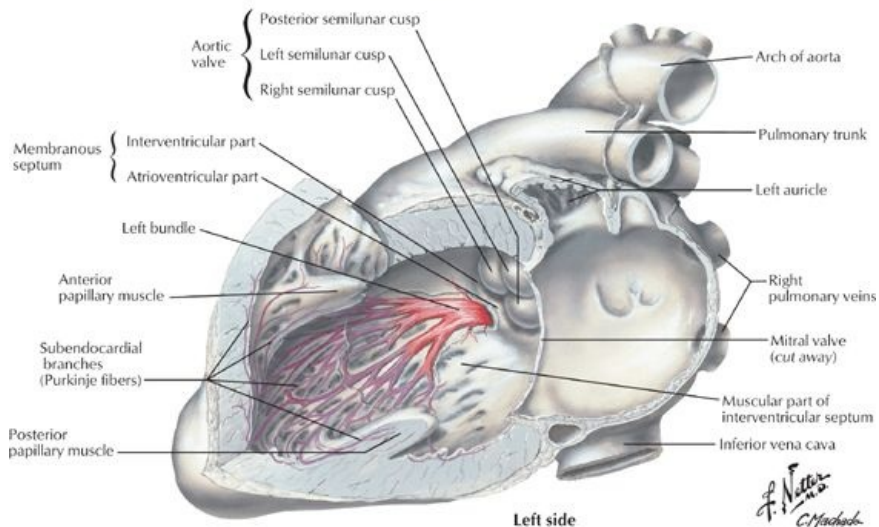
[Plate 216, Valves and Fibrous Skeleton of Heart]



[Plate 218, Atria, Ventricles and Interventricular Septum]



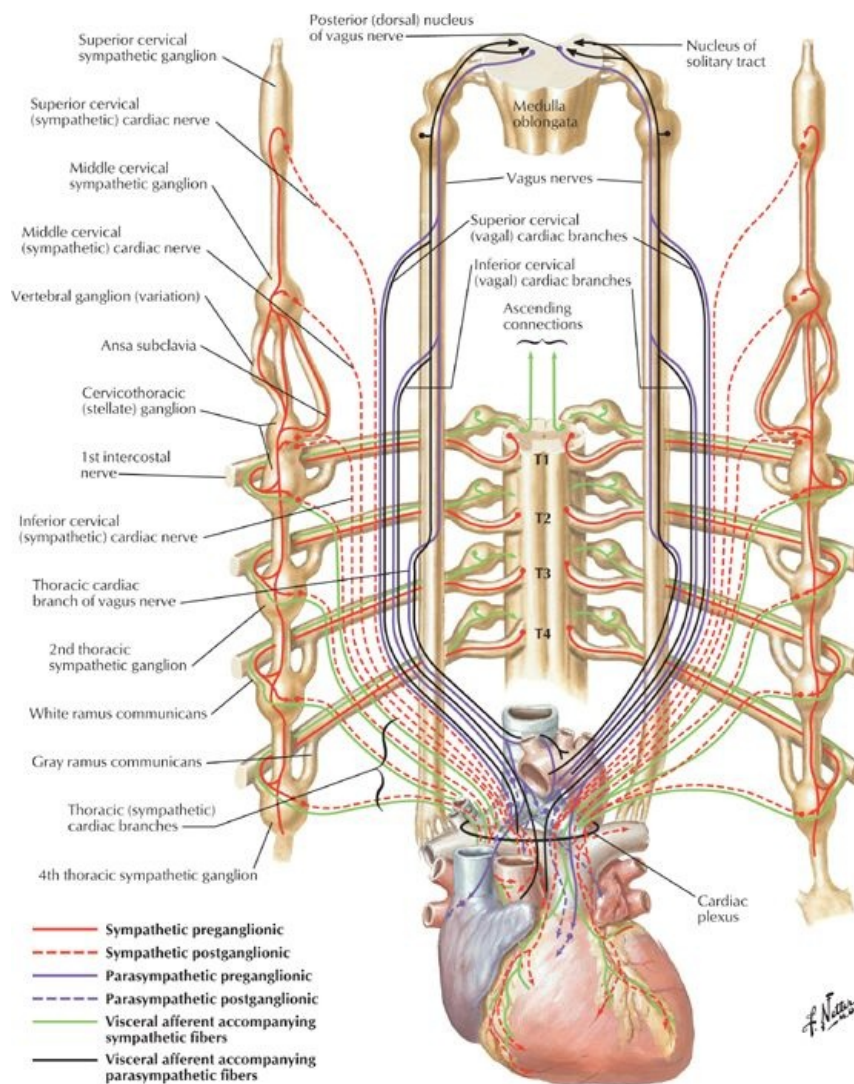
Right side



Left side

[Plate 219, Conducting System of Heart]

*F. Netter
C. Machado
M.D.*



[Plate 221, Innervation of Heart: Schema]

- Both divisions of the autonomic nervous system provide fibers to the cardiac plexus
- The conducting system of the heart coordinates the cardiac cycle of contraction. It consists of
 - The sinoatrial node (SANode), located at the superior end of the sulcus terminalis of the right atrium, near the entrance of the superior vena cava
 - The SANode is the so-called pacemaker of the heart, from which impulses for contraction are initiated and spread through the musculature of both atria.
- Fibers from the cardiac plexus supply the SANode.
 - Sympathetic innervation accelerates the rate and force of contraction of heart muscle.
 - Parasympathetic stimulation slows down the rate and force of contraction of heart muscle.
- Signal from the SANode is propagated by the cardiac muscle to the AV node.
- The AV node is located near the inferior end of the interatrial septum posteriorly, near the septal cusp of the tricuspid valve.
- The AV bundle carries the signal from the AV node through the fibrous skeleton of the heart and the membranous interventricular septum.
 - It divides into right and left bundles that pass on either side of the muscular interventricular septum.
 - The fibers of the right and left bundles (Purkinje fibers) spread into the walls and papillary muscles of the ventricles.
 - Purkinje fibers from the right bundle innervate the anterior papillary muscle of the right ventricle via the septomarginal trabecula or moderator band, to coordinate the timing of the contraction of the papillary muscles.

Heart Sounds

- Clinicians need to listen to valve sounds.
- Blood carries sound in the direction of its flow, so valve sounds are best heard (auscultated) directly superficial to their location or at the end of a line of blood flow through the valve.

FACTS & HINTS

High-Yield Facts

Clinical Points

page 115
page 116
page 116
page 117

Cardiac Tamponade

- Inflammation of the pericardium (pericarditis) can result in pericardial effusion, a leakage of fluid from the pericardial capillaries into the pericardial cavity.
- Similarly, stab wounds to the heart can result in the leakage of blood into the pericardial cavity.
- As excess blood or fluid accumulates in the pericardial cavity, the heart becomes increasingly inhibited from expanding as it beats, and blood flow to the ventricles is impeded.
- This situation is called cardiac tamponade and is a potentially lethal condition.
- Symptoms include distension of neck veins and a collapsing pulse, i.e., diastolic and systolic pressures become the same.

Pericardiocentesis

- Pericardiocentesis or drainage of fluid from the pericardial cavity is necessary to relieve cardiac tamponade.
- A wide bore needle is inserted into the 5th or 6th intercostal space adjacent to the sternum (but not too close because of the presence of the internal thoracic vessels).
- This approach can be made because of the cardiac notch in the left lung and left parietal pleura, leaving the pericardial sac exposed.
- A needle can also be inserted into the infrasternal angle, again being careful of the internal thoracic artery and its branches, and passed superiorly and posteriorly to reach the pericardial sac.

Cardiac Referred Pain

- While the heart is generally insensitive to various stimuli, ischemia (lack of oxygen) and the resulting accumulation of metabolic products registers as pain, typically in the left pectoral and substernal regions and over the medial aspect of the left shoulder and upper limb.
- The axons of visceral afferent fibers from the heart typically enter spinal cord segments from T1 through T4 or 5 on the left side.
- General sensory fibers from these areas also enter the same spinal cord segments

Cardiac Bypass Graft (CABG)

- In this surgery, the patient has a blood vessel grafted into the coronary circulation to bypass an occlusion in one of the coronary arteries or its branches.
- In the past, the saphenous vein was commonly used in the bypass graft, because it is easily obtained from the lower limb and has lengthy sections without valves or branches.
- The internal thoracic artery is more frequently used to shunt blood from the aorta to branches of the coronary arteries beyond the occlusion.
- This restores normal blood flow to the part of the heart distal to the blockage.

Ventricular Septal Defects (VSDs)

- The membranous part of the interventricular septum is the most common site of ventricular septal defects (VSDs).
- VSDs account for 25% of all cardiac abnormalities.
- It can be a result of any one of several developmental anomalies, such as failure of the embryonic endocardial cushions, which form part of the septum, to fuse.
- A left to right flow of blood occurs with this defect because of the strength of contraction of the left ventricle.
- This increases the blood flow through the pulmonary trunk to the lungs and results in pulmonary hypertension (increased blood pressure) and an enlarged heart.
- This condition is potentially fatal if not corrected.

Pathologies of the Aorta

- Aneurysms of the ascending aorta
- An aortic aneurysm is an enlargement of a weakened area of the aorta, in this case in the distal part of the ascending aorta.
 - Aneurysms are prone to rupture once they reach a certain size and 50% of patients who experience a rupture of a thoracic aortic aneurysm die before reaching the hospital.
 - Ascending aortic aneurysms frequently cause dilation and leakage of the aortic valve, resulting in shortness of breath or even heart failure.
 - They can also cause a dull pain beneath the sternum and/or pain radiating to the upper back.
- Aortic dissection is a tearing of the internal wall of the aorta, with subsequent bleeding into the wall, as the result of an aneurysm, atherosclerosis, or high blood pressure.
- Coarctation of aorta is a birth defect in which the aorta is narrowed somewhere along its length, most commonly just past the point where the subclavian artery arises.
 - This results in low blood pressure in branches of the aorta distal to the narrowing and high blood pressure in branches between the narrowing and the heart.
 - People with this condition often have high blood pressure in the upper body and arms (or one arm) and low blood pressure in the lower body and legs.
 - The intercostal arteries can become enlarged, since the anastomoses of the anterior intercostals (from the internal thoracic artery) with the posterior intercostals can circumvent the narrowing.
 - Aortic coarctation is more common in some genetic conditions such as Turner syndrome but also can be associated with congenital abnormalities of the aortic valve such as a bicuspid aortic valve.

Valvular Insufficiencies

- The mitral valve is the heart valve most frequently affected by disease.
 - It can be caused by endocarditis, myocarditis, rheumatic heart disease, or lupus erythematosus, or can result from a developmental abnormality.
 - The diseased mitral valve allows reversal of blood flow from the left ventricle to the left atrium (mitral regurgitation).
 - It is characterized by a high pitched murmur, loudest over the apex of the heart.
- Narrowing of the pulmonary valve (stenosis) is caused by fusion of the valve cusps.
 - It can result from a developmental abnormality or diseases such as rheumatic fever or endocarditis.

-
- Stenosis of the pulmonary valve leads to right ventricular hypertrophy and heart failure, if not corrected surgically.

Mnemonics

Memory Aids

PV2L: Pulmonary valve heard over 2nd left intercostal space

AV2R: Aortic valve heard over 2nd right intercostal space

Memory Aids

To remember the cusps of the aortic and pulmonary valves: **A = P** and **P = A**

A(ortic) = **P**osterior, **R**ight and **L**eft

P(ulmonary) = **A**nterior, **R**ight and **L**eft

23 Mediastinum

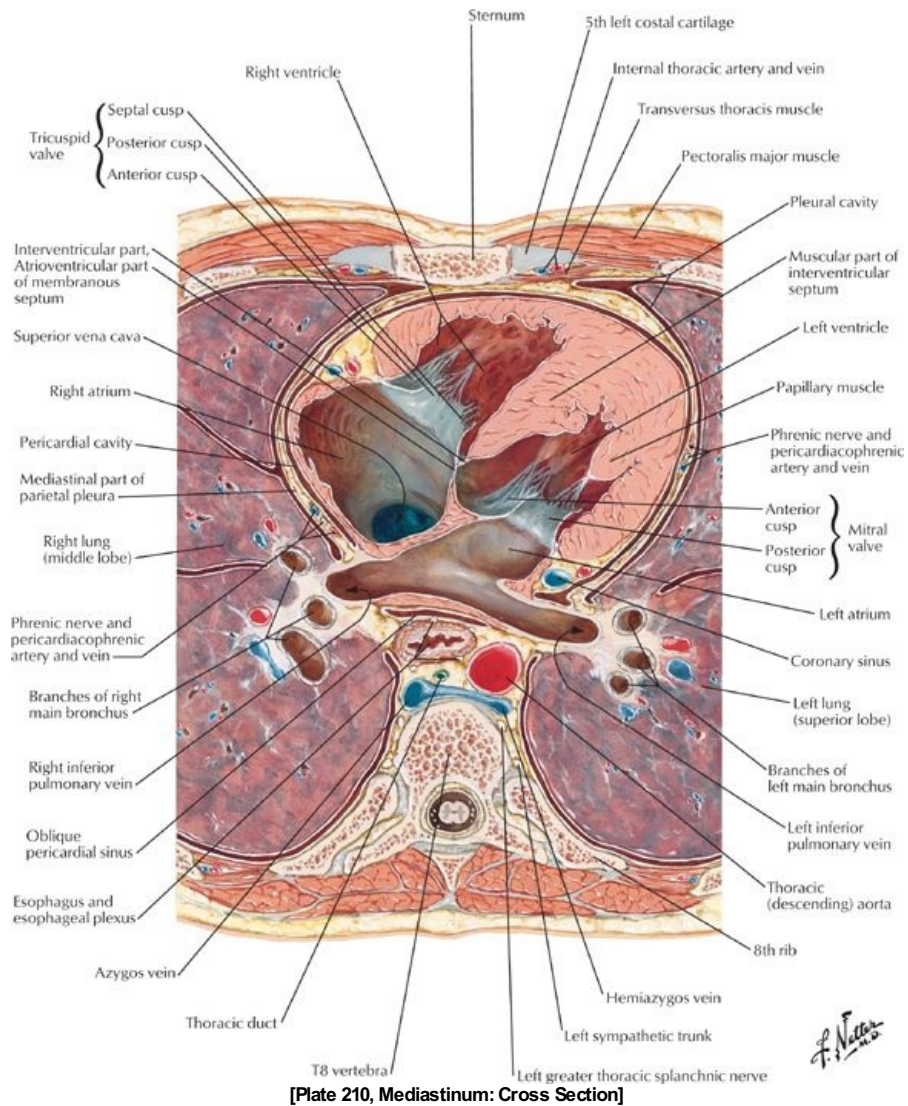
STUDY AIMS

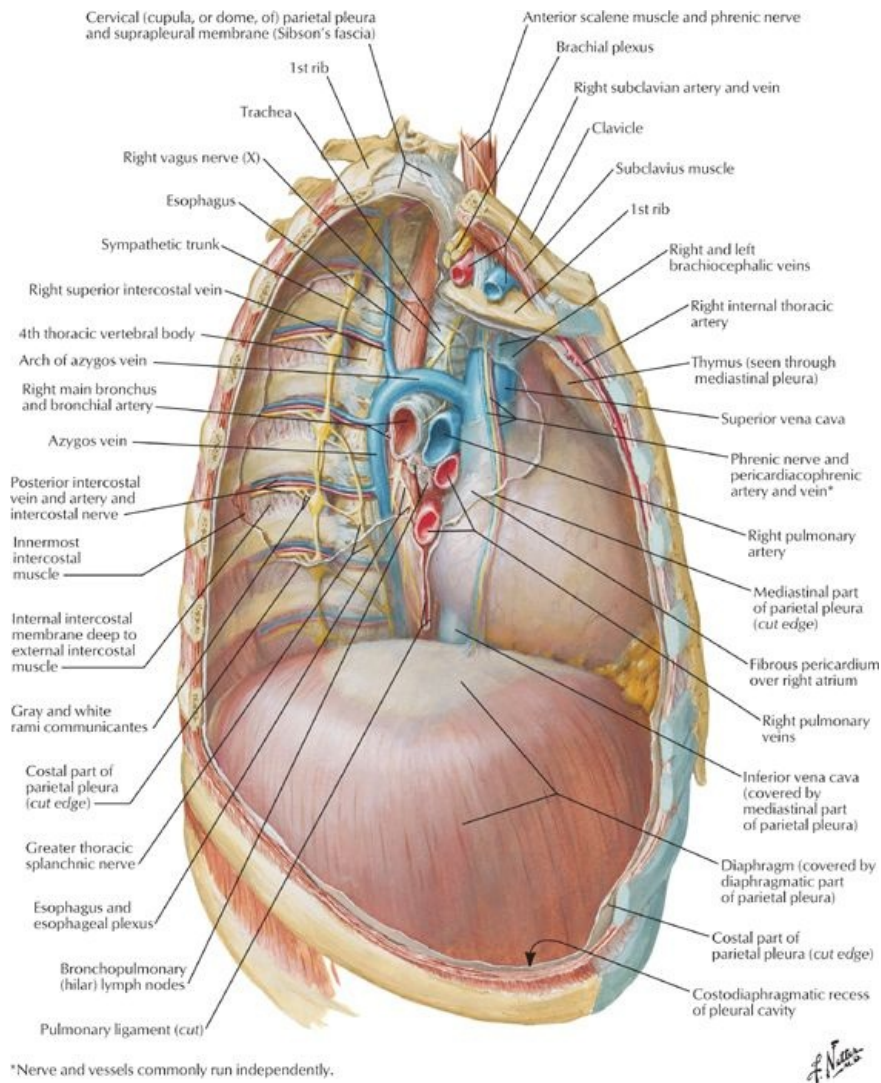
At the end of your study, you should be able to:

- Identify the mediastinum
- Identify the major arteries and veins of the mediastinum
- Identify the trachea
- Identify the esophagus

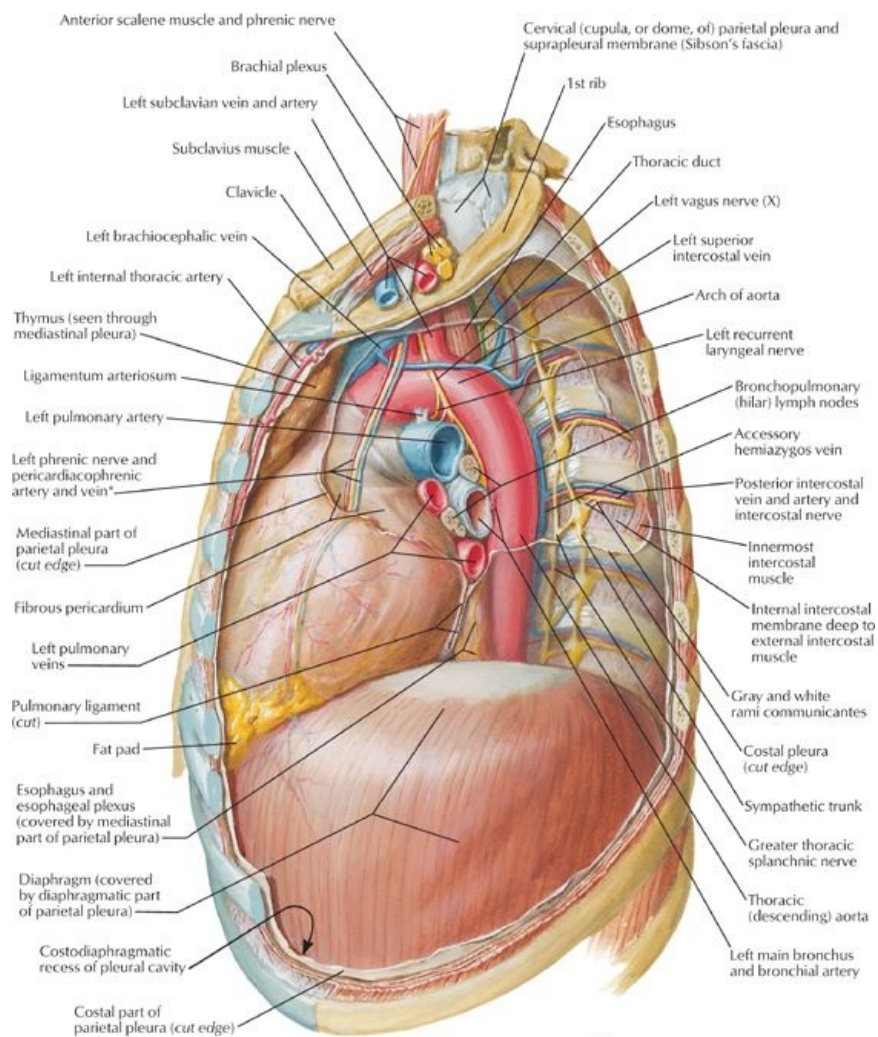
GUIDES

Thorax: Mediastinum





[Plate 224, Mediastinum: Right Lateral View]



*Nerve and vessels commonly run independently.

[Plate 225, Mediastinum: Left Lateral View]

General Description

page 118
page 119
page 119
page 120
page 120
page 121

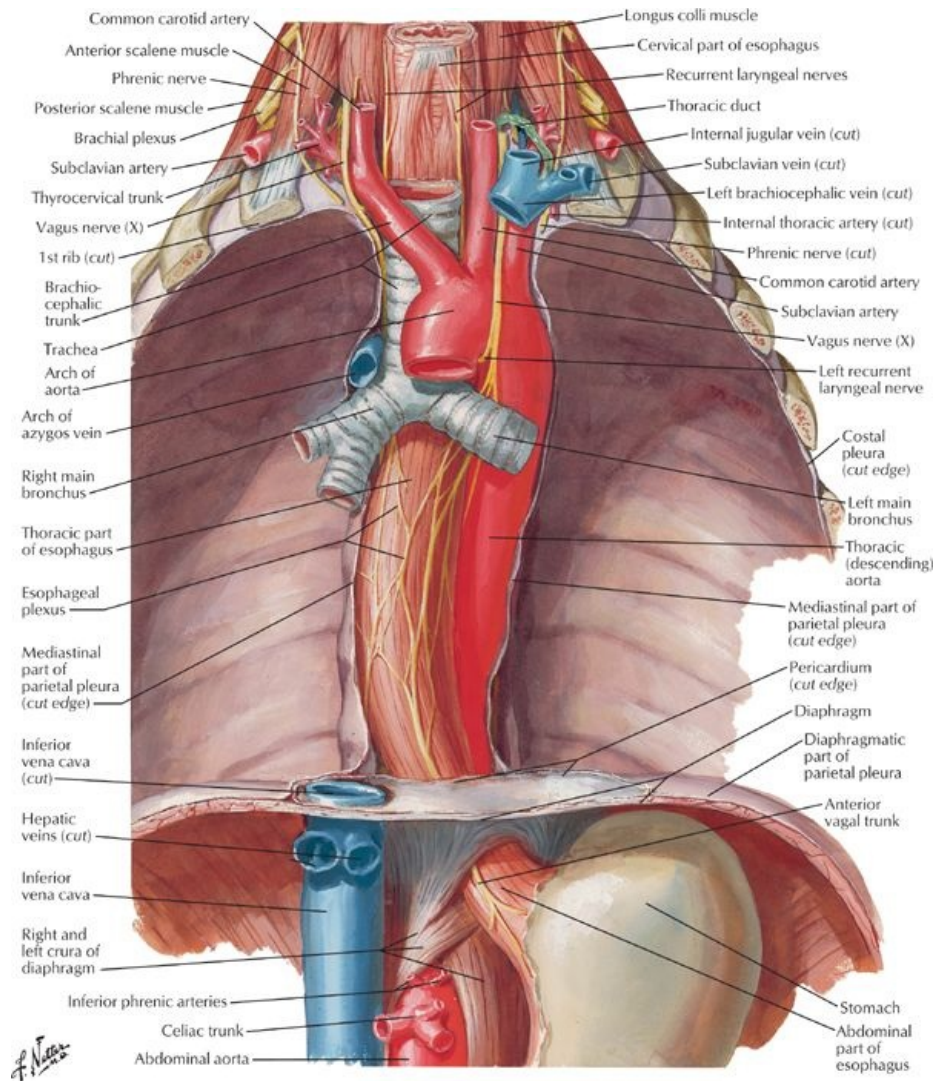
- The mediastinum is the central compartment of the thorax between the two pleural cavities.
- Stretches from the thoracic inlet to the diaphragm and from the sternum to the bodies of the thoracic vertebrae posteriorly.
- Its contents include the heart, trachea, esophagus, great vessels of the heart, lymph nodes, nerves, and fat.
- The mediastinum is divided into two parts:
 - The superior part extends from the thoracic inlet to a plane at the level of the sternal angle and the T4/5 intervertebral disc
 - The inferior mediastinum extends from this plane to the diaphragm.
- Superior mediastinum contains the
 - superior vena cava
 - arch of the aorta and its branches
 - trachea
 - phrenic nerves
 - thoracic duct
 - esophagus
 - vagus nerves
 - left recurrent laryngeal nerve
 - thymus
- Inferior mediastinum is subdivided into
 - anterior mediastinum
 - middle mediastinum
 - posterior mediastinum
- The anterior mediastinum contains fat and the remnants of the thymus gland
- The middle mediastinum contains the heart surrounded by the pericardium and the roots of the great vessels. The great vessels are:
 - ascending aorta
 - superior vena cava
 - pulmonary trunk
- The posterior mediastinum contains

- esophagus and the esophageal plexus
- descending aorta
- thoracic duct
- tracheobronchial lymph nodes
- azygos and hemiazygos veins
- thoracic sympathetic trunks
- thoracic splanchnic nerves

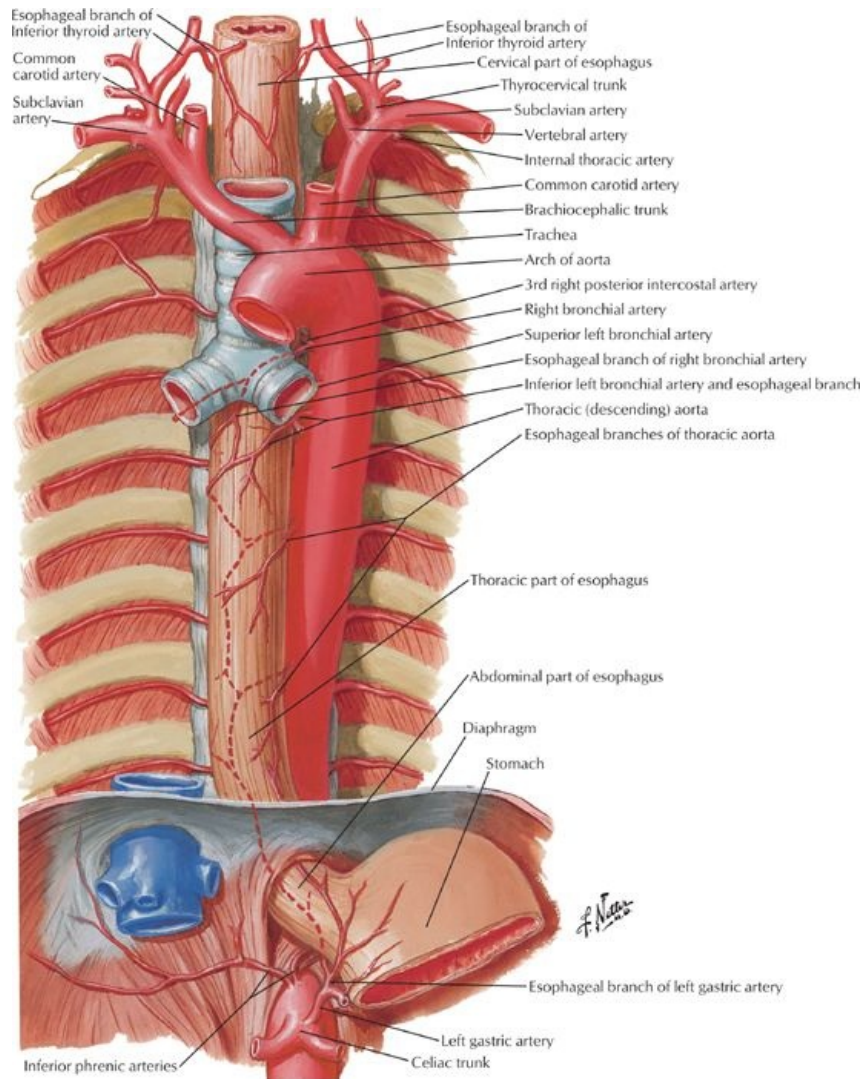
Structures in the Mediastinum

- Thymus gland
 - plays a central role in the development of the immune system
 - lies posterior to the manubrium
 - receives blood from the internal thoracic and anterior intercostal arteries
 - is gradually replaced by adipose tissue after puberty
- Heart and pericardial sac (*Section 3-5: Thorax-Heart*)
- Superior vena cava
 - Formed by the union of two brachiocephalic veins
 - Returns blood to the heart from all structures above the diaphragm except the heart and lungs
 - Descends vertically and terminates in the right atrium
 - Lies to the right of the ascending aorta and to the left of the right phrenic nerve
 - Receives azygos veins before piercing fibrous pericardium
- Brachiocephalic veins
 - Are formed in the root of the neck posterior to the sternoclavicular joints by union of the internal jugular and subclavian veins.
 - Right brachiocephalic vein
 - receives lymph from the right lymph duct.
 - is accompanied by right phrenic vein.
 - Left brachiocephalic vein
 - is twice as long as the right
 - runs obliquely down and behind the manubrium
 - crosses the roots of the three major branches of the aorta
 - receives lymph from the thoracic duct
- Aorta
 - Ascending
 - begins at the aortic orifice
 - ascends to the 2nd right sternocostal joint
 - Arch
 - Begins at the 2nd right sternocostal joint and arches superiorly and to the left
 - Anterior to the right pulmonary artery and bifurcation of the trachea
 - Passes over the root of the right lung
 - Ends at the body of the T4 vertebra
 - Descending (thoracic)
 - begins at the body of T4 vertebra
 - descends on the left side of the bodies of T5-12 vertebrae, posterior to the root of the left lung and the pericardium
 - enters the abdomen through the aortic hiatus at the T12 vertebral body
 - has a number of branches:
 - bronchial (1-2)
 - pericardial (twigs)
 - superior phrenic (1 pair)
 - esophageal (2)
 - posterior intercostal (9 pairs)
 - subcostal (1 pair)
- Trachea
 - Continues from the larynx
 - Contains cartilaginous semicircular rings
 - Is completed by muscle posteriorly
 - Descends anterior to the esophagus, slightly to the right of the midsagittal plane
 - Bifurcates into right and left main bronchi at level of T4/T5 (angle of Louis)
 - Right bronchi divides into upper and lower lobar bronchi before entering the right lung
- Esophagus
 - Is a fibromuscular tube from the pharynx to the stomach
 - Contains both circular and longitudinal muscles, both skeletal and smooth
 - upper 1/3-skeletal muscle
 - lower 2/3-smooth muscle
 - Passes through right crus of diaphragm at T10
 - Continues for 1-2 cm below diaphragm
 - Supplied by esophageal plexus of nerves derived from
 - right and left vagal nerves
 - sympathetic nerves
 - Surrounded by a number of lymph nodes:
 - inferior deep cervical nodes
 - posterior mediastinal nodes
 - intercostal nodes
 - paratracheal nodes
 - superior and inferior tracheobronchial nodes.
 - Vascular supply
 - arterial: esophageal branches of the thoracic aorta
 - venous: azygos, hemiazygos and accessory azygos veins
- Thoracic duct
 - Originates from the cisterna chyli in the abdomen
 - Contains valves

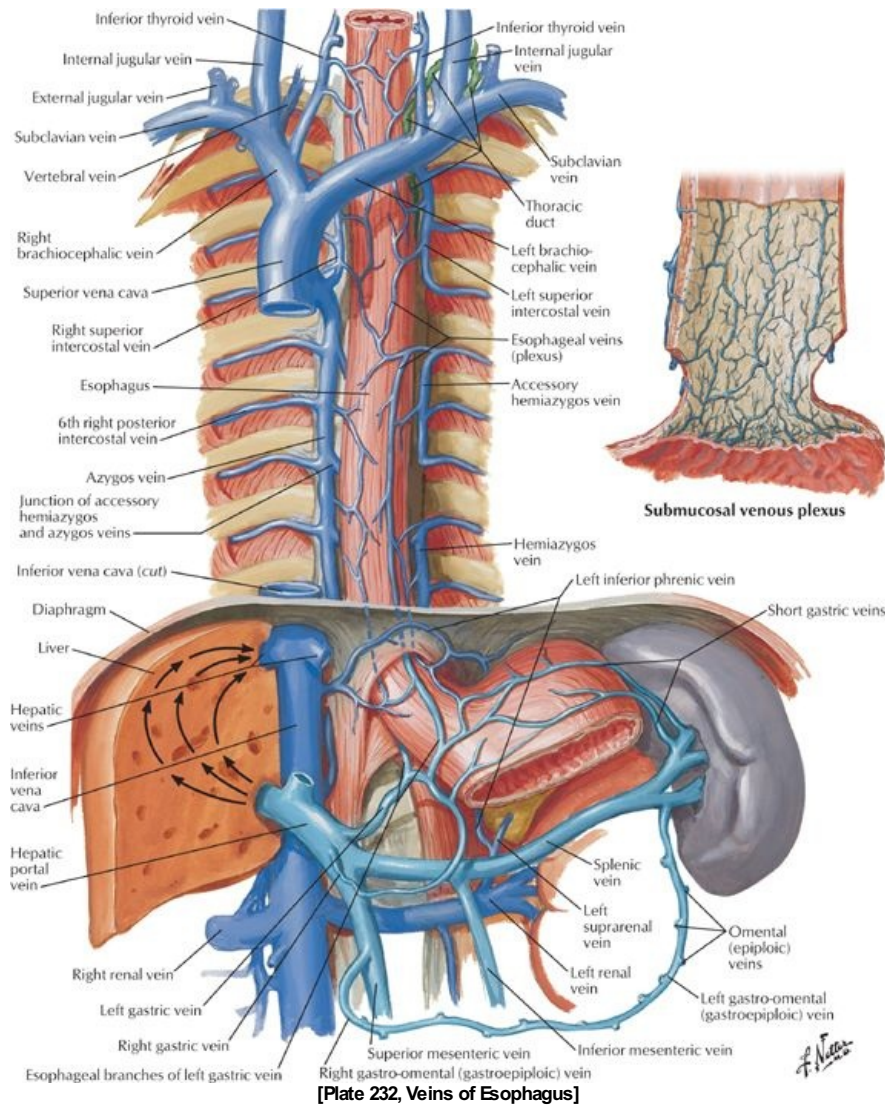
- Ascends through the aortic hiatus in the diaphragm
- Lies anterior to the bodies of T6-12 vertebral bodies, between the thoracic aorta and the azygos vein
- Conveys lymph from the limbs, pelvic and abdominal cavities, left side of the thorax, left upper limb and left side of the head and neck
- Empties into the venous system at the junction of the left internal jugular and left subclavian veins
- i. Azygos venous system
 - Drains blood from the back and thoracoabdominal walls
 - Is highly variable
 - Is composed of an unpaired azygos vein and its main tributary, the hemiazygos vein.
 - Offers an alternate route for blood to reach the heart if the inferior vena cava is blocked
 - Azygos vein
 - arises from ascending lumbar and/or renal veins and subcostal veins
 - ascends on the right side of the bodies of T5-T12 vertebrae
 - arches over the root of the right lung to join the superior vena cava
 - receives blood from
 - hemiazygos vein
 - posterior intercostals veins
 - esophageal veins
 - bronchial veins
 - communications with the vertebral venous plexus
 - Hemiazygos vein
 - arises from the left subcostal and ascending lumbar veins
 - ascends on the left side of the vertebral column from T12-T9
 - crosses the T9 vertebrae posterior to the aorta, esophagus and thoracic duct to empty into the azygos vein
 - receives blood from
 - inferior three posterior intercostals
 - inferior esophageal veins
 - accessory hemiazygos (occasionally)
 - Accessory hemiazygos vein
 - begins at the 4th or 5th intercostal space on the left
 - descends on the left side of vertebrae T5-T8
 - crosses over T7 or T8 vertebrae to join the azygos
 - sometimes joins the hemiazygos
 - receives blood from
 - posterior intercostal veins from the 4th through 8th intercostal spaces
 - left superior intercostal vein (occasionally)
- j. Vagus nerves and recurrent laryngeal nerves
 - The right vagus nerve
 - enters the thorax anterior to the right subclavian artery and immediately gives rise to the right recurrent laryngeal nerve, which loops around the right subclavian artery and ascends into the neck
 - descends on the right side of the trachea
 - passes posterior to the right brachiocephalic vein, superior vena cava and root of the right lung
 - gives rise to branches of the right pulmonary plexus
 - continues to the esophagus, where it contributes to the esophageal nerve plexus and continues as the anterior vagal trunk into the abdomen
 - The left vagus nerve
 - enters the mediastinum between the left common carotid and left subclavian arteries
 - descends with the left phrenic nerve to the aortic arch
 - gives off the left recurrent laryngeal nerve just below the arch, which loops around the arch and ascends into the neck
 - passes posterior to the root of the left lung where it contributes to the left pulmonary plexus
 - continues as a single nerve to the esophagus where it contributes to the esophageal nerve plexus and continues as the posterior vagal trunk into the abdomen
- k. Phrenic nerves
 - Supply motor and sensory fibers to the diaphragm
 - Enter the superior mediastinum between the subclavian artery and brachiocephalic vein on either side
 - Pass anterior to the roots of the lungs, unlike the vagus nerve
 - The right phrenic nerve descends on the right side of the inferior vena cava to the diaphragm
 - The left phrenic nerve
 - crosses the arch of the aorta
 - descends anterior to the root of the left lung and along the pericardium over the left atrium and ventricle
 - pierces the diaphragm to the left of the pericardium
- 1. Thoracic sympathetic trunks
 - Are continuous with the cervical and lumbar sympathetic trunks
 - Shift medially as they descend, crossing from the heads of the ribs to the costovertebral joints to the sides of the vertebral bodies
 - Give off the paired thoracic splanchnic nerves
 - greater splanchnic: from T5-T9 vertebral levels
 - lesser splanchnic: from T10-T11 vertebral levels
 - least splanchnic: from T12 vertebral level

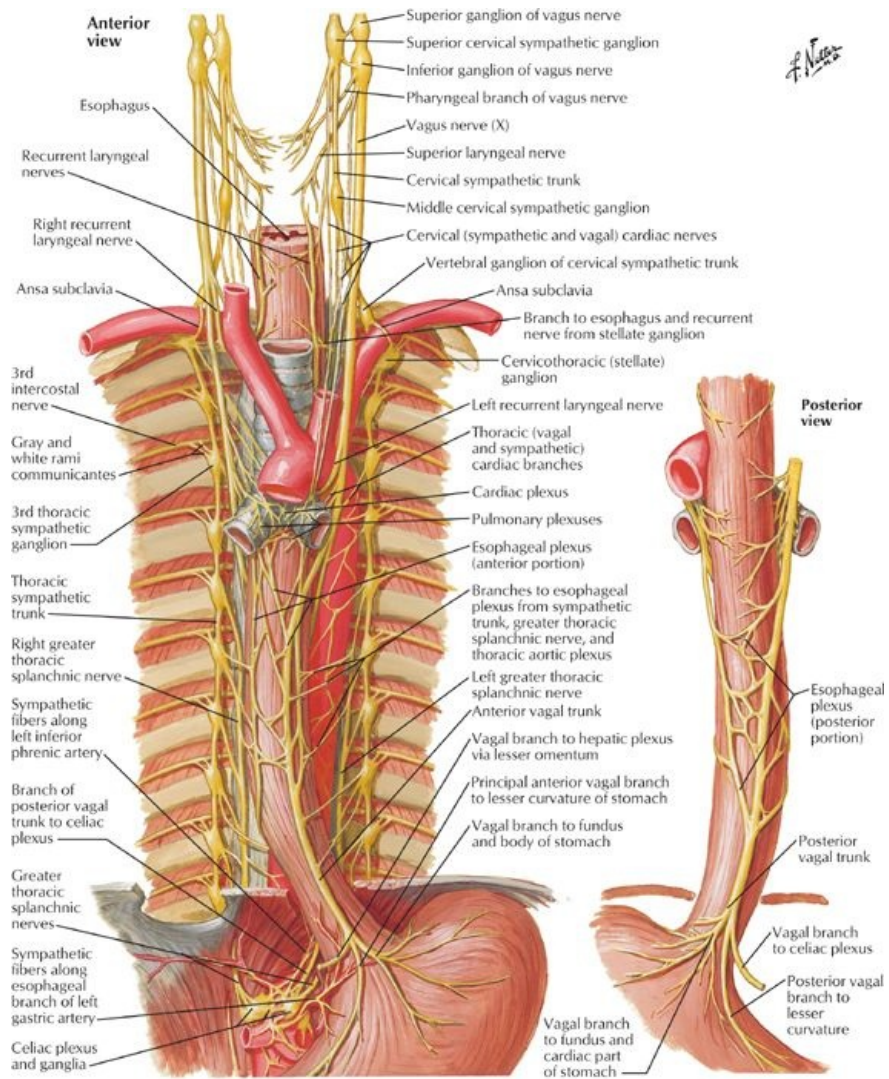


[Plate 226, Esophagus In Situ]



[Plate 231, Arteries of Esophagus]





[Plate 234, Nerves of Esophagus]

FACTS & HINTS

High-Yield Facts

Clinical Points

Recurrent laryngeal nerve injury

- The recurrent laryngeal nerve supplies all of the intrinsic muscles of the larynx but one.
- Surgery, injury, or disease affecting the contents of superior mediastinum can damage either or both recurrent laryngeal nerves, reducing the voice to a hoarse whisper.
- The left recurrent laryngeal nerve passes beneath the arch of the aorta and ascends to the neck between the trachea and the esophagus. Bronchogenic or esophageal carcinoma or an aneurysm of the arch of the aorta can thus affect this nerve.

Chylothorax

- Surgical procedures involving the posterior mediastinum can injure the thoracic duct, which is hard to identify because it has a thin wall and is usually colorless.
- Injury to the thoracic duct can lead to leakage of lymph into the thoracic cavity at a volume of up to 200 mL per hour.
- Lymph is called chyle when it is carrying chylomicrons (fat droplets) from the digestion of food in the gastrointestinal system.
- If lymph from the thoracic duct enters the pleural cavity, the resulting condition is called a chylothorax and may require removal by thoracocentesis.

Mnemonics

Memory Aids

To remember the spinal nerve contributions to the phrenic nerve: **C3,4,5 keeps the diaphragm alive**

8-10-12:	T8-Site at which inferior vena cava pierces the diaphragm
	T10-Site at which esophagus pierces the diaphragm
	T12-Site at which aorta pierces the diaphragm

Memory Aids

SAT (for major contents of the superior mediastinum): **S**uperior vena cava, **A**rch of aorta, and **T**rachea

Turkeys Blow Eggs: Trachea lies **B**ehind the **E**sophagus

page 122
page 123

Memory Aids

Relationship of Thoracic Duct to Esophagus and Azygos Vein

"The duck lies between two geoses." duck = thoracic duct

Two geoses = azyGOOSE and esophaGOOSE

Abdomen

page 123
page 124

24 Topographic Anatomy

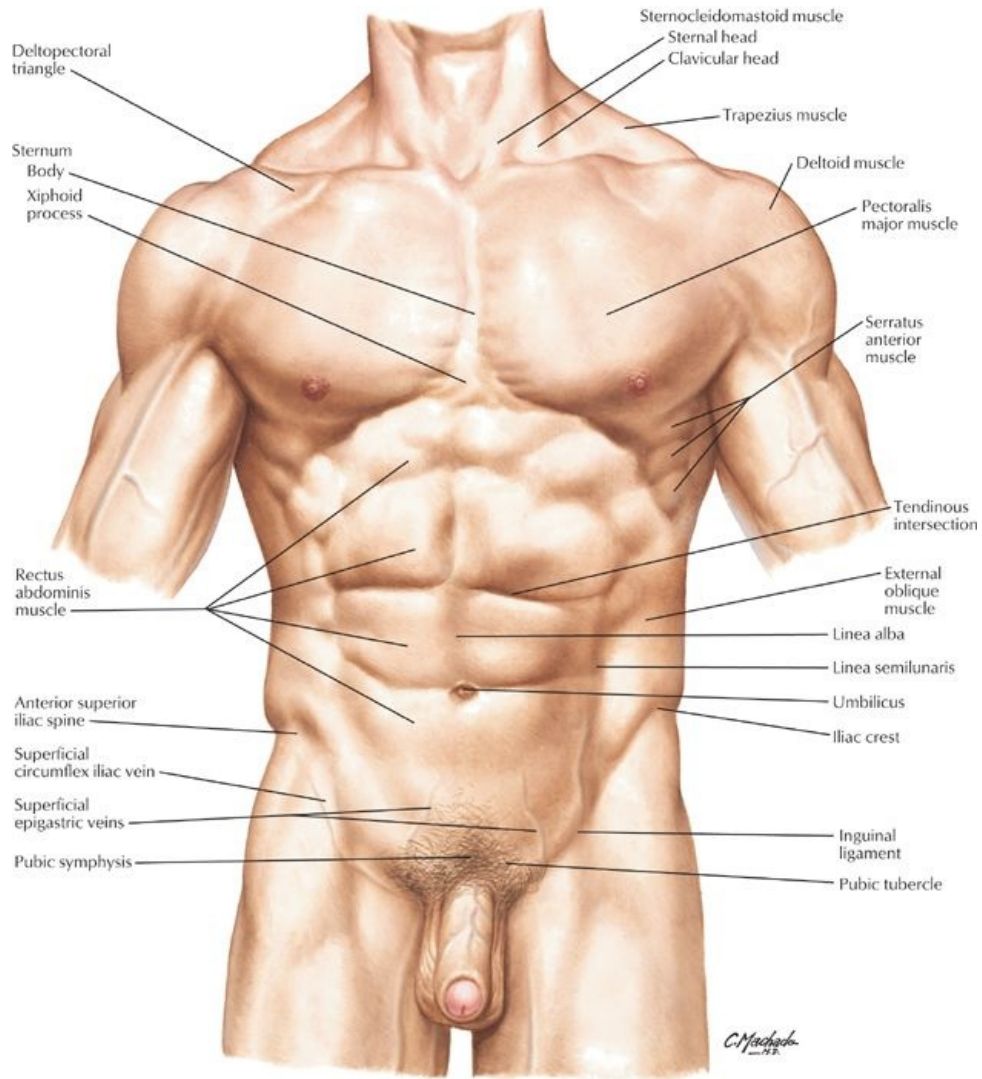
STUDY AIMS

At the end of your study, you should be able to

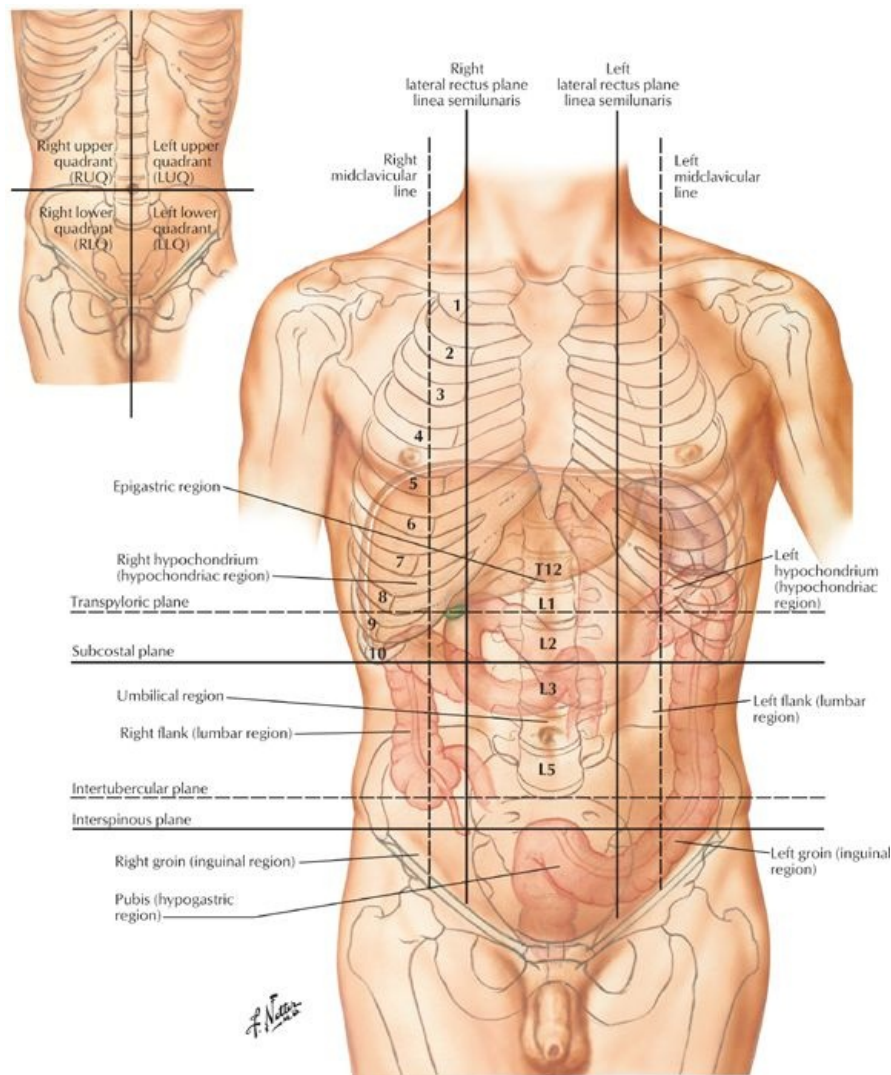
- Understand the boundaries of the abdominal cavity
- Identify surface landmarks of the abdomen
- Know the four quadrants of the abdomen and their contents
- Know the nine regions of the abdomen
- Know the lines and planes that create the four quadrants and nine regions

GUIDE

Abdomen: Topographic Anatomy



[Plate 240, Abdomen]



[Plate 242, Regions and Planes of Abdomen]

Abdomen: General description

- Lies between the diaphragm and the pelvic inlet.
- Is the largest cavity in the body and is continuous with the pelvic cavity.
- Lined with parietal peritoneum, a serous membrane
- Bounded superiorly by the diaphragm
 - Has a concave dome
 - Spleen, liver, part of the stomach, and part of the kidneys lies under the dome and are protected by the lower ribs and costal cartilages.
- Lower extent lies in the greater pelvis
 - Between the ala or wings of the ilia
 - Ileum, cecum, and sigmoid colon thus partly protected
- Anterior and lateral walls composed of muscle
 - Viscera in these areas are more likely to be damaged by blunt force and penetrating injuries.
- Posterior wall comprised of vertebral column, the lower ribs, and associated muscles
 - Protect the abdominal contents.

Bony landmarks of the abdomen

- Xiphoid process
- Lower six costal cartilages
- Anterior ends of the lower six ribs (ribs 7 to 12) (Section 3-3: Thorax-Body Wall)
- Lumbar vertebrae (L1 to L5)
- Pelvis
 - Iliac crest
 - Anterior superior iliac spine (ASIS)
 - Anterior inferior iliac spine
 - Pubic symphysis
 - Pubic crest and pubic tubercle

- Costal margin: Formed by the medial borders of the 7th through 10th costal cartilages
- Rectus sheath
 - From xiphoid process and 5th through 7th costal cartilages → pubic symphysis and pubic crest
 - Contains rectus abdominis muscle (*Section 4-2: Abdomen-Body Wall*)
- Linea alba
 - Slight indentation that can sometimes be seen extending from the xiphoid process to the pubic symphysis
 - A fibrous raphe where the aponeuroses of the external and internal abdominal oblique and the transversus abdominis muscles on either side unite.
- Semilunar line (linea semilunaris)
 - Vertical indentation seen as a curved line from the tip of the ninth rib cartilage to the pubic tubercle on each side in well-muscled individuals
 - Represents the lateral edge of the rectus abdominis muscle
- Tendinous intersections
 - Transverse attachments between the anterior rectus sheath and rectus abdominis muscle
 - May be seen as transverse grooves in skin on either side of midline (six-pack)
- Inguinal ligament
 - From ASIS to pubic tubercle of pelvis
 - Folded inferior edge of external abdominal aponeurosis
 - Separates abdominal region from thigh
- Umbilicus
 - At approximate level of intervertebral disc between the L3 and L4
 - Marks the T10 dermatome
- Liver
 - Mainly in the right upper quadrant, behind ribs 7 through 11 on the right side
 - Crosses the midline to reach towards the left nipple (*Section 4-5: Abdomen-Viscera (Accessory Organs)*)
- Spleen
 - Beneath ribs 9 through 11 on the left side
 - 10th rib is axis of spleen
- Kidneys
 - Located in loin region
 - Left kidney is higher than right (pelvis at L1/2 on left and L2/3 on right) (*Section 4-8: Abdomen-Kidneys and Suprarenal Glands*)

Abdominal contents

- Gastrointestinal tract
 - Stomach
 - Duodenum
 - Ileum
 - Jejunum
 - Cecum and appendix
 - Ascending, transverse and descending colon
 - Part of the sigmoid colon
- Accessory digestive organs
 - Liver
 - Gallbladder
 - Pancreas
- Spleen
- Suprarenal glands
- Urinary system-kidneys and ureters
 - Kidneys are the only organs developing beneath the parietal peritoneum
 - Never have a mesentery
 - Thus are primarily retroperitoneal
- Organs that develop within the abdominal cavity and then become retroperitoneal
 - Are called secondarily retroperitoneal
 - Pancreas
 - Two thirds of the duodenum
 - Ascending and descending colon.
- All the rest of the organs are peritoneal
 - Lie within the peritoneal cavity
 - Covered by a layer of visceral peritoneum
 - Visceral peritoneum is continuous with the parietal peritoneum lining the cavity via a mesentery.

Abdominal regions

- Abdominal quadrants
 - Clinicians usually divide the abdomen into four quadrants for descriptive purposes, using the following planes:
 - Median plane: imaginary vertical line following the linea alba from the xiphoid process to the pubic symphysis
 - Transumbilical plane: imaginary horizontal line at the level of the umbilicus
 - These lines or planes create four quadrants
 - Right upper
 - Left upper
 - Right lower
 - Left lower
- Abdominal regions

- Clinicians may divide the abdomen into nine regions
 - For more accurate descriptive and diagnostic purposes
 - Use two vertical and three horizontal lines or planes
- Horizontal planes (in descending order):
 - *Subcostal plane*: passes through the lower border of the 10th costal cartilage on either side
 - Sometimes the *transpyloric plane* is used instead of the subcostal; passes through the pylorus on the right and the tips of the ninth costal cartilage on either side
 - *Transumbilical plane*: passes through the umbilicus at the level of the L3/4 intervertebral disc
 - *Transtubercular (intertubercular) plane*: passes through the tubercles of the iliac crests and the body of L5
- Vertical planes
 - *Right midclavicular line*
 - *Left midclavicular line*
 - Pass from the midpoint of the clavicle to the midpoint of inguinal ligament.
- These planes create nine abdominal regions:
 - Right and left hypochondriac regions, superiorly on either side
 - Right and left lumbar (flank) regions, centrally on either side
 - Right and left inguinal (groin) regions, inferiorly on either side
 - Epigastric region superiorly and centrally
 - Umbilical region, with the umbilicus as its center
 - Hypogastric or suprapubic region, inferiorly and centrally
- Descriptive quadrants and regions are essential in clinical practice
 - Each area represents certain visceral structures
 - Allow correlation of pain and referred pain from these areas to specific organs.
- Regions and quadrants are palpated, percussed, and auscultated during clinical examination

page 126
page 127

Contents of the Abdominal Quadrants

Right Upper Quadrant (RUQ)	Left Upper Quadrant (LUQ)
Liver (right lobe)	Liver (left lobe)
Gallbladder	Spleen
Pylorus (of stomach)	Stomach
Duodenum (parts 1 through 3)	Jejunum and proximal ileum
Pancreas (head)	Pancreas (body and tail)
Right kidney and suprarenal gland	Left kidney and suprarenal gland
Colon: distal ascending colon, hepatic flexure and right half of transverse colon	Colon: left half of transverse colon, splenic flexure and superior part of descending colon
Right Lower Quadrant (RLQ)	Left Lower Quadrant (LLQ)
Majority of ileum	Distal descending colon
Cecum with vermiform appendix	Sigmoid colon
Proximal ascending colon	Left ureter
Proximal right ureter	
Ovaries Uterine tubes Right and left ductus deferens Uterus (if enlarged) Urinary bladder (if full, especially in women)	

FACTS & HINTS

High-Yield Facts

Clinical Points

McBurney's Point and Appendicitis

- **McBurney's point:** A surface landmark that roughly indicates the location of the appendix, located approximately one third of the way along a line from the anterior superior iliac spine to the umbilicus.
- **Appendicitis:** inflammation of the appendix. Pain first presents in the epigastric region, moves to the umbilical region and then localizes in the right lower quadrant. Rupture of the appendix leads to peritonitis (inflammation of the peritoneum). This presents with severe pain, fever, and abdominal rigidity.
- **Muscle-splitting incision (of McBurney):** used to access the appendix. Each muscle layer is split in the direction of the fiber orientation. The incision must not go too far laterally or the ascending branch of the deep circumflex iliac artery may be severed.

Clinical Points

Grey-Turner's sign

- Local right flank redness or bruising (ecchymosis)
- Indicates a retroperitoneal hemorrhage
- Usually takes 24 to 48 hours to appear
- Can be predictive of severe hemorrhagic pancreatitis, abdominal injury, or metastatic cancer

page 127
page 128

Clinical Points

Cullen's sign

- Discoloration (ecchymosis) around the umbilicus
- A result of peritoneal hemorrhage

Mnemonics

Memory Aids

Causes for abdominal expansion (protuberance):	
Remember the five Fs:	Fat
	Feces
	Fetus
	Flatus
	Fluid.

25 Body Wall

STUDY AIMS

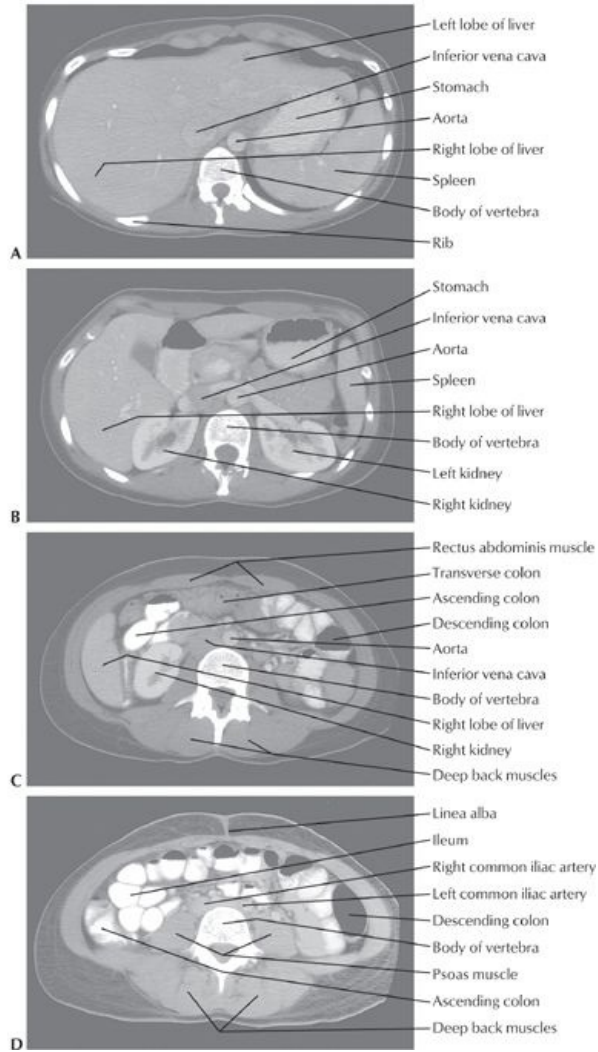
At the end of your study, you should be able to:

- Know the layers of the anterior abdominal wall from superficial to deep
- Understand the orientation and functions of the muscles of the anterolateral abdominal wall
- Describe the structure of the rectus sheath and its contents
- Describe the neurovascular supply of the abdominal wall
- Understand the boundaries of the inguinal canal and layers of the spermatic cord
- Describe the boundaries of Hesselbach's triangle
- Know the etiology and location of the umbilical peritoneal folds
- Understand the structure and organization of the posterior abdominal wall and its neurovascular relations

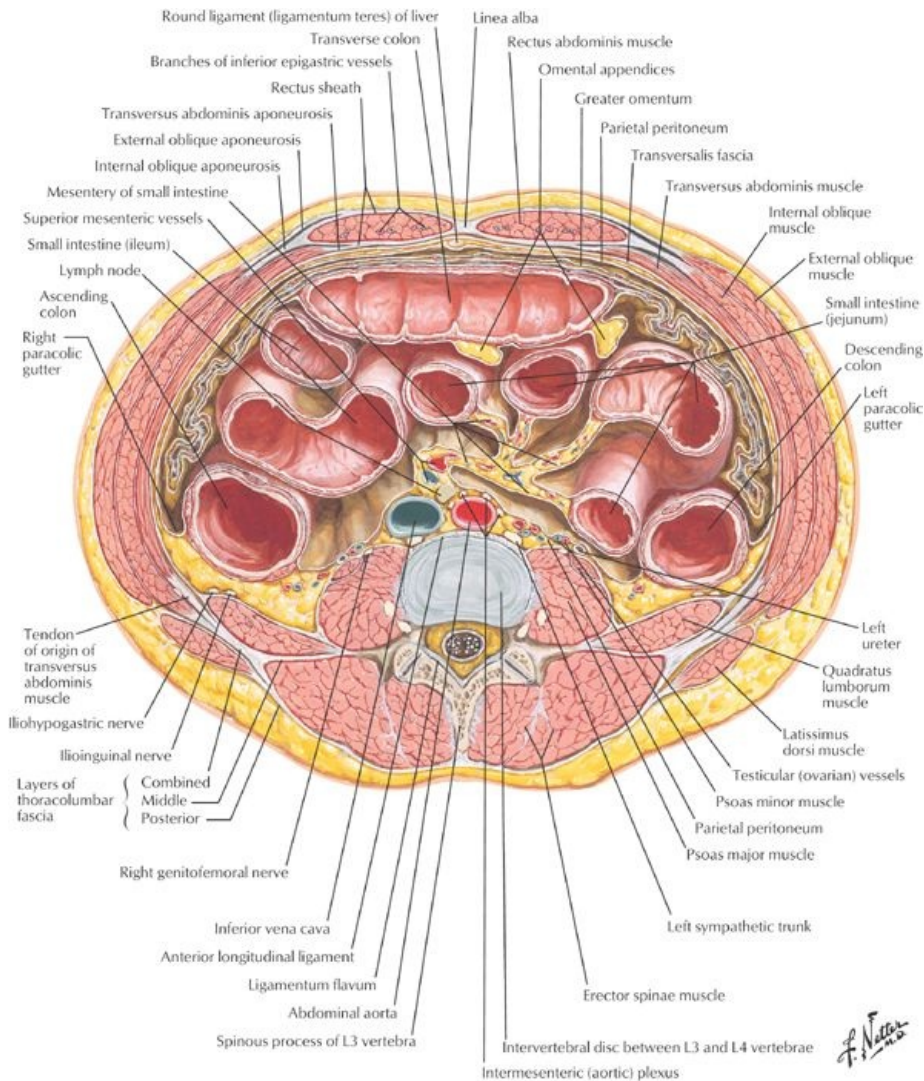
GUIDE

Abdomen: Body Wall

Series of abdominal axial CT images from superior (A) to inferior (D)



[Plate 324, Abdominal Scans: Axial CT Images]



[Plate 330, Schematic Cross Section of Abdomen at L3, 4]

Anterolateral Abdominal Wall

page 129
page 130

- Fascial layers
 - Superficial fascia: two layers in abdomen
 - Fatty superficial layer (Camper's fascia)
 - Deeper membranous layer (Scarper's fascia)
 - Deep fascia-a very thin layer investing the most superficial muscles.
 - Transversalis fascia (endoabdominal fascia)
 - A thin membranous sheet lining most of the abdominal wall
 - Lies deep to the transversus muscles and the linea alba
 - Endoabdominal fat separates the transversalis fascia from the parietal peritoneum
- Muscles
 - Functions
 - Protect the viscera
 - Help maintain posture
 - Can compress the abdominal contents, thus raising intra-abdominal pressure, such as in sneezing, coughing, defecating, micturating, lifting, and childbirth
 - Four paired muscles make up the anterolateral abdominal wall
 - Three flat muscles
 - A single vertical muscle.
 - Three flat muscles include
 - The *external abdominal oblique*
 - a. Largest and most superficial
 - b. Fibers run inferiorly and medially and end in aponeurosis that contributes to the rectus sheath.
 - c. Inferior border of its aponeurosis forms the inguinal ligament, where it thickens and folds back on itself
 - d. Innervated segmentally by T6-T12 spinal nerves and subcostal nerve
 - The *internal abdominal oblique*
 - a. A thin muscular layer
 - b. Fibers run inferiorly and laterally and end in an aponeurosis that contributes to the rectus sheath
 - c. Inferior aponeurotic fibers join with those of the rectus abdominis to form the conjoint tendon, inserting onto the pubic crest

- d. Innervated segmentally by the ventral rami of T6-T12 spinal nerves
- The *transversus abdominis*
 - a. Innermost of the three flat muscles
 - b. Fibers run transversely and medially and end in an aponeurosis that contributes to the rectus sheath.
 - c. Innervated segmentally by the ventral rami of T6-T12 spinal nerves
- Linea alba
 - a. Tendinous raphe running vertically in the midline
 - b. Formed by the union of the aponeuroses of the flat muscles on either side
 - c. Largely avascular
 - d. Umbilicus found in midline
- Vertical muscle = *rectus abdominis*
 - Paired
 - Separated by the linea alba in the midline
 - Wider superiorly than inferiorly
 - Typically composed of four segments connected by tendinous intersections that attach anteriorly to the sheath of this muscle
 - Innervated segmentally by the ventral rami of T6-T12 spinal nerves
 - Have the superior epigastric and the inferior epigastric arteries running inferiorly and superiorly, respectively, on their deep surfaces.
- Pyramidalis muscle
 - Small, insignificant, triangular muscles arising from the body of the pubis inferiorly
 - Inserts into the linea alba medially
 - Absent in 20% of people
- Rectus sheath
 - Atough, fibrous sheath composed of the aponeuroses of the three flat muscles
 - Extends from the xiphoid process and fifth through seventh costal cartilages to pubic symphysis and crests
 - Contains the superior and inferior epigastric vessels, lymphatics and branches of the ventral primary rami of T7-T12
 - Encloses the rectus abdominis and the pyramidalis muscle
 - Semilunar line marks lateral border
 - Has a crescent-shaped line-the arcuate line-on its posterior wall approximately three fourths of the way down the wall
 - Above the arcuate line:
 - Anterior wall composed of the aponeurosis of the external abdominal oblique and the anterior layer of the aponeurosis of the internal abdominal oblique
 - Posterior wall composed of the posterior layer of the aponeurosis of the internal abdominal oblique, the aponeurosis of the transversus abdominis, the transversalis fascia of the abdomen, and parietal peritoneum
 - Below arcuate line
 - Aponeuroses of all three flat muscles pass anterior to the rectus muscle, reinforcing the anterior wall
 - Posterior wall composed of just transversalis fascia and parietal peritoneum
 - Has vessels and nerves entering the sheath at its lateral edge, the semilunar line, to supply the rectus muscle.

page 130

page 131

Muscle	Proximal Attachment (Origin)	Distal Attachment (Insertion)	Innervation	Blood Supply	Main Actions
External oblique	External surfaces of 5th to 12th ribs	Linea alba, pubic tubercle, and anterior half of iliac crest	Inferior seven thoracic nerves	Superior and inferior epigastric arteries	Compresses and supports abdominal viscera; flexes and rotates trunk
Internal oblique	Thoracolumbar fascia, anterior two thirds of iliac crest, and lateral half of inguinal ligament	Inferior borders of 10th to 12th ribs, linea alba, and pubis via conjoint tendon	Ventral rami of inferior six thoracic and 1st lumbar nerves	Superior and inferior epigastric and deep circumflex iliac arteries	Compresses and supports abdominal viscera; flexes and rotates trunk
Transversus abdominis	Internal surfaces of 7-12 costal cartilages, thoracolumbar fascia, iliac crest, and lateral third of inguinal ligament	Linea alba with aponeurosis of internal oblique, pubic crest, and pecten pubis via conjoint tendon	Ventral rami of inferior six thoracic and 1st lumbar nerves	Deep circumflex iliac, and inferior epigastric arteries	Compresses and supports abdominal viscera
Rectus abdominis	Pubic symphysis and pubic crest	Xiphoid process and costal cartilages 5-7	Ventral rami of inferior six thoracic nerves	Superior and inferior epigastric arteries	Flexes trunk and compresses abdominal viscera
Pyramidalis	Body of pubis, anterior to rectus abdominis	Linea alba		Inferior epigastric artery	Tenses the linea alba

page 131

page 132

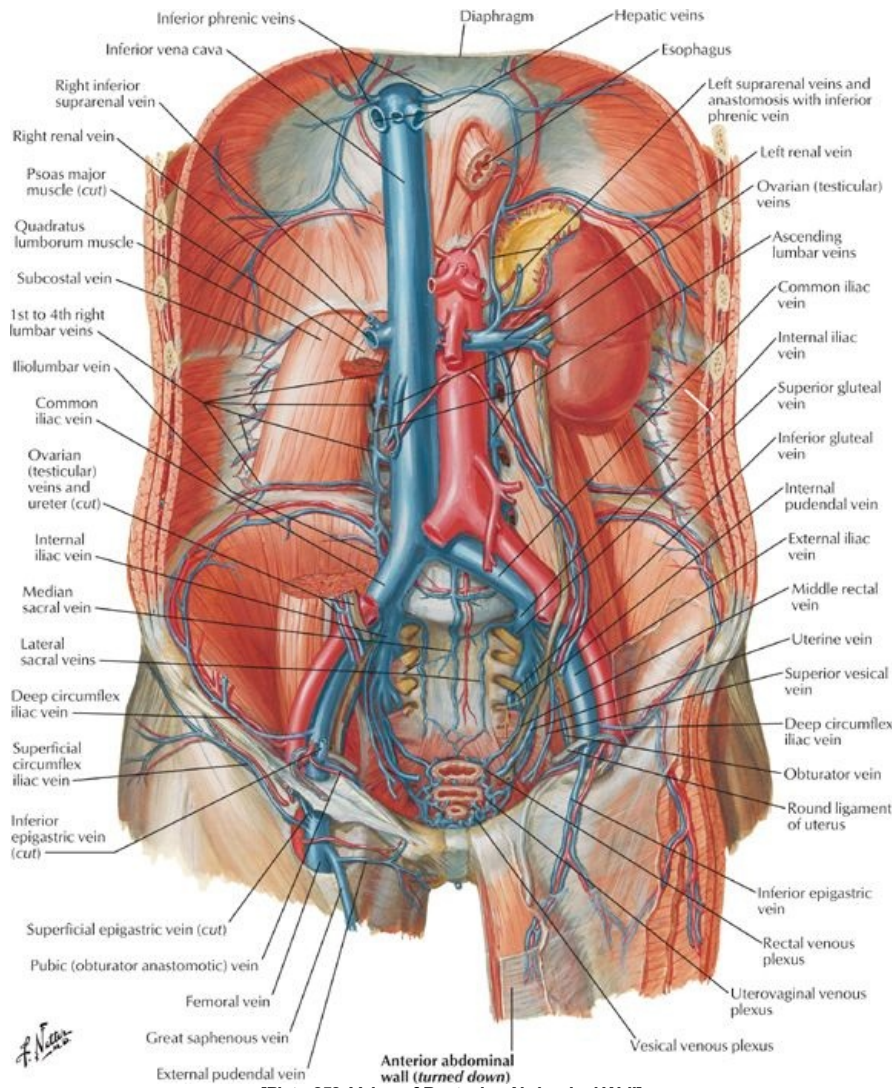
- Nerve supply
 - Neurovascular plane
 - Found between the internal abdominal oblique and the transversus abdominis
 - Contains the vessels and nerves supplying the skin and muscles of the anterior and lateral abdominal wall.
 - Nerves and vessels are transversely oriented and segmental
 - Nerves
 - Thoracoabdominal nerves
 - Anterior cutaneous branches of the ventral primary rami of T7-T11
 - a. T7-T9 supply skin above the umbilicus
 - b. T10 supplies skin around the umbilicus
 - c. T11 (plus subcostal and ilioinguinal and iliohypogastric nerves) supplies skin below umbilicus

- d. Subcostal nerves (T12) supply skin below umbilicus
- e. Iliohypogastric and ilioinguinal nerves (terminal branches of L1) supplies skin below umbilicus

• **Vascular supply**

- **Arteries**
 - Anterior and collateral branches of posterior intercostal arteries
 - Branches of the internal thoracic arteries
 - a. Superior epigastric
 - b. Musculophrenic
 - Inferior epigastric (from external iliac)
 - Branches of the femoral artery
 - a. Superficial epigastric
 - b. Superficial circumflex iliac
- **Veins**
 - Venous drainage is via venae comitantes (veins corresponding to the arteries listed)
 - Blood drains away from the umbilicus
 - Venous drainage to the caval system
- **Lymphatics**
 - Superficial lymphatics above the umbilicus lymph drains to the axillary nodes
 - Superficial lymphatics below the umbilicus drain to the superficial inguinal nodes
 - Deep lymphatics
 - a. Accompany deep veins
 - b. Drain to external iliac, common iliac, and lumbar nodes

Posterior abdominal wall



page 132
page 133

Muscle	Superior Attachment (Origin)	Inferior Attachment (Insertion)	Innervation	Blood Supply	Actions
Psoas major	Transverse processes of lumbar vertebrae; sides of bodies of T12-L5	Lesser trochanter of femur	Lumbar plexus via ventral	Lumbar arteries	Acting superiorly with iliacus, flexes hip; acting inferiorly, flexes vertebral column laterally; used to balance

	vertebrae, and intervening intervertebral discs		branches of L1-L4 nerves		trunk in sitting position; acting inferiorly with iliacus, flexes trunk
Iliacus	Superior two thirds of iliac fossa, ala of sacrum, and anterior sacroiliac ligaments	Lesser trochanter of femur and shaft inferior to it, and to psoas major tendon	Femoral nerve (L2-L4)	Iliolumbar artery	Flexes hip and stabilizes hip joint; acts with psoas major
Quadratus lumborum	Medial half of inferior border of 12th rib and tips of lumbar transverse processes	Iliolumbar ligament and internal lip of iliac crest	Ventral branches of T12 and L1-L4 nerves	Iliolumbar artery	Extends and laterally flexes vertebral column; fixes 12th rib during inspiration
Diaphragm	Xiphoid process, lower six costal cartilages, L1-L3 vertebrae	Converge into central tendon	Phrenic nerve (C3-C5)	Pericardiophrenic, musculophrenic, superior and inferior phrenic arteries	Draws central tendon down and forward during inspiration

page 133
page 134
page 134
page 135

• Fascia

- Superficial fascia: single layer
- Deep fascia-a very thin layer investing the most superficial muscles.
- Transversalis fascia (endoabdominal fascia)
- Endoabdominal fat separates the transversalis fascia from the parietal peritoneum
- Psoas sheath
 - Fascia covering the psoas muscle
 - Attaches to lumbar vertebrae and pelvic brim
 - Thickened superiorly to form the medial arcuate ligament-a site of origin of the muscle of the diaphragm
- Fascia of quadratus lumborum
 - Fuses medially with psoas fascia
 - Thickened superiorly to form the lateral arcuate ligament-a site of origin of the muscle of the diaphragm
- Thoracolumbar fascia (*Section 2: Back and Spinal Cord*)
 - Composed of anterior and posterior layers
 - Encloses the deep muscles of the back
 - Thick and strong in the lumbar region
 - Extends from 12th rib to iliac crest and continuous laterally with deep fascia of internal oblique and transversus abdominus muscles

• Muscles

- Psoas major
 - Long and thick
 - Lies lateral, and is attached to, the lumbar vertebrae
 - Tendon passes deep to inguinal ligament to lesser trochanter of femur
 - Together with iliacus forms iliopsoas muscle, which flexes the hip, helps maintain erect posture
 - Lumbar plexus of nerves embedded within it
- Iliacus
 - Attaches to superior two thirds of iliac fossa
 - Joins psoas to form iliopsoas
- Quadratus lumborum
 - Thick quadrangular muscle of posterior wall
 - Extends from 12th rib and tips of lumbar transverse processes to iliac crest
 - Flexes and laterally extends vertebral column

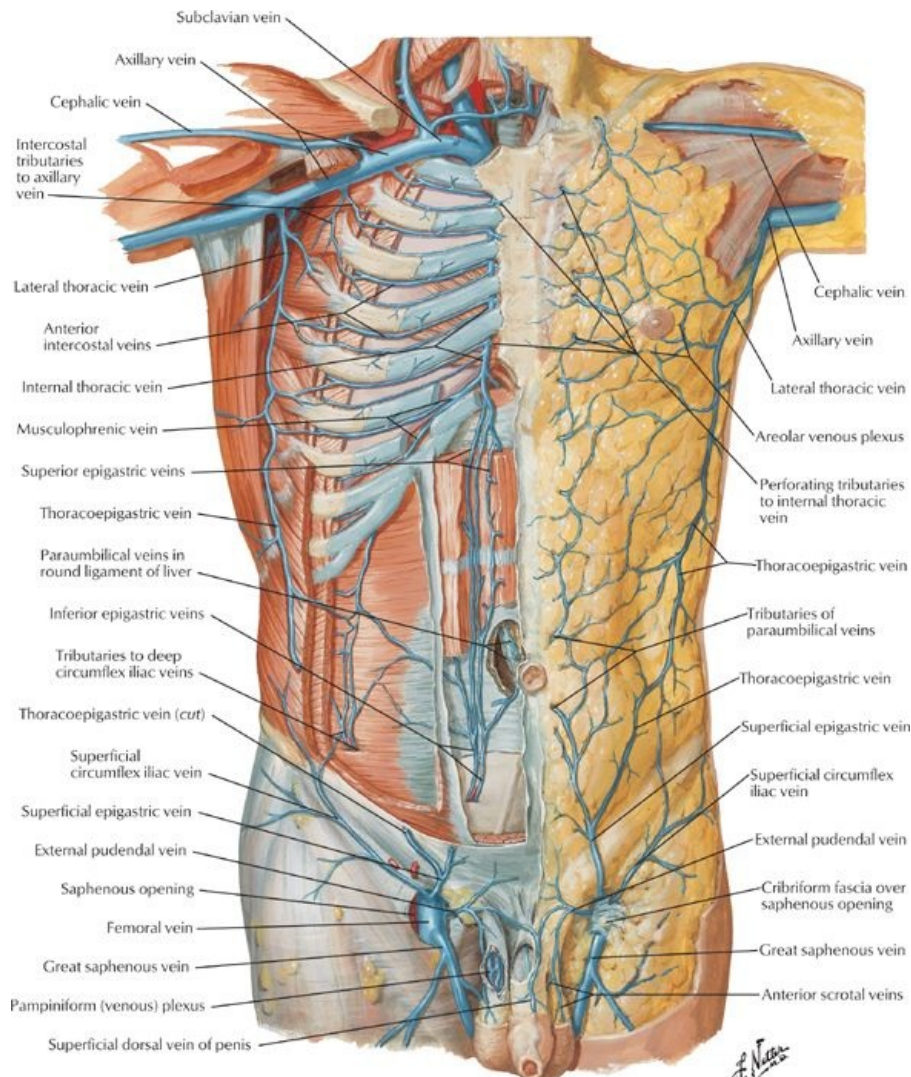
• Arteries of the posterior abdominal wall (*Section 4-6: Abdomen-Visceral Vasculature*)

- Abdominal aorta
 - Origin of most of arteries supplying the posterior wall
 - Begins anterior to the body of T12 and ends at bifurcation of the common iliac arteries at L4
- Common iliac artery
 - Follows the medial border of the psoas
 - Divides into internal and external iliac arteries at pelvic brim
 - External iliac
 - a. Gives off inferior epigastric and deep circumflex arteries
 - b. Exits under the inguinal ligament as the femoral artery
 - c. Supplies lower limb
 - Internal iliac artery supplies pelvis
- Unpaired visceral branches of abdominal aorta
 - Celiac trunk (T12)
 - Superior mesenteric (L1)
 - Inferior mesenteric (L3)
- Paired visceral branches
 - Suprarenal arteries (L1)
 - Renal arteries (L1)
 - Gonadal arteries (L2) (Note: gonadal arteries branch from the anterior aorta)
- Paired parietal branches
 - Subcostal arteries (T12)

- Inferior phrenic arteries
 - Lumbar arteries (four pairs)
 - Unpaired parietal branch: Median sacral artery arising just above aortic bifurcation
- **Veins of the posterior abdominal wall** (Section 4-6: Abdomen-Visceral Vasculature)
 - Inferior vena cava (IVC)
 - Formed from union of common iliac veins
 - Begins anterior to body of L5 and passes through the diaphragm at T8.
 - Its tributaries follow branches of aorta
 - Exceptions:
 - a. Left gonadal vein drains to left renal vein
 - b. Left suprarenal vein drains to left renal vein
 - Blood from abdominal viscera
 - Drains via portal system and liver
 - Reaches IVC through the hepatic veins
 - Ascending lumbar veins
 - Drain to azygos/hemiazygos veins and thence to superior vena cava (SVC)
 - Forms an anastomosis between IVC and SVC.
- **Lymphatics of the posterior abdomen**
 - Common iliac nodes
 - Receive lymph from the external and internal iliac nodes
 - Drain to lumbar (para-aortic) nodes
 - Lumbar (para-aortic) nodes
 - Receive lymph from the posterior abdominal wall, descending colon, kidneys, ureters, testes/ovaries, uterus, uterine tubes
 - Efferent vessels form the lumbar lymphatic trunks
 - Preaortic nodes
 - Receive lymph from the digestive tract, liver, spleen, and pancreas
 - Efferent vessels form the intestinal lymphatic trunks
- **Nerves of the posterior abdominal wall** (Section 4-7: Abdomen-Innervation)
 - Somatic nerves
 - Subcostal nerves
 - a. Ventral primary rami of T12
 - b. Arise in the thorax
 - c. Run inferiorly on surface of quadratus lumborum
 - d. Supply external abdominal oblique and skin of anterolateral abdominal wall
 - Lumbar nerves
 - a. Dorsal and ventral primary rami of lumbar spinal nerves
 - b. Dorsal rami supply muscles and skin of back
 - c. Ventral rami pass into substance of psoas major muscle and form lumbar plexus
 - Nerves of lumbar plexus
 - Iliioinguinal and iliohypogastric nerves (L1)
 - a. Enter abdomen posterior to medial arcuate ligament
 - b. Pierce transverse abdominus near anterior superior iliac spine (ASIS)
 - c. Supply skin of suprapubic and inguinal regions
 - Genitofemoral nerve (L1/2)
 - a. Emerges from anterior surface of psoas muscle
 - b. Runs inferiorly deep to fascia
 - c. Divides into genital and femoral branches
 - Lateral femoral cutaneous nerve (L2/3)
 - a. Emerges from lateral aspect of psoas muscle
 - b. Runs inferiorly on iliacus
 - c. Enters thigh posterior to inguinal ligament and medial to ASIS
 - Obturator nerve (L2-L4)
 - a. Emerges from medial border of psoas
 - b. Descends through pelvis to obturator canal
 - c. Supplies muscles and skin of medial thigh
 - Femoral nerve (L2-L4)
 - a. Emerges from lateral border of psoas
 - b. Innervates iliacus
 - c. Passes beneath inguinal ligament on surface of iliopsoas muscle
 - d. Innervates muscles of anterior thigh
 - Lumbosacral trunk (L4/5)
 - a. Descends over ala of sacrum into pelvis
 - b. Joins in formation of sacral plexus
 - Autonomic nerves
 - Thoracic splanchnic nerves
 - a. Greater (T5-T9), lesser (T10-T11) and least (T12) thoracic splanchnic nerves
 - b. Convey presynaptic sympathetic fibers to celiac, superior mesenteric, and aorticorenal sympathetic ganglia
 - Lumbar splanchnic nerves
 - a. Rise of abdominal sympathetic trunks
 - b. Three to four in number
 - c. Convey presynaptic sympathetic fibers to inferior mesenteric, intermesenteric, and superior hypogastric plexuses
 - Prevertebral sympathetic ganglia
 - a. Celiac
 - b. Superior mesenteric
 - c. Inferior mesenteric
 - d. Aorticorenal
 - Parasympathetic fibers
 - a. Preganglionic
 - b. From anterior and posterior vagal trunks and pelvic splanchnic nerves

- Autonomic plexuses
 - a. Contain preganglionic sympathetic and parasympathetic fibers, postganglionic sympathetic fibers, sympathetic ganglia (prevertebral), and visceral afferent fibers
 - b. Some named for major blood vessels (periarterial): celiac, superior mesenteric, inferior mesenteric, intermesenteric, aorticorenal
 - c. Superior hypogastric plexus-continuous with inferior mesenteric and intermesenteric plexuses at aortic bifurcation

Internal features of anterior abdominal wall



[Plate 250, Veins of Anterior Abdominal Wall]

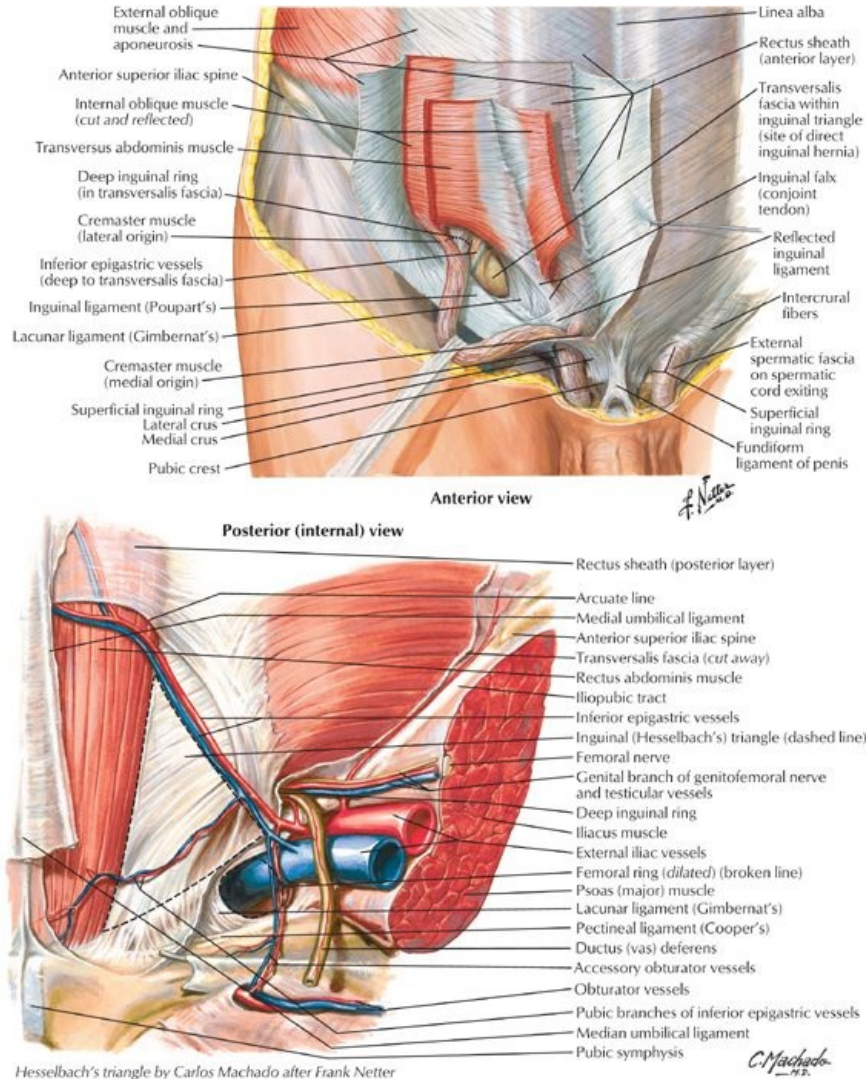
page 135
page 136

- Lined by parietal peritoneum
- Has five peritoneal folds, inferior to the umbilicus
 - Median umbilical fold
 - Extends in the midline from the bladder to the umbilicus
 - Represents the remnant of the urachus
 - Medial umbilical folds (two)
 - One on either side of median umbilical fold
 - Represent remnants of umbilical arteries
 - Lateral umbilical folds (two)
 - One on either lateral side of the medial umbilical folds
 - Over the inferior epigastric vessels
- Peritoneal fossae are formed between the umbilical folds:
 - Supravesical fossae: between the median and medial folds
 - Medial inguinal fossae: between the medial and lateral folds
 - Lateral inguinal fossae:
 - Lateral to lateral folds
 - Site of deep inguinal ring (beneath peritoneum)
- Falciform ligament
 - Asharp-edged fold of peritoneum
 - Extends between peritoneum of the abdominal wall above the umbilicus and the liver
 - Contains the round ligament of the liver (ligamentum teres hepatis: remnant of the umbilical vein)

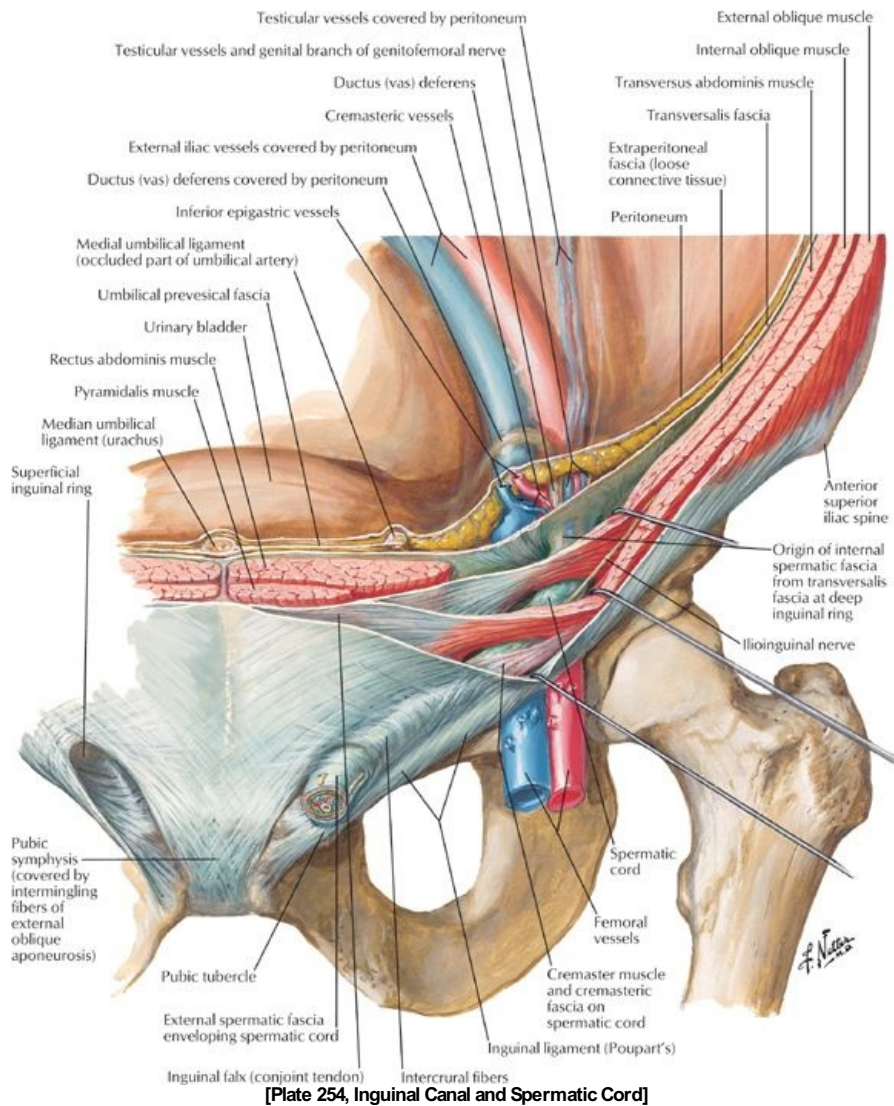
Hesselbach's (inguinal) triangle

- Boundaries:
 - Medially: lateral border of rectus abdominis
 - Laterally: inferior epigastric vessels
 - Inferiorly: inguinal ligament
- Significance
 - Only peritoneum, endoabdominal fascia and transversalis fascia form the wall
 - The superficial inguinal ring lies directly external to it
 - It is thus the site where direct inguinal hernias protrude from the abdominal cavity

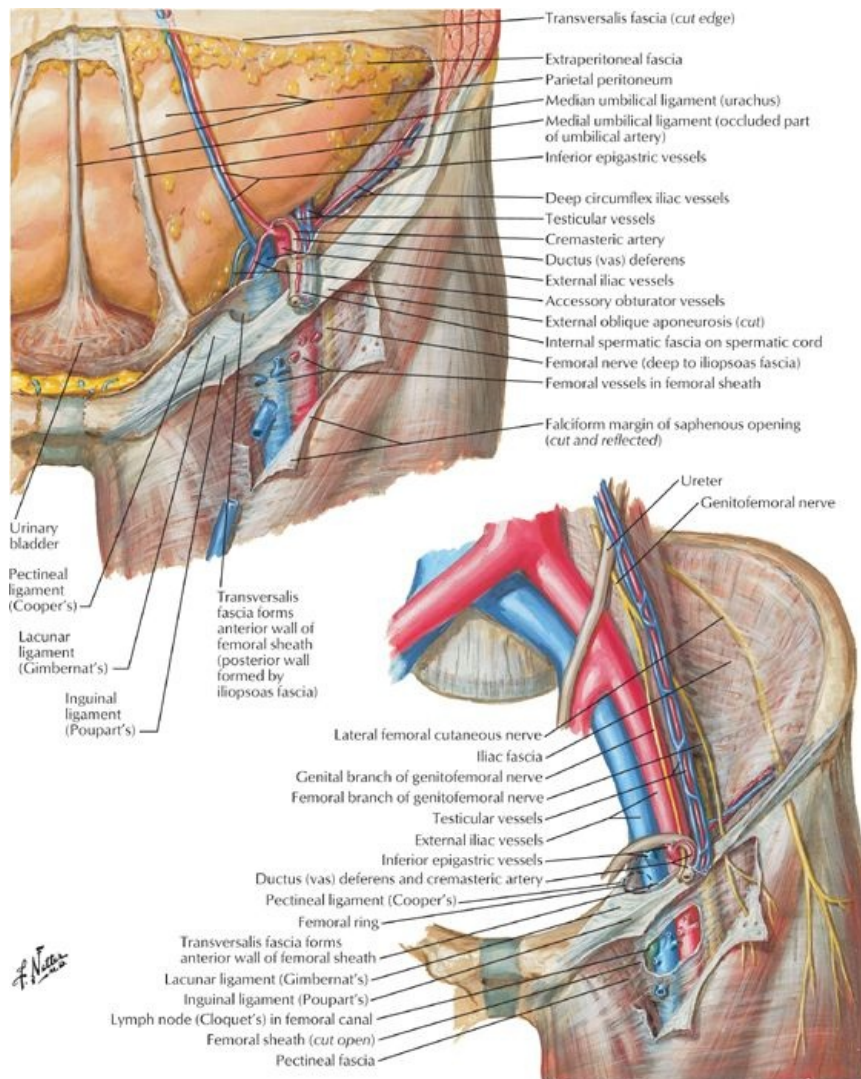
Inguinal canal: A feature of the anterior abdominal wall



[Plate 253, Inguinal Region: Dissections]



[Plate 254, Inguinal Canal and Spermatic Cord]



[Plate 255, Femoral Sheath and Inguinal Canal]

- Oblique canal, approximately 4 cm long at the inferior margin of the anterior abdominal wall
- Parallel and superior to the medial half of the inguinal ligament
- Deep inguinal ring: internal entrance to canal
 - Entrance to the canal through the transversalis fascia.
 - Located 1.25 cm superior to the midpoint of the inguinal ligament
 - Occurs lateral to the epigastric vessels
- Superficial ring: external exit of the canal
 - Exit through the external oblique aponeurosis
 - Located superolateral to the pubic tubercle
- Boundaries:
 - Anterior wall: external oblique aponeurosis (and internal oblique laterally)
 - Posterior wall
 - Transversalis fascia laterally
 - Internal oblique and conjoint tendon (joint insertion of aponeuroses of internal oblique and transverses abdominus) medially
 - Roof: arching fibers of internal oblique
 - Floor: inguinal ligament, reinforced medially by the lacunar ligament
- Contents:
 - Spermatic cord in men
 - Round ligament in women (*Section 5: Pelvis and Perineum*)
 - Ilioinguinal nerve
 - Blood and lymphatic vessels

FACTS & HINTS

High-Yield Facts

Clinical Points

Inguinal Hernia

- Most abdominal hernias occur in the inguinal region
- Most hernias are inguinal hernias
- Inguinal hernias are more common in men
- About 20% are direct inguinal hernias.
- Direct inguinal hernias protrude through the layers of the wall in Hesselbach's (the inguinal) triangle, *medial* to the epigastric vessels.
- The hernial sac consists of peritoneum containing a portion of a viscus (usually small or large bowel)
- Indirect hernias which leave the abdomen *lateral* to the epigastric vessels, entering the inguinal canal through its deep ring.
- The hernial sac consists of peritoneum containing a portion of a viscus (usually small or large bowel) and is covered by the layers covering the spermatic cord.
- The hernia may continue through the superficial ring and into the scrotum.

Clinical Points

Psoas Abscess

- Usually caused by the spread of lumbar vertebral tuberculosis to the psoas sheath.
- The sheath becomes thickened and pus accumulates beneath it
- Pus tracks inferiorly within the sheath, deep to the inguinal ligament, surfacing in the superior part of the thigh.
- Should pus track to the adjacent iliac fascia, a recess may form-the iliacosubfascial fossa.
- The large bowel can become trapped in this fossa, with resulting severe pain.

Mnemonics

Memory Aids

Muscles of the abdominal wall:	TIRE
	Transversus abdominis
	Internal oblique
	Rectus abdominis
	External oblique

26 Peritoneal Cavity

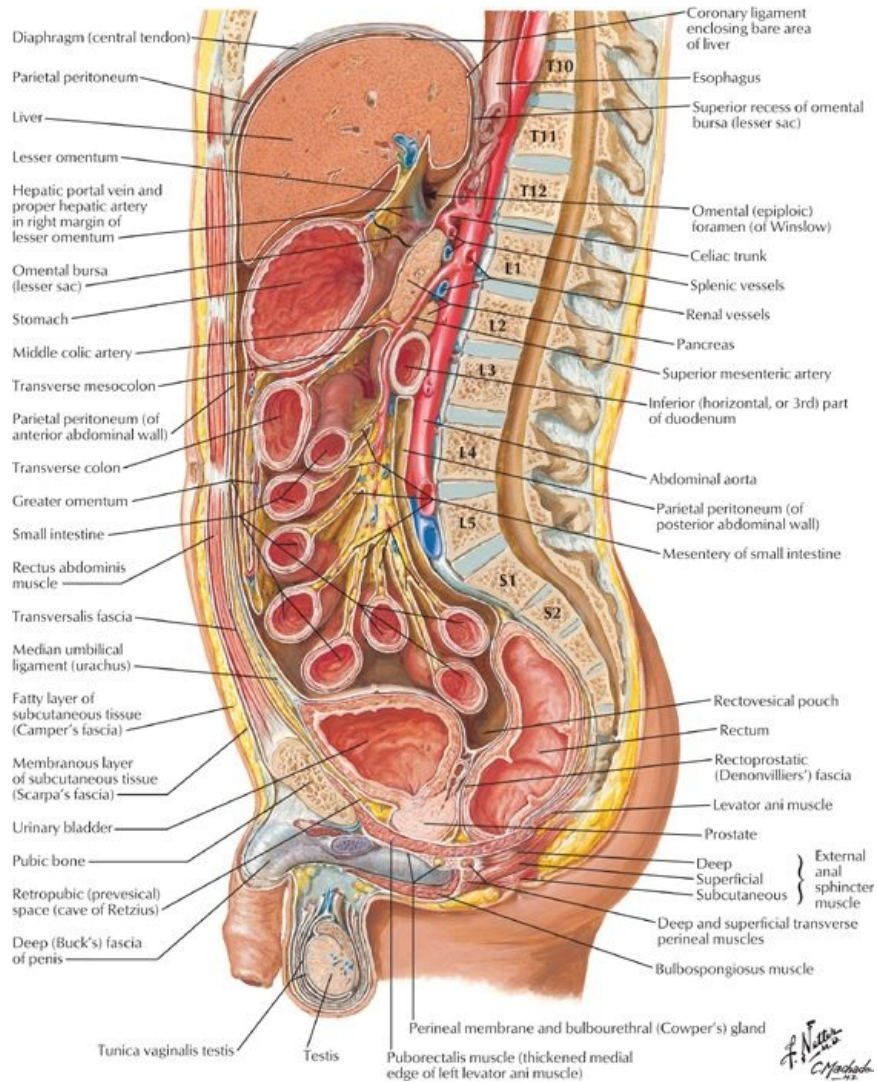
STUDY AIMS

At the end of your study, you should be able to:

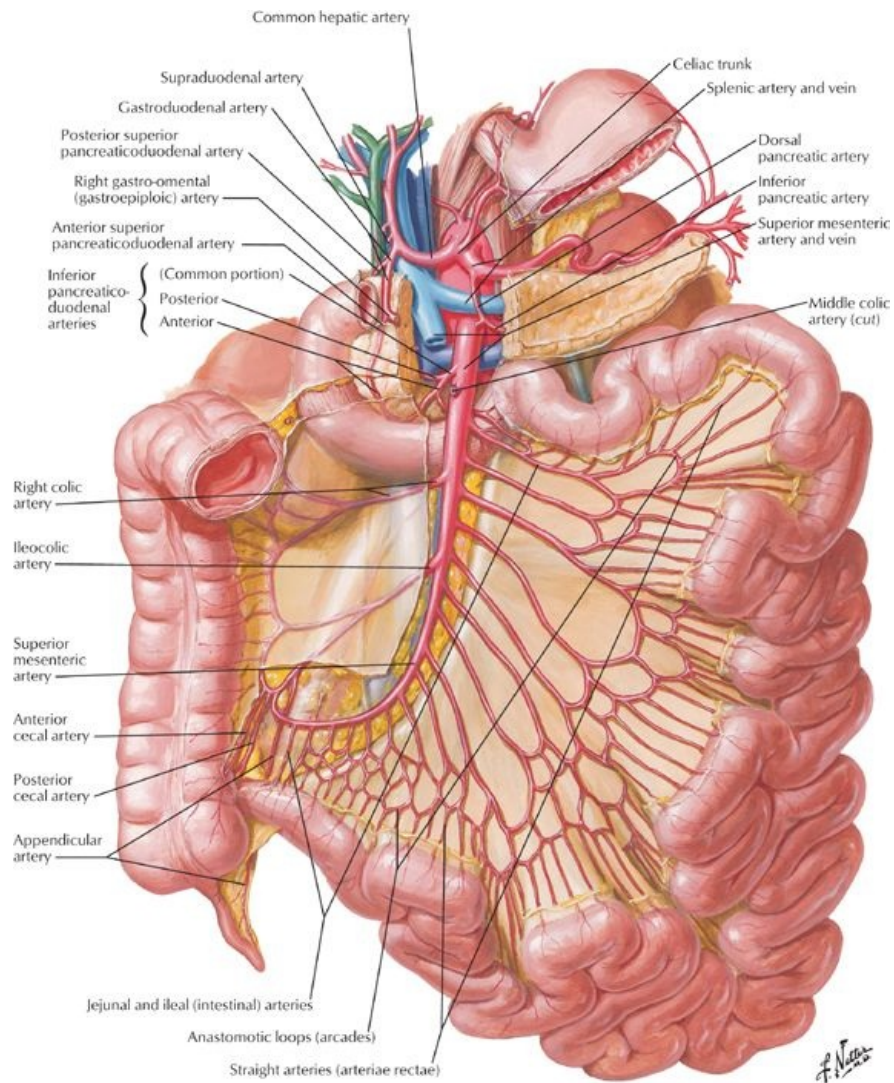
- Understand the difference between the abdominopelvic and peritoneal cavities
- Be able to explain the difference between the greater sac and the lesser sac (omental bursa)
- Understand the organization of the peritoneal folds that form the greater omentum, lesser omentum, the mesentery of the small intestine, and other mesenteries and peritoneal ligaments
- Know which organs are intraperitoneal, retroperitoneal, and secondarily retroperitoneal
- Describe the subdivisions of the peritoneal cavity

GUIDE

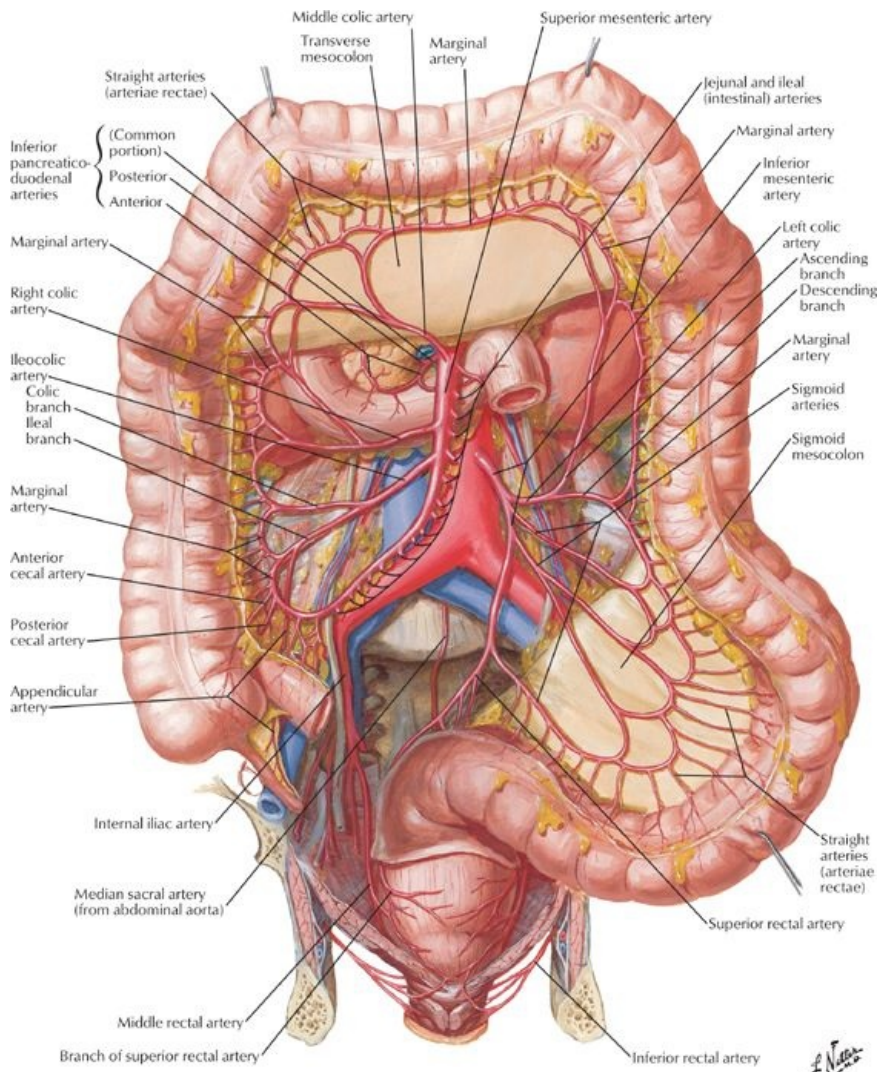
Abdomen: Peritoneal Cavity



[Plate 323, Abdominal Wall and Viscera: Paramedian (Parasagittal) Section]

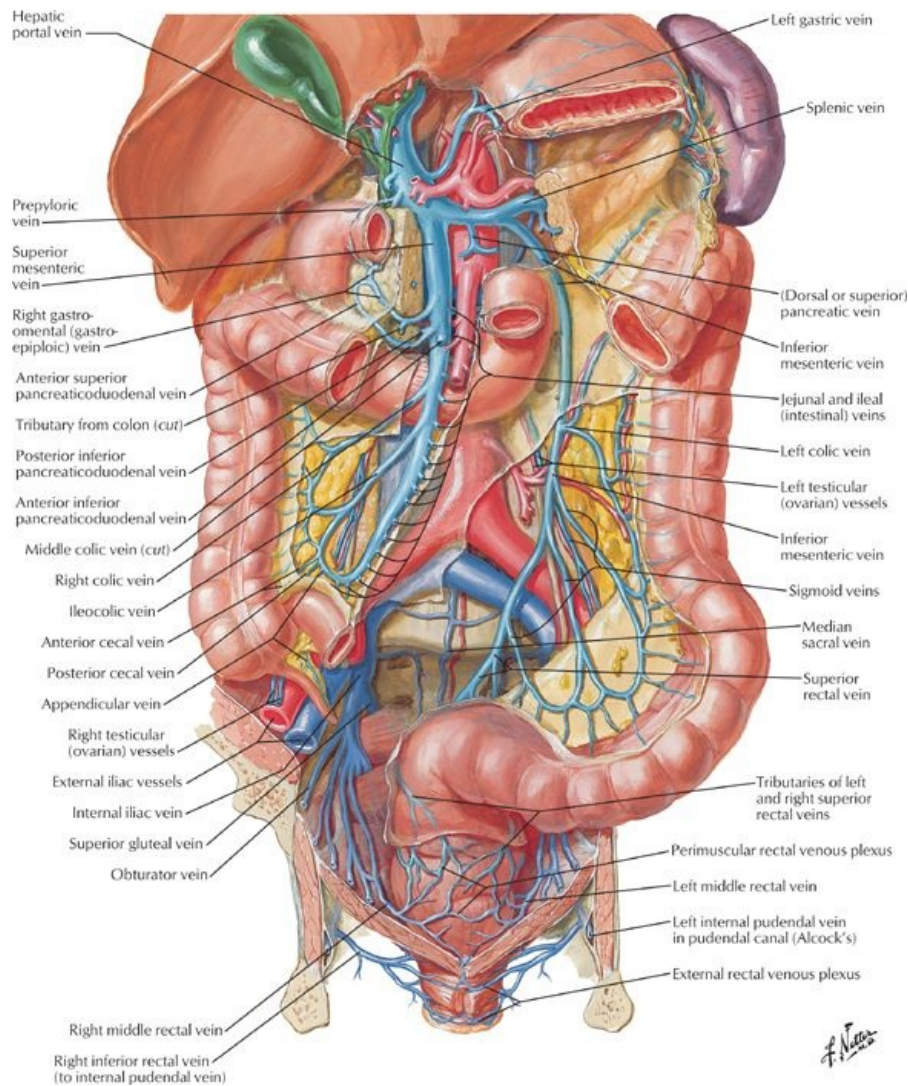


[Plate 287, Arteries of Small Intestine]



[Plate 288, Arteries of Large Intestine]

f. Netter



[Plate 291, Veins of Large Intestine]

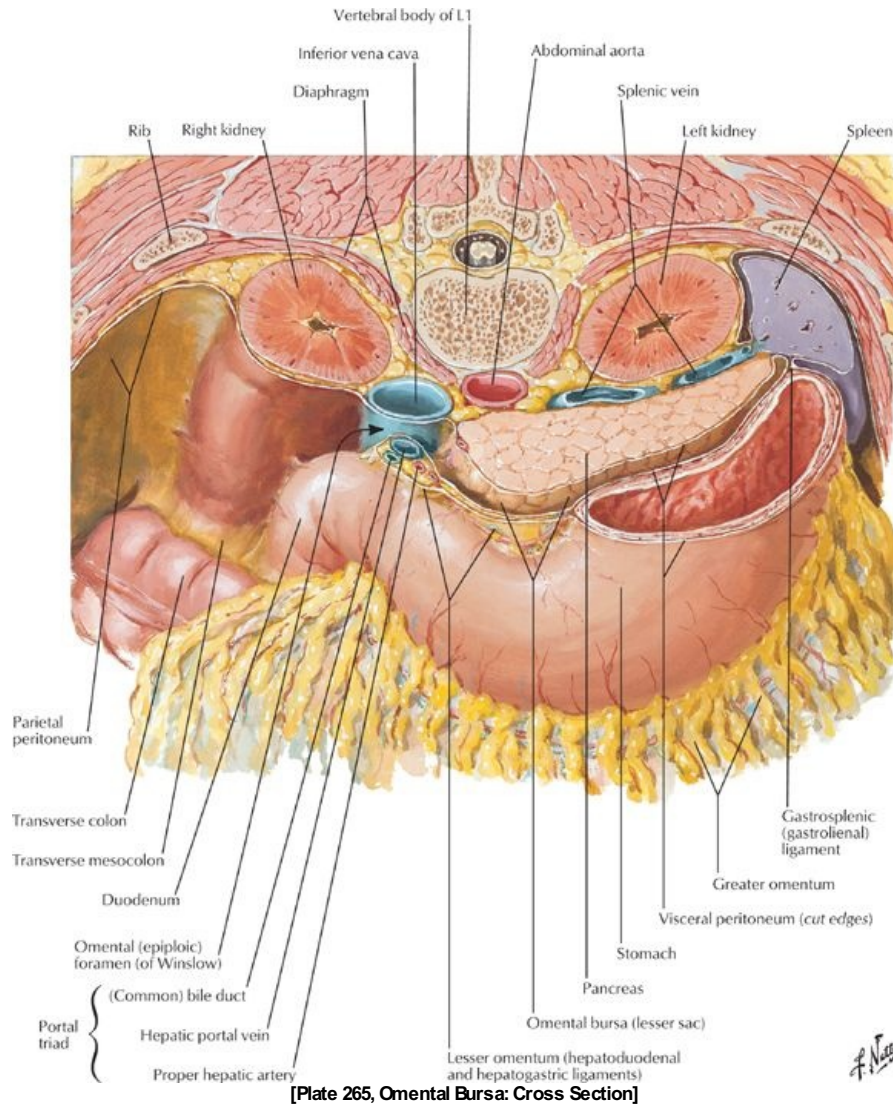
Peritoneum

page 138
page 139

- Serous membrane
 - Lines the abdominopelvic cavity
 - Consists of two continuous layers of mesothelium:
 - Parietal peritoneum
 - Lines the internal abdominal wall
 - Receives its neurovascular supply from the region of the wall it lines
 - Visceral peritoneum
 - Invests abdominal viscera
 - Receives its neurovascular supply from that of organ
- Peritoneal cavity
 - A potential space between the parietal and visceral layers of the peritoneum
 - Contains a thin film of fluid
 - No organs actually lie within this potential space
 - Males: peritoneal cavity is completely closed
 - Females: communicates with exterior of body via uterine tubes, uterus, and vagina
- Intra-peritoneal organs
 - Are organs nearly totally covered by visceral peritoneum
 - Not actually inside the peritoneal cavity, but project into the peritoneal cavity
 - Are covered by peritoneum
 - Are attached to body wall and other organs by mesenteries and ligaments
 - Include:
 - Liver
 - Spleen
 - Stomach
 - First part of duodenum
 - Jejunum
 - Ileum
 - Transverse colon
 - Sigmoid colon

- Superior rectum
- Primarily retroperitoneal organs
 - Organs that develop and remain beneath the parietal peritoneum
 - Only the kidneys
- Secondarily retroperitoneal organs
 - Organs that developed with a short mesentery
 - Become pushed against parietal peritoneum lining the body wall by growth of other organs, primarily the small intestine.
 - Mesentery of organ fuses with parietal peritoneum: fusion fascia
 - Peritoneum covers only its anterior surface, hence, secondarily retroperitoneal
 - Organ can be freed at its lateral edge, along the plane of the fusion fascia
 - Include
 - Adrenal glands
 - Pancreas
 - Parts two through four of the duodenum
 - Ascending and descending colon

Omenta



- Omentum = double-layered fold of peritoneum
- Lesser omentum: connects lesser curve of stomach and proximal duodenum to liver
 - Passes from the stomach and first part of the duodenum to adjacent organs
 - Consists of two parts:
 - Hepatogastric ligament
 - Hepatoduodenal ligament
- Greater omentum
 - Hangs down from the greater curve of the stomach and proximal duodenum
 - Folds back on itself to attach to the transverse colon

Mesenteries

- Mesentery = double layer of peritoneum created by invagination of peritoneum by an organ

- Is the continuity of visceral and parietal peritoneum
- Provides a pathway for neurovascular communication between organ and body wall
- Contains lymph nodes and variable amounts of fat
- The *mesentery* is the mesentery of the small intestine
- The *mesocolon* is the mesentery of the large intestine
 - Transverse mesocolon
 - Sigmoid mesocolon

Peritoneal ligaments

page 139
page 140

- Ligament = double layer of peritoneum connecting an organ to another organ or to the abdominal wall
- Ligaments of the liver:
 - Falciform ligament: from liver to anterior abdominal wall
 - Gastrohepatic ligament
 - From lesser curvature of stomach to liver
 - = a portion of lesser omentum
 - Hepatoduodenal ligament
 - From the liver to the first part of the duodenum
 - = Right, thickened free edge of lesser omentum
 - Contains portal triad (portal vein, hepatic artery, bile duct)
- Ligaments of the stomach
 - Gastrophrenic ligament: from stomach to inferior diaphragmatic surface
 - Gastrosplenic ligament: from stomach to hilum of spleen
 - Gastrocolic ligament: from stomach as the greater omentum to the transverse colon
- Ligaments of the spleen
 - Gastrosplenic: from stomach to hilum of spleen
 - Splenorenal (lienorenal): from spleen to the left kidney
- Phrenicocolic ligament (sustentaculum lienis)
 - From the left hepatic flexure of transverse colon to diaphragm
 - Supports the spleen

Peritoneal subdivisions

- Greater sac: main peritoneal cavity
- Lesser sac (omental bursa)
 - Posterior to the stomach
 - Visible through the lesser omentum
 - Superior recess: limited by the diaphragm and posterior layers of the coronary ligament of the liver (*Section 4-4: Abdomen-Viscera (Gut)*)
 - Inferior recess: potential space between layers of the greater omentum
 - Communicates with the greater sac via the epiploic foramen (of Winslow)

Boundaries of the epiploic foramen

Boundary	Structures
Anterior	Hepatoduodenal ligament containing portal triad
Posterior	Inferior vena cava (IVC) and right crus of diaphragm which is covered by the parietal peritoneum
Superior	Caudate lobe of liver which is covered by the visceral peritoneum
Inferior	First part of duodenum, portal vein, hepatic artery, bile duct

- Supracolic compartment
 - Greater sac above the transverse mesocolon
 - Contains stomach, liver, and spleen
- Infracolic compartment
 - Greater sac below transverse mesocolon,
 - Contains small bowel, ascending and descending colon.
 - Divided into left and right divisions by the mesentery of the small intestine
 - Free communication between the supracolic and infracolic compartments via the paracolic gutter
 - Grooves or recesses between the ascending and descending colon and the posterior abdominal wall along their lateral borders

FACTS & HINTS

High-Yield Facts

Anatomic Points

The **greater omentum** is often referred to as the "abdominal policeman." It can move within the peritoneal cavity and wrap itself around an inflamed organ, localizing inflammation and preventing adhesion between the visceral peritoneum and parietal peritoneum of the abdominal wall.

page 140
page 141

There are several ways to access the omental bursa surgically:

- Directly through the lesser omentum
- Through the transverse mesocolon
- Through the gastrocolic ligament (part of the greater omentum)

Clinical Points

Peritonitis

- Inflammation of the peritoneum
- Can be localized (e.g., secondary to appendicitis) or generalized (e.g., secondary to bowel perforation)
- Can result in reflex tensing ("guarding") of the overlying abdominal musculature leading to abdominal rigidity.
- Involvement of parietal peritoneum leads to well-localized, sharp abdominal pain with tenderness on palpation.

Ascites

- Accumulation of fluid in the peritoneal cavity
- May form secondary to peritonitis or a variety of other pathological conditions
- Abdomen may become grossly distended as many liters of fluid accumulate
- Paracentesis may be undertaken both for diagnostic purposes and for draining the ascitic fluid.
- Usually performed under local anaesthesia.

27 Viscera (Gut)

STUDY AIMS

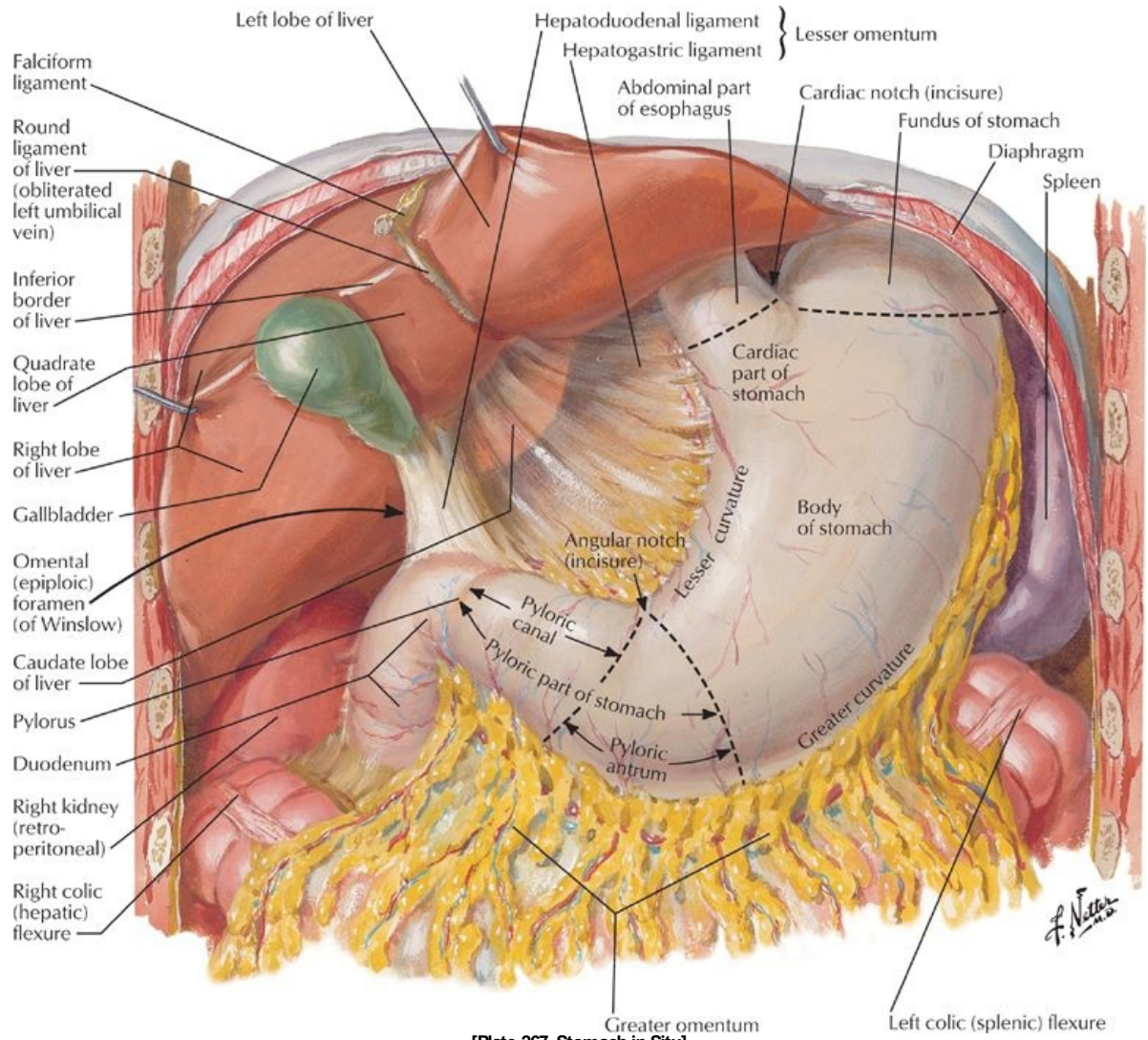
At the end of your study, you should be able to:

- Describe the structure of the stomach and its neurovascular supply
- Describe the structure of the duodenum, its immediate anatomic relationships, and its neurovascular supply
- Understand the orientation of the small bowel within the abdomen and describe its divisions and neurovascular supply
- Understand the course of the large bowel within the abdomen and describe its divisions and neurovascular supply
- List distinguishing features of the jejunum, ileum, and large intestine

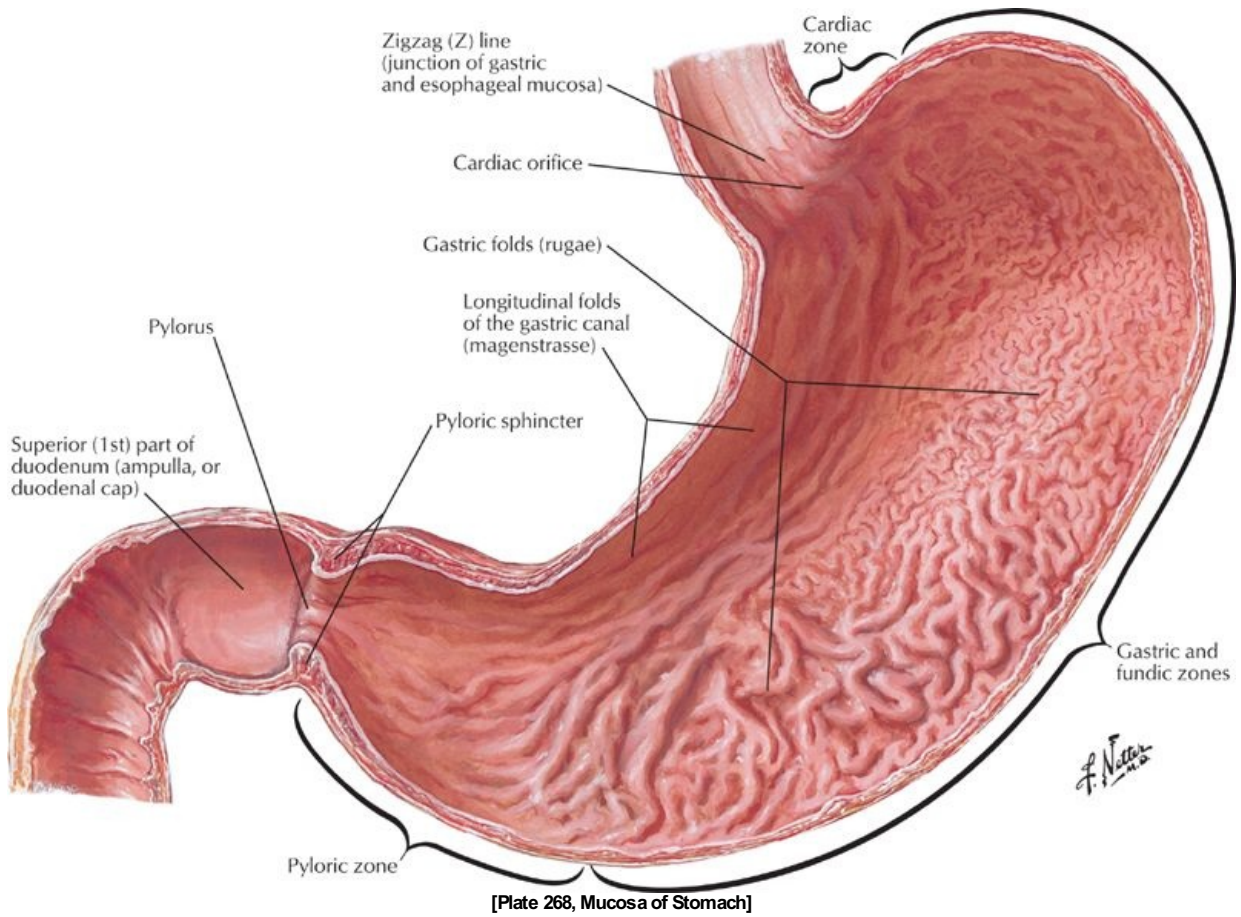
GUIDE

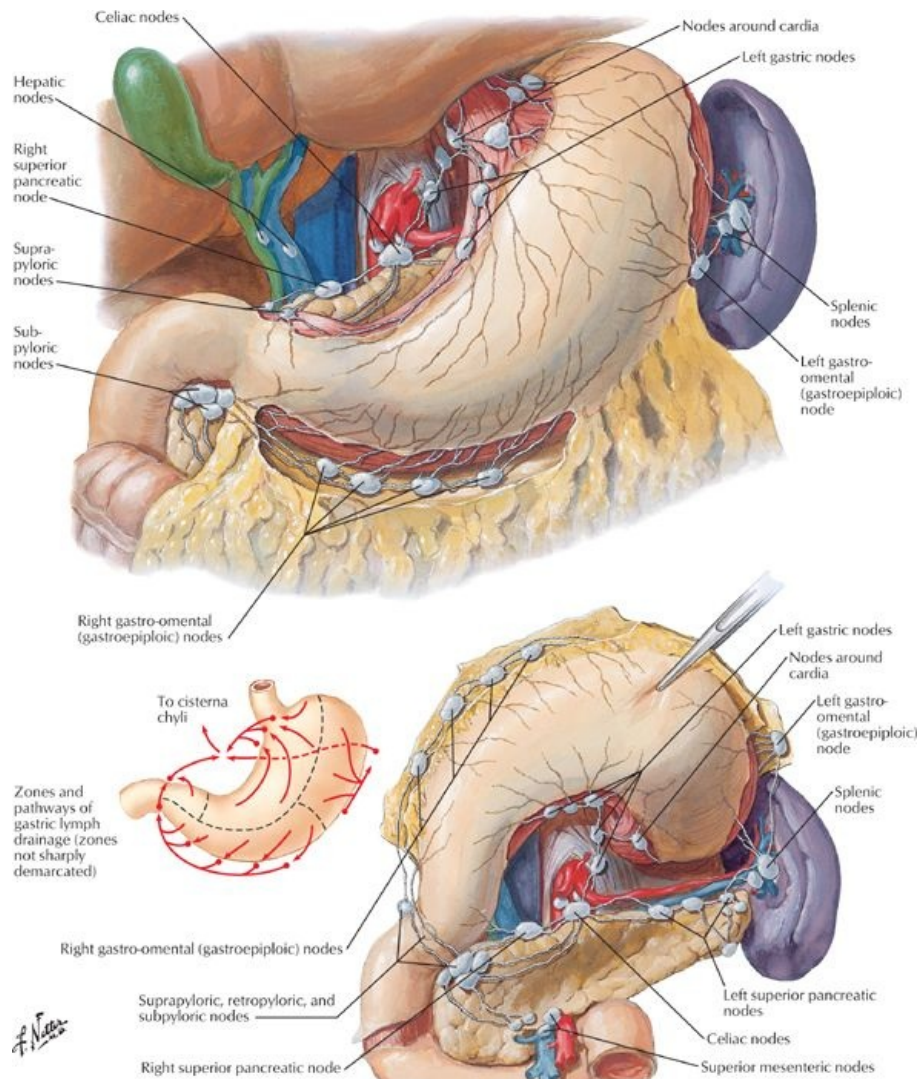
Abdomen: Viscera (Gut)

Stomach



[Plate 267, Stomach in Situ]





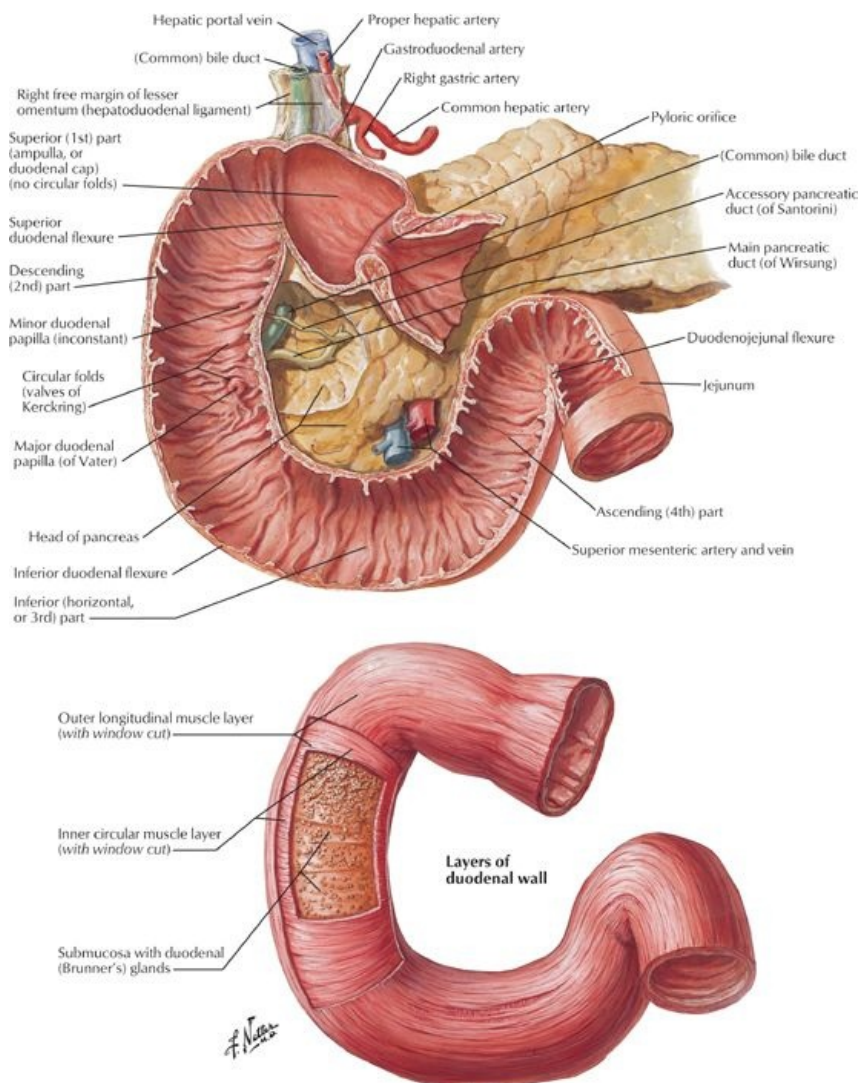
[Plate 293, Lymph Vessels and Nodes of Stomach]

page 142
page 143

- J-shaped enlargement of the gastrointestinal tract
- Chief function: enzymatic digestion
 - Acidic gastric secretions convert food into liquid *chime*
 - Passes fairly quickly into the duodenum
- Parts of the stomach
 - Greater curvature: long, convex border
 - Lesser curvature: short, concave border
 - Cardia: surrounds cardiac (esophageal) orifice
 - Fundus: dilated upper part
 - Above the level of the esophageal orifice
 - Dilated by fluid, food, but mainly gas
 - Separated from esophagus by cardiac notch
 - Body: between fundus and pyloric antrum
 - Pyloric part
 - Begins at level of angular incisure: indentation two thirds of the way along the lesser curvature
 - Widest region: pyloric antrum
 - Antrum leads to pyloric canal
 - Pylorus: surrounds pyloric orifice
 - Pyloric sphincter
 - a. Thick, circular middle layer of muscularis externa
 - b. Controls passage of chime into duodenum
 - c. Normally closed in tonic contraction, except during peristalsis
- Three muscle layers: outer longitudinal, inner circular, and innermost oblique
- Internal surface thrown into numerous longitudinal folds-rugae
 - Gastric canal = longitudinal fold along lesser curvature
 - Forms during swallowing
 - Accommodates the passage of liquid
- Covered by peritoneum except where blood vessels run over it, and over a small area posterior to the cardiac orifice
 - Double layer of peritoneum extends between stomach and liver and duodenum and liver: lesser omentum
 - Two layers of lesser omentum wrap around stomach and leave greater curvature as great omentum

- Vascular supply (*Section 4-6: Abdomen-Visceral Vasculature*)
 - Arteries
 - Left gastric from celiac trunk
 - Right gastric from common hepatic artery
 - Right gastroepiploic (gastro-omental) from proper hepatic or gastroduodenal arteries
 - Left gastroepiploic from splenic artery
 - Short gastric arteries (four to five) from distal splenic artery
 - Veins
 - Follow the arteries
 - Right and left gastrics drain to portal vein
 - Short gastrics and left gastroepiploic drain into splenic vein → superior mesenteric vein (SMV) → portal vein
 - Right gastroepiploic drains to SMV
 - Lymphatics
 - Follow the arteries
 - Drain into gastric, gastroepiploic, pancreaticosplenic, and pyloric nodes
- Innervation (*Section 4-7: Abdomen-Innervation*)
 - Parasympathetic supply
 - From anterior and posterior vagal trunks
 - Increase peristalsis and relax pyloric sphincter
 - Sympathetic supply
 - From T6-T9 spinal cord segments via great splanchnic nerve to celiac plexus
 - Inhibit peristalsis and contract pyloric sphincter

Duodenum



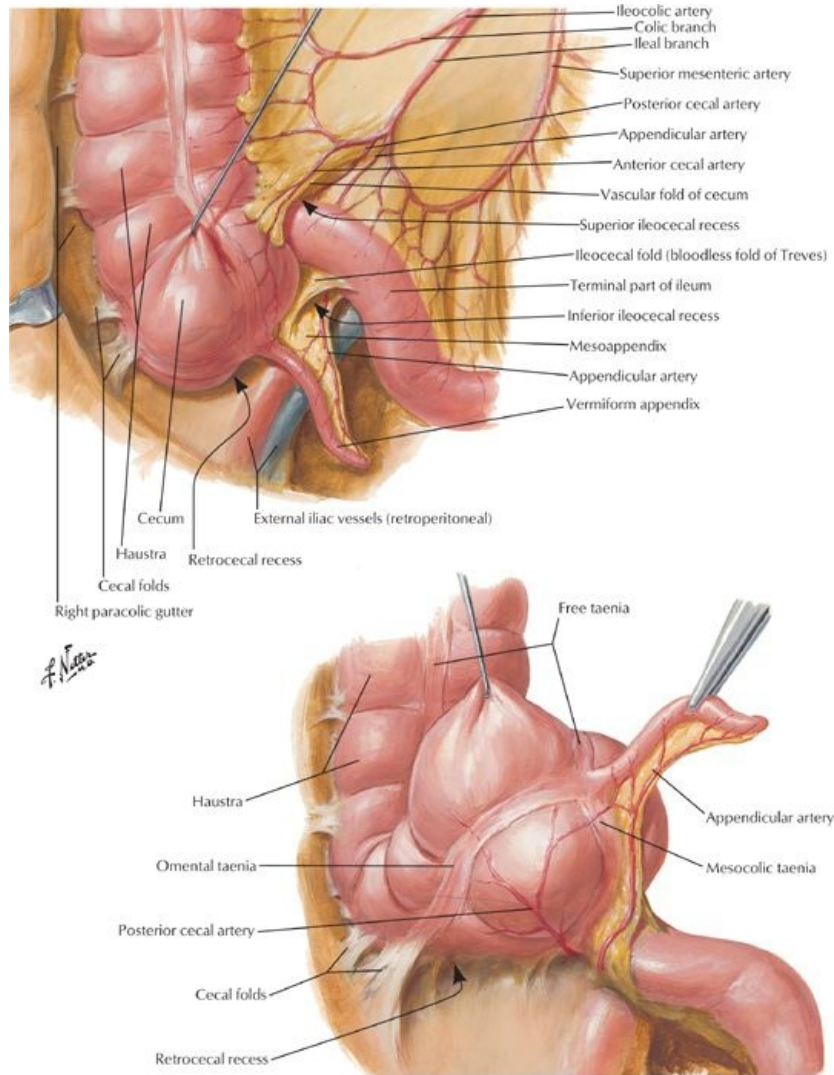
[Plate 271, Mucosa and Musculature of Duodenum]

page 143
page 144

- First and shortest part of small intestine
- Follows a C-shaped course around the head of the pancreas
- Consists of four parts (*parts 2 through 4 are retroperitoneal*)
 - Superior (first) part: anterolateral to body of L1
 - Ascends from pylorus

- Is connected to liver by hepatoduodenal ligament (part of lesser omentum)
 - Portal vein, bile duct, and IVC located posteriorly
 - Descending (second) part
 - Descends along the right of L1-L3
 - Contains major duodenal papilla on posteromedial wall = opening of hepatopancreatic ampulla
 - Horizontal (third) part
 - Crosses inferior vena cava (IVC), aorta, and L3 vertebra
 - Is crossed by superior mesenteric artery (SMA) and SMV and root of mesentery
 - Ascending (fourth) part
 - Ascends to L2 on the left side
 - Curves anteriorly at the duodenojejunal flexure
 - Flexure is supported by the ligament of Treitz
- Vascular supply (Section 4-6: Abdomen-Visceral Vasculature)
 - Arteries
 - Gastroduodenal artery, branch of common hepatic → superior anterior and posterior pancreaticoduodenal arteries
 - SMA → anterior and posterior inferior pancreaticoduodenal arteries
 - Important anastomoses between celiac trunk and SMA via duodenal arteries
 - Veins
 - Follow the arteries
 - Drain directly or indirectly into the portal vein
 - Lymphatics
 - Follow the arteries
 - Drain into pancreaticoduodenal, pyloric, superior mesenteric, and celiac lymph nodes
- Innervation (Section 4-7: Abdomen-Innervation)
 - Parasympathetic supply from the vagus via celiac and superior mesenteric plexuses
 - Sympathetic supply via celiac and superior mesenteric plexuses, traveling on pancreaticoduodenal arteries

Jejunum and ileum

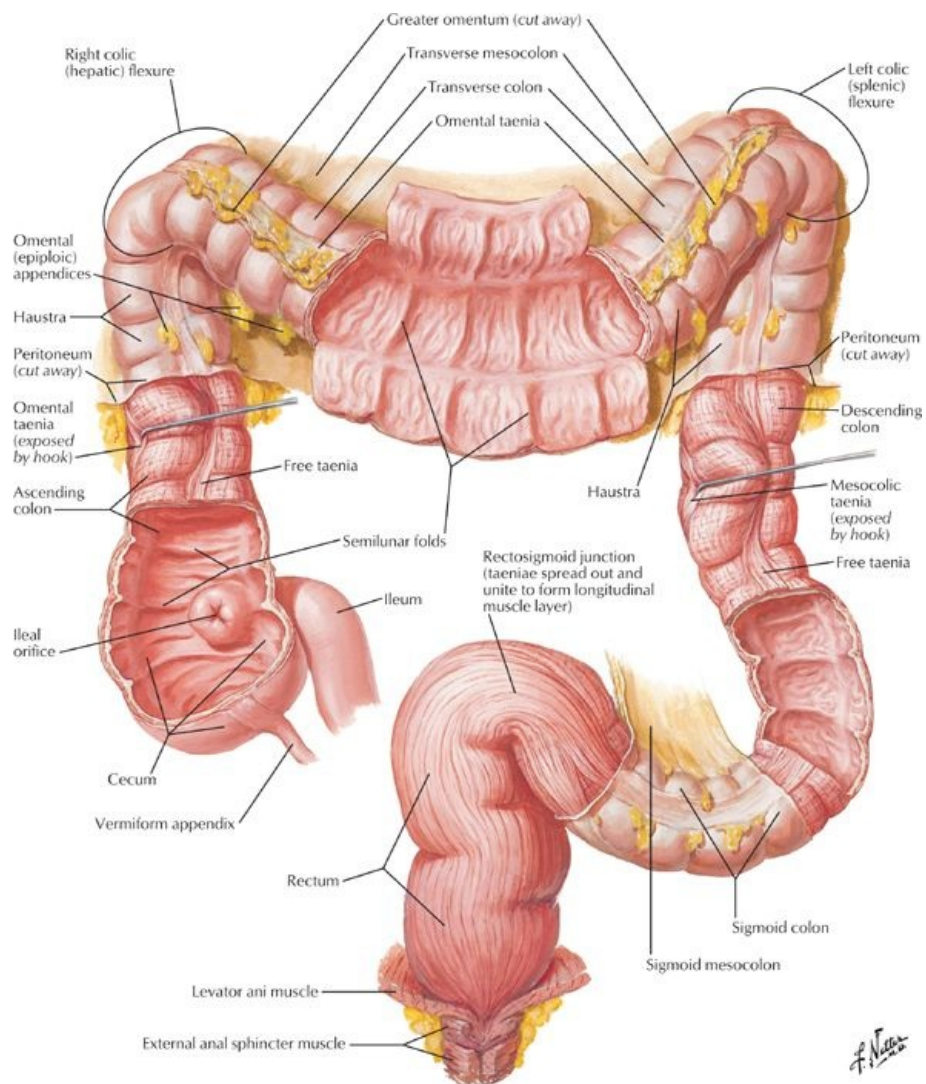


[Plate 273, Ileocecal Region]

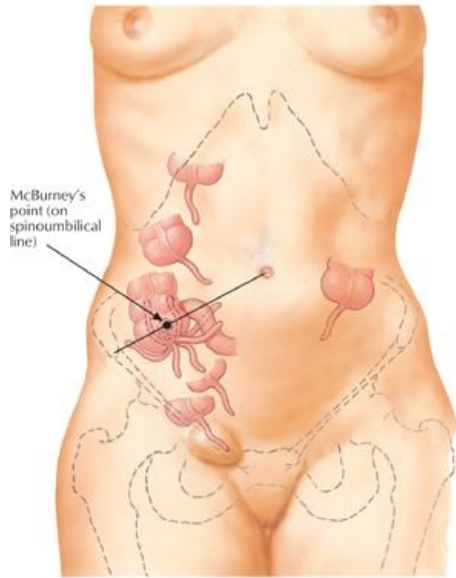
- Begins at duodenojejunal junction and ends at ileocecal junction

- Together are approximately 6 m long
- The mesentery
 - Double layered fold of peritoneum
 - Attaches jejunum and ileum to posterior abdominal wall
 - Root of mesentery
 - Follows an oblique line
 - Runs inferiorly and to the right, from ligament of Treitz to ileocolic junction
 - Between two layers are SMA, SMM, lymph nodes, fat, and autonomic nerves
- Jejunum
 - Approximately two fifths of the length
 - Mainly in the left upper quadrant (LUQ)
 - Thick-walled and very vascular
- Ileum
 - Approximately three fifths of the length
 - Mainly in the right lower quadrant (RLQ)
 - Thin-walled and less vascular
 - Terminates at the ileocecal junction
- Vascular supply (*Section 4-6: Abdomen-Visceral Vasculature*)
 - Arteries
 - Superior mesenteric artery
 - Fifteen to 18 branches from SMA to jejunum and ileum
 - Branches unite to form loops or arches (arterial arcades)
 - Arcades give rise to straight arteries = vasa recta
 - Double row of arcades to ileum
 - Veins
 - SMM drains ileum and jejunum
 - Posterior to neck of pancreas joins splenic vein to form portal vein
 - Lymphatics
 - Specialised lymphatic vessels that absorb fat = lacteals
 - Absorbed fat = chyle
 - Lacteals found in villi (finger-like projections of intestinal mucosa)
 - Lacteals drain to lymphatic plexuses in walls of jejunum and ileum
 - Lymphatics pass between the layers of the mesentery to mesenteric lymph nodes and then to superior mesenteric or ileocolic nodes
 - Lymph drains to cisterna chyli
- Innervation (*Section 4-7: Abdomen-Innervation*)
 - Parasympathetic supply
 - Preganglionic fibers from the posterior vagal trunks
 - Synapse on postganglionic cells in myenteric and submucosal plexuses in intestinal wall
 - Sympathetic supply
 - Preganglionic fibers from T5-T9 spinal cord segments → sympathetic trunks → greater and lesser splanchnic nerves
 - Synapse on postganglionic cells in celiac and superior mesenteric ganglia

Large intestine (colon)

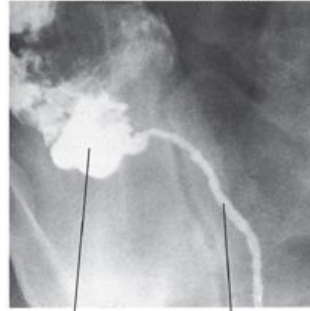

[Plate 276, Mucosa and Musculature of Large Intestine]

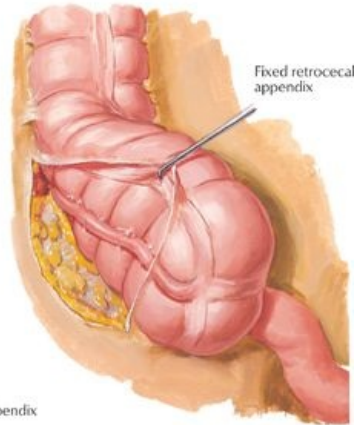


Variations in position of appendix

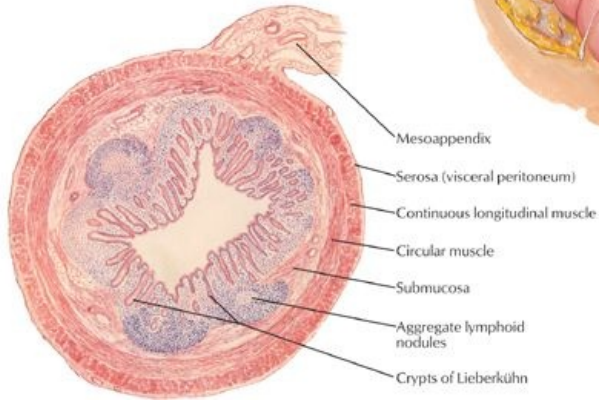
Barium radiograph of unusually long appendix



Cecum Appendix

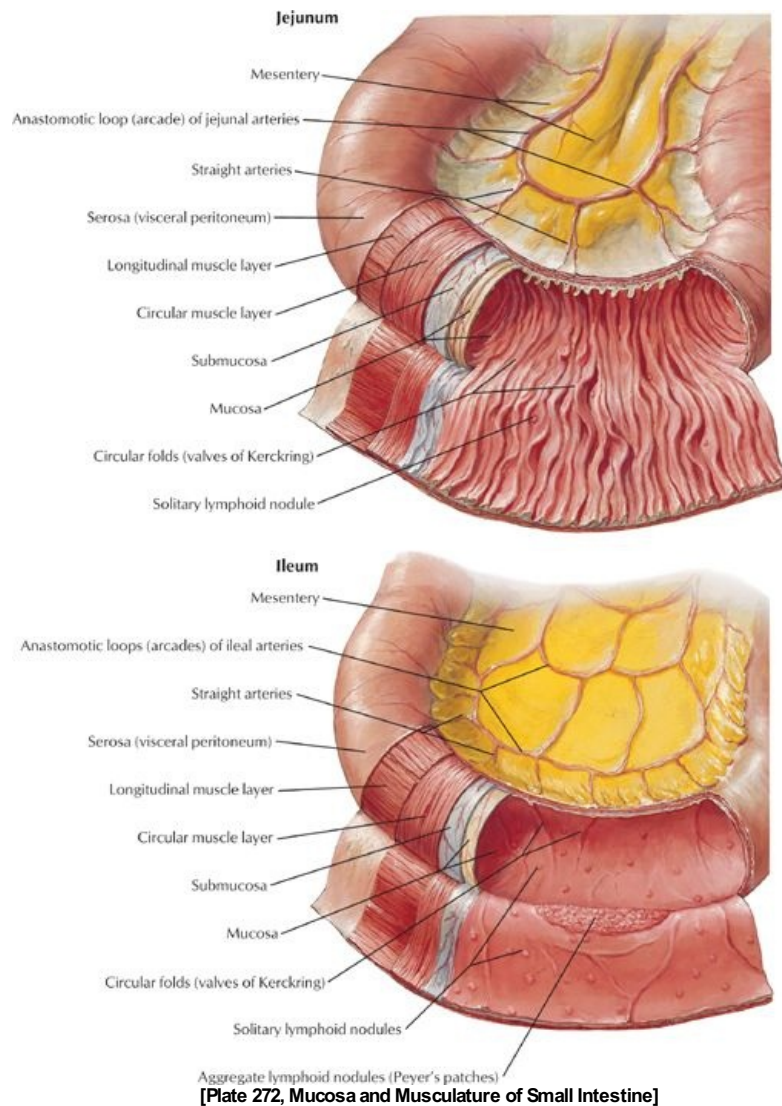


Fixed retrocecal appendix



[Plate 275, (Vermiform) Appendix]

Handwritten signature



page 145
page 146

- Characterized by:
 - Teniae coli: 3 thickened longitudinal bands of muscle (*absent from appendix and rectum*)
 - Haustra: sacculations of the colon caused by teniae coli
 - Appendices epiploicae: fatty lobules of omentum
- Cecum
 - Blind pouch, approximately 7.5 cm in diameter
 - No mesentery, but may be bound to the abdominal wall by cecal folds of peritoneum
 - Invaginated by ileum to form the ileocecal valve-does not prevent reflux
 - Vermiform appendix
 - Arises from the posteromedial side of cecum
 - Usually retrocecal
 - Has a short mesentery from cecum: mesoappendix
 - Supplied by appendicular artery from ileocolic artery
 - Vascular supply: ileocolic artery and vein, with lymph to ileocolic nodes
 - Nerves: sympathetic and parasympathetic nerves from the superior mesenteric plexus
 - Parasympathetic fibers from vagus nerves
 - Sympathetic fibers from lower thoracic spinal cord segments
- Ascending colon
 - On right side of posterior abdominal wall
 - Extends from cecum to liver, where it turns at right colic flexure (hepatic flexure)
 - Is secondarily retroperitoneal
 - Vascular supply from branches/tributaries of SMA/SMV
 - Ileocolic artery and vein
 - Right colic artery and vein
 - Lymphatics to epicolic and paracolic nodes
 - Nerve supply from the superior mesenteric plexus
- Transverse colon
 - Extends from hepatic flexure on the right to splenic flexure on the left
 - Largest and most mobile section of colon
 - Attached to posterior abdominal wall by its mesentery: the transverse mesocolon

- Vascular supply from branches/tributaries of SMA/SMV
 - Left colic artery and vein
 - Right colic artery and vein
 - Middle colic artery and vein
- Lymphatic drainage to middle colic nodes
- Nerve supply
 - Superior mesenteric plexus along right and middle colic arteries
 - Inferior mesenteric plexus along left colic arteries
- Descending colon
 - On left side of posterior abdominal wall
 - Extends from splenic flexure to sigmoid colon
 - Is secondarily retroperitoneal
 - May have a short mesentery in one third of people
 - Vascular supply from branches/tributaries of IMA/IMV
 - Left colic artery and vein
 - Superior sigmoid artery and vein
 - Lymphatic drainage to the epicolic and paracolic nodes
 - Innervation
 - Sympathetic fibers from the lumbar sympathetic trunk and superior hypogastric plexus
 - Parasympathetic fibers from the pelvic splanchnic nerves
- Sigmoid colon
 - S-shaped loop of variable length
 - Links descending colon with rectum
 - Long mesentery with a V-shaped root: sigmoid mesocolon
 - Vascular supply from branches/tributaries of inferior mesenteric artery (IMA)/inferior mesenteric vein (IMV)
 - Left colic artery and vein
 - Superior sigmoid artery and vein
 - Lymphatic drainage to the epicolic and paracolic nodes
 - Innervation
 - Sympathetic fibers from the lumbar sympathetic trunk and superior hypogastric plexus
 - Parasympathetic fibers from the pelvic splanchnic nerves
- Rectum and anal canal (*Section 5-9: Pelvis and Perineum-Rectum and Anal Canal*)
 - Rectum
 - Begins anterior to the body of the S3 vertebra
 - Is approximately 15 cm long
 - Connects sigmoid colon and anal canal
 - Fixed, and continuous with the anal canal
 - Anal canal
 - Begins at distal end of rectal ampulla
 - Extends from pelvic diaphragm to anus

FACTS & HINTS

High-Yield Facts

Clinical Points

page 146
page 147

Hiatus hernia

- Herniation of part of the stomach through the esophageal hiatus of the diaphragm
- May cause pain and discomfort and predispose to reflux of gastric contents
- Sliding hernias involve the cardia of the stomach sliding superiorly
- Rolling hernias (less common) involve part of the fundus extending through the hiatus

Congenital hypertrophic pyloric stenosis

- Thickening of smooth muscle of the pylorus
- Causes severe stenosis of the pyloric canal
- Gastric emptying is greatly reduced and typically leads to the presentation of projectile vomiting following a feeding
- More common in males, and usually presents 3 to 8 weeks after birth
- Diagnosis made by palpating a pyloric mass in the right upper quadrant (RUQ) during a test feeding

Intestinal volvulus

- Rotation of a loop of bowel upon its mesentery
- May cause acute bowel obstruction
- Can compromise the vascular supply leading to ischaemia, infarction, and eventually necrosis
- Most commonly occurs in the mobile small bowel, but may also affect the sigmoid colon, owing to the length of its mesentery
- Prompt surgical decompression may be required, although passage of a flatus tube is usually sufficient in cases of sigmoid volvulus

Mnemonics

Memory Aids

Stomach Parts:	"The CAR is FUN 'til the BODY PILES	
	This relates to the four parts of the stomach:	
	CAR	Cardiac
	FUN	Fundus
	BODY	Body
	PILES*	Pylorus

*The pylorus is where the food piles waiting for the sphincter to open

Memory Aids

Bowel segments:	Dow Jones Industrial Averages Closing Stock Report
Dow	Duodenum
Jones	Jejunum
Industrial	Ileum
Averages	Appendix (attached to cecum)
Closing	Colon
Stock	Sigmoid
Report	Rectum

Memory Aids

Sphincters of the gastrointestinal tract:	APE OIL
A	Anal
P	Pyloric
E	Esophageal (lower)
O	Oddi
IL	Ileocecal

28 Viscera (Accessory Organs)

STUDY AIMS

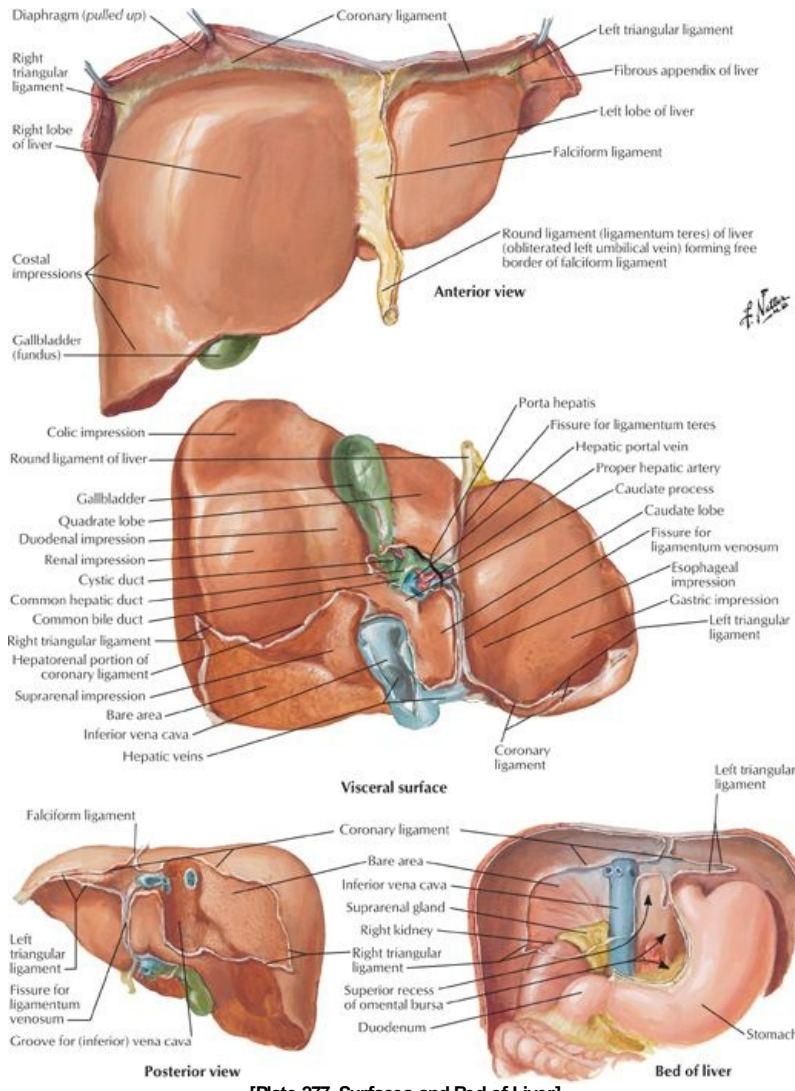
At the end of your study, you should be able to:

- Describe the structure of the liver, its relations, and neurovascular supply
- Describe the structure of the gallbladder, its neurovascular supply, and understand the biliary system
- Describe the structure of the pancreas, its relations, and neurovascular supply
- Describe the structure of the spleen, its relations, and neurovascular supply

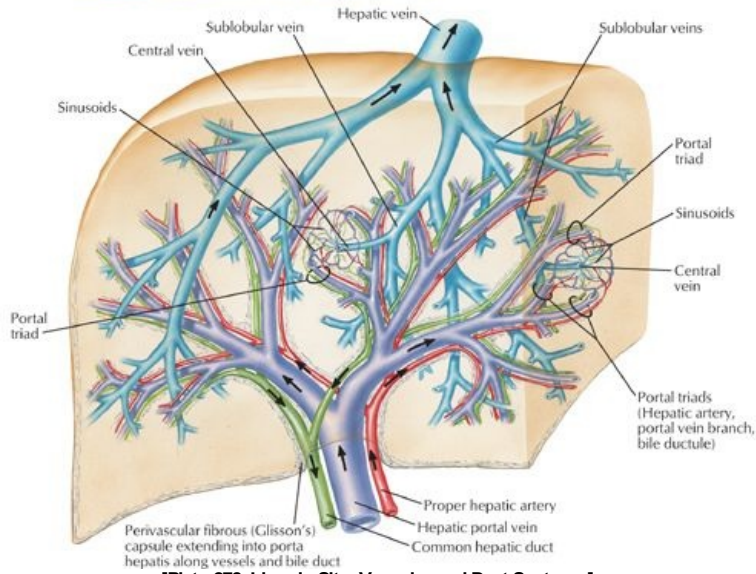
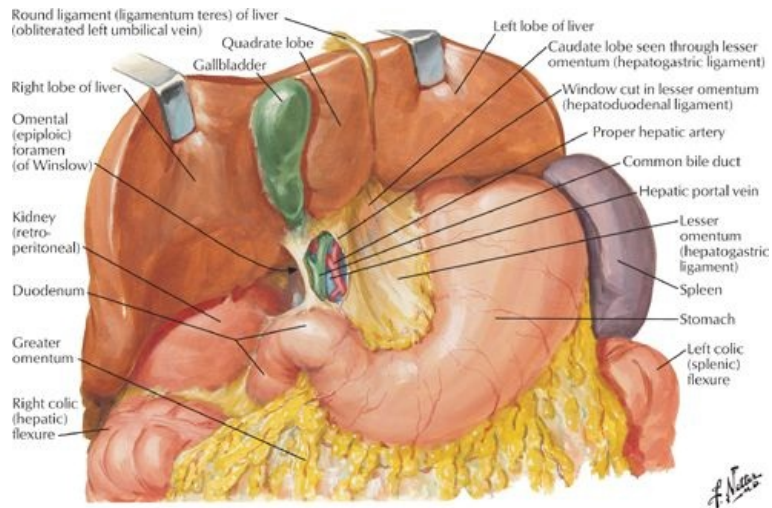
GUIDE

Abdomen: Viscera (Accessory Organs)

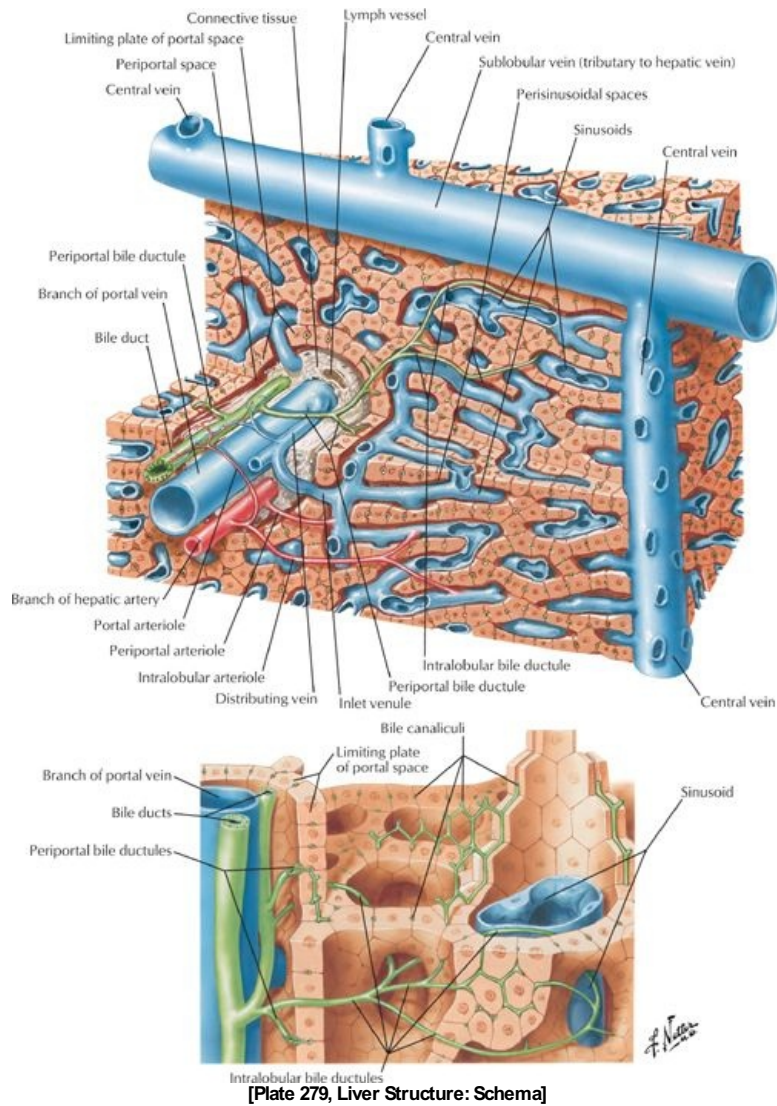
Liver



[Plate 277, Surfaces and Bed of Liver]



[Plate 278, Liver in Situ: Vascular and Duct Systems]



[Plate 279, Liver Structure: Schema]

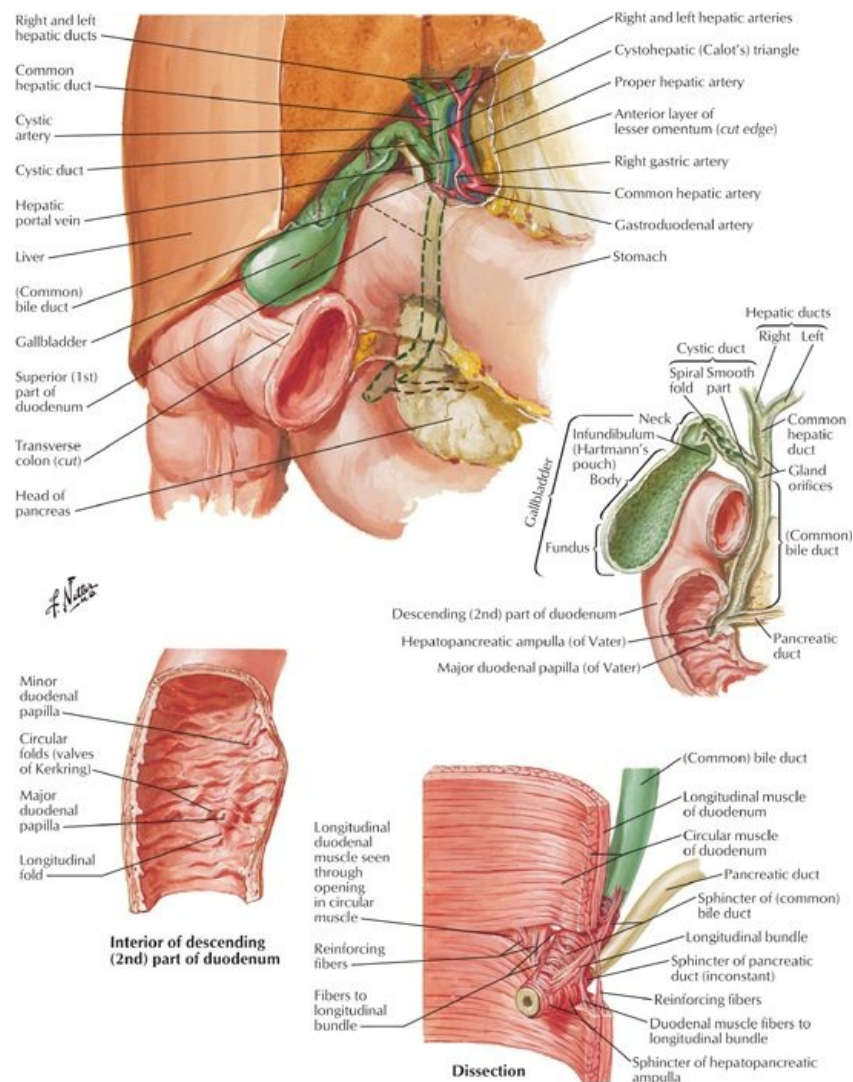
page 148
page 149

Largest gland in the body (approximately 1.5 kg)

- Surfaces
 - Smooth diaphragmatic surface, covered by peritoneum except over bare area
 - Reflection of peritoneum from the diaphragm to liver forms the coronary ligament
 - Has anterior and posterior layers
 - Where layers meet on right = right triangular ligament
 - Posterior layer is continuous with lesser omentum
 - Left triangular ligament formed by the falciform ligament and lesser omentum
 - Visceral surface
 - Separated anteriorly from anterior and superior surfaces by sharp inferior border
 - Covered by peritoneum except at the porta hepatis and bed of the gall bladder
 - Related to: Right side of anterior stomach
 - First part of duodenum
 - Gall bladder
 - Right colic flexure and transverse colon
 - Right kidney and suprarenal glands
- Ligaments
 - Falciform ligament
 - Peritoneal reflection from upper anterior abdominal wall from umbilicus to liver
 - Has ligamentum teres hepatis (round ligament) in free edge
 - Ligamentum teres hepatis (round ligament of liver)
 - Fibrous remnant of umbilical vein
 - Extended from umbilicus to liver
 - Ligamentum venosum
 - Remnant of the ductus venosus
 - Extended in fetus between the umbilical vein and inferior vena cava (IVC)
- Recesses:
 - Subphrenic recess separates liver from diaphragm (split by falciform ligament)
 - Hepatorenal recess
 - On the right side

- Separates liver anteriorly from kidney and suprarenal gland posteriorly
- Lobes
 - Left, right, caudate, quadrate
 - Functional "left liver" includes left lobe, caudate and quadrate lobes
- Porta hepatis
 - Transverse fissure on visceral surface between caudate and quadrate lobes
 - Provides entrance/exit for:
 - Portal vein
 - Hepatic artery
 - Hepatic nerve plexus
 - Hepatic ducts (left and right converge to form the common hepatic duct)
 - Lymphatic vessels
- Vascular supply (*Section 4-6: Abdomen-Visceral Vasculature*)
 - Liver receives blood from
 - Portal vein (70%)
 - Hepatic artery (30%)
 - Hepatic veins (3)
 - Formed by union of central veins
 - Drain directly into the IVC inferior to diaphragm
 - Lymphatics
 - Drain mainly to the hepatic nodes at the porta hepatis
 - From hepatic nodes → celiac nodes → cisterna chyli
- Nervous supply (*Section 4-7: Abdomen-Innervation*) is derived from the hepatic nerve plexus
 - Accompanies branches of hepatic artery and portal vein
 - Sympathetic fibers from celiac plexus
 - Parasympathetic fibers from anterior and posterior vagal trunks
 - Role unknown except for vasoconstriction

Gallbladder

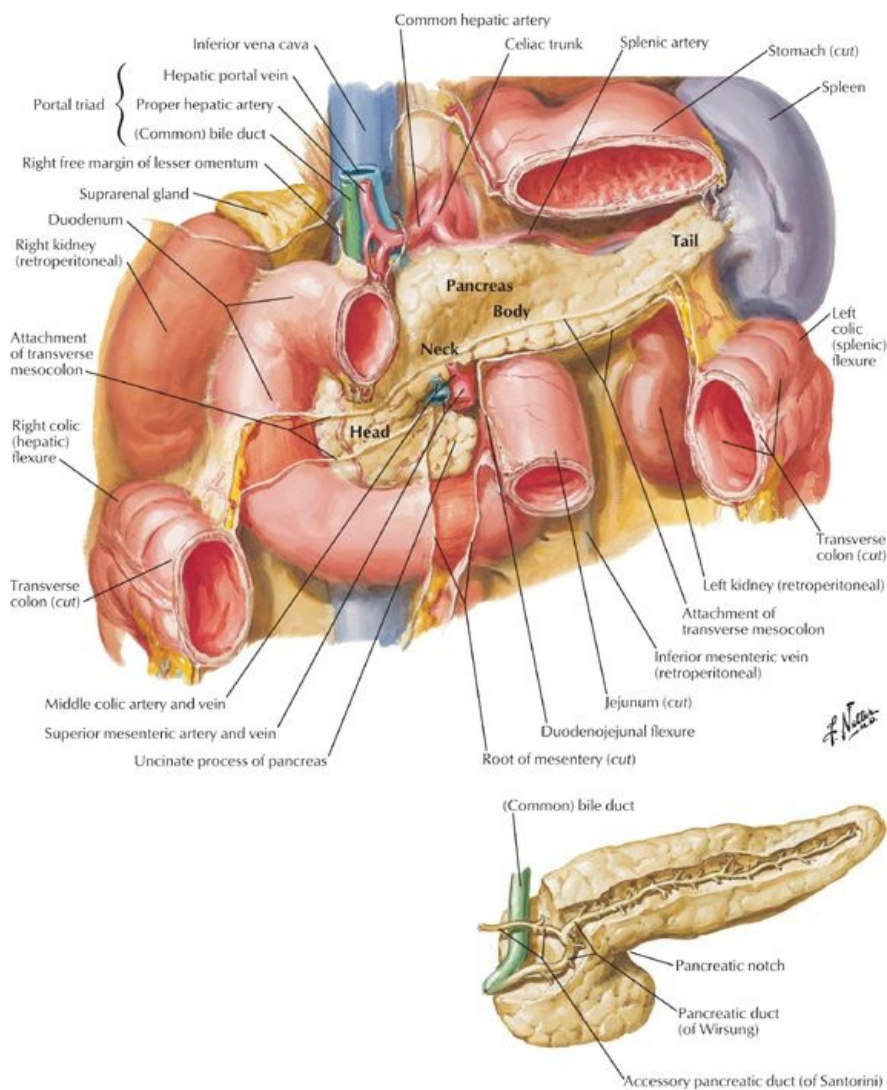


[Plate 280, Gallbladder, Extrahepatic Bile Ducts, and Pancreatic Duct]

- Lies in fossa at junction of right and left lobes of liver
- Connected to liver by fibrous capsule of liver

- Stores bile produced by the liver
- Parts
 - Fundus-located at tip of ninth costal cartilage
 - Body-also in contact with transverse colon and first part of duodenum
 - Neck
 - Has S-shaped bend to joint cystic duct
 - Mucosa thrown into a spiral fold-the *spiral valve*-to keep cystic duct open
 - Cystic duct connects to common hepatic duct to form the common bile duct
- Vascular supply (*Section 4-6: Abdomen-Visceral Vasculature*)
 - Artery: cystic artery from right hepatic artery
 - Cystic veins
 - Veins draining neck and biliary ducts empty into portal vein
 - Veins draining the body and fundus drain directly into the liver
 - Lymph drains to the hepatic nodes
- Nervous supply (*Section 4-7: Abdomen-Innervation*)
 - Sympathetic from celiac plexus
 - Parasympathetic from vagus
 - Sensory from right phrenic

Pancreas



[Plate 281, Pancreas in Situ]

- Lies retroperitoneally and transversely across posterior abdominal wall
- Digestive gland with exocrine and endocrine functions
 - Exocrine: secretion of digestive juices
 - Endocrine: secretion of insulin and glucagon
- Parts:
 - Head
 - Encircled by C-shaped curve of duodenum
 - Overlies IVC, left and right renal veins and right renal artery.
 - Contains embedded bile duct

- Has a projection from inferior part-the incanate process-that extends to the left
 - Neck:
 - Overlies superior mesenteric vessels
 - Is adjacent to pylorus of stomach
 - Superior mesenteric vein (SMV) joins splenic vein to form portal vein posterior to neck
 - Body
 - Crosses body of L2 and aorta
 - Lies in floor of omental bursa
 - Related anteriorly to the stomach
 - Is in contact posteriorly with aorta, superior mesenteric artery (SMA), left suprarenal gland, left kidney, and related vessels
 - Tail
 - Lies anterior to the left kidney
 - Related to hilum of spleen and left colic flexure
- Main pancreatic duct
 - Begins in the tail and runs towards the head
 - Turns inferiorly to join common bile duct to form hepatopancreatic ampulla (of Vater)
 - Opens on major duodenal papilla in descending portion of duodenum
 - Surrounded by the sphincter of Oddi-smooth muscle
- Accessory pancreatic duct
 - Opens at summit of minor duodenal papilla
 - Can connect with main pancreatic duct (60% of time)
 - Can be main duct for pancreatic secretions
 - Variation as a result of type of fusion or lack of fusion of dorsal and ventral pancreatic ducts during embryonic development
- Vascular supply (*Section 4-6: Abdomen-Visceral Vasculature*)
 - Arteries
 - Mainly from branches of splenic artery
 - Also from gastroduodenal, superior mesenteric, superior, and inferior pancreaticoduodenal arteries
 - Veins
 - Mainly drain to splenic vein
 - Also drain to SMV and then portal vein
 - Lymph
 - Follow blood vessels
 - Mainly drain into the pancreaticosplenic nodes along splenic artery
- Nervous supply (*Section 4-7: Abdomen-Innervation*)
 - From the vagus
 - From thoracic splanchnic nerves
 - Fibers from celiac and superior mesenteric plexuses pass along arteries

page 150

page 151

Spleen

- Largest lymphatic organ, very vascular
- Located in left upper quadrant (LUQ)
- Related posteriorly with ribs 9 to 11 (separated by diaphragm)
- Covered by peritoneum except at the hilum
- Surrounded by a thin capsule of fibroelastic connective tissue
- Relations:
 - Anterior: stomach (gastrosplenic ligament)
 - Posterior: diaphragm
 - Inferior: splenic flexure of colon
 - Medial: left kidney (splenorenal ligament)
 - Tail of pancreas extends to hilum
- Ligamentous attachments
 - Gastrosplenic ligament to greater curvature of stomach
 - Splenorenal ligament to left kidney
 - Both ligaments attach to hilum
 - Spleen sits on phrenicocolic ligament (sustentaculum lienis)
- Vascular supply (*Section 4-6: Abdomen-Visceral Vasculature*)
 - Artery: splenic artery
 - Twisted course from origin at celiac trunk
 - Divides into five or more branches that enter at the hilum
 - Lack of anastomoses between branches results in two to three vascular segments with avascular planes in between.
 - Vein: splenic vein
 - Formed from several tributaries at the hilum
 - Runs to the right behind body and tail of pancreas
 - Joins the SMV to form the portal vein
 - Lymph: drains to the pancreaticosplenic nodes
- Nervous supply (*Section 4-7: Abdomen-Innervation*)
 - Derived from the celiac plexus
 - Travels along branches of splenic artery
 - Vasomotor function

FACTS & HINTS

High-Yield Facts

Anatomic Points

The porta hepatis is the cross bar of an "H" on the visceral surface of the liver. The right arm of the H is formed by the inferior vena cava and the gall bladder. The left arm is formed by the fissure for the ligamentum teres hepatis and the fissure for the ligamentum venosum.

Clinical points

page 151

page 152

Gallstones (cholelithiasis)

- Stone-like deposits are commonly seen in the gallbladder
- If they obstruct the cystic duct, can cause pain in the right upper quadrant (RUQ), especially after consumption of a fatty meal.
- Pain typically comes and goes (biliary colic) and may be associated with nausea and vomiting.
- Secondary inflammation of the gallbladder leads to constant pain, and is often the trigger to seeking medical attention.
- If the gallstones pass further down, they may obstruct the biliary system causing jaundice, or the pancreatic duct causing pancreatitis.

Splenic rupture

- Spleen is the most commonly damaged abdominal organ, despite being protected by the ribcage.
- Trauma causing rib fracture or sudden increases in intra-abdominal pressure (such as being impaled against a steering wheel in a road traffic accident) may result in rupture of the spleen.
- Bleeding is typically profuse owing to its thin capsule and soft parenchyma.

Subphrenic abscess

- Subphrenic recess is a common site for pus to accumulate.
- Right-sided abscesses are more common owing to the incidence of perforation of an inflamed appendix.
- Pus usually tracks into the hepatorenal recess in the supine position, and is best drained inferior to the 12th rib (avoiding puncture of the pleura).

Mnemonics

Memory Aids

Spleen:	"1, 3, 5, 7, 9, 11"
It measures 1 x3 x5 inches, weighs 7 ounces and lies between ribs 9 and 11	

29 Visceral Vasculature

STUDY AIMS

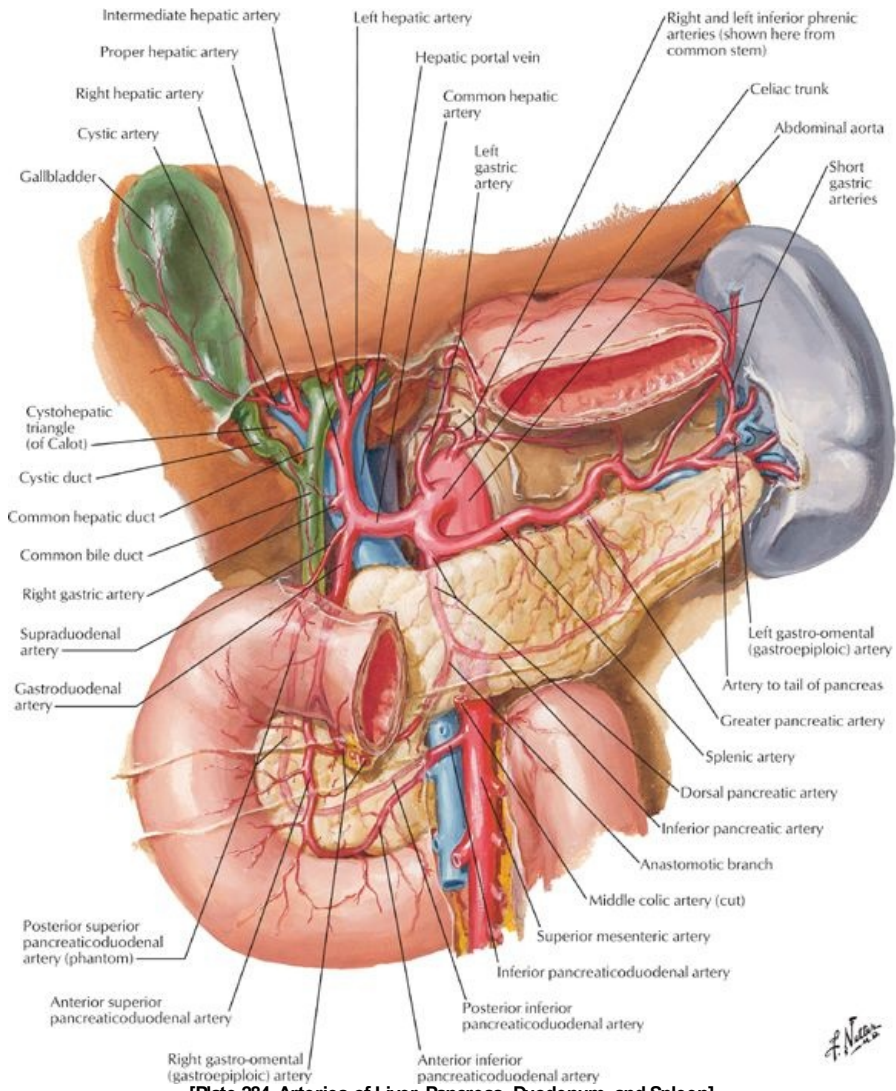
At the end of your study, you should be able to

- Know the unpaired branches of the abdominal aorta
- Know the major branches of the celiac trunk, superior mesenteric artery, and inferior mesenteric artery
- Know the unpaired branches of the abdominal aorta and their distribution of blood
- Understand the two types of venous drainage from the abdomen
- Describe the formation of the hepatic portal vein from the splenic and superior mesenteric veins
- Know the tributaries of the splenic and superior mesenteric veins
- Describe the lymphatic drainage of the abdomen

GUIDE

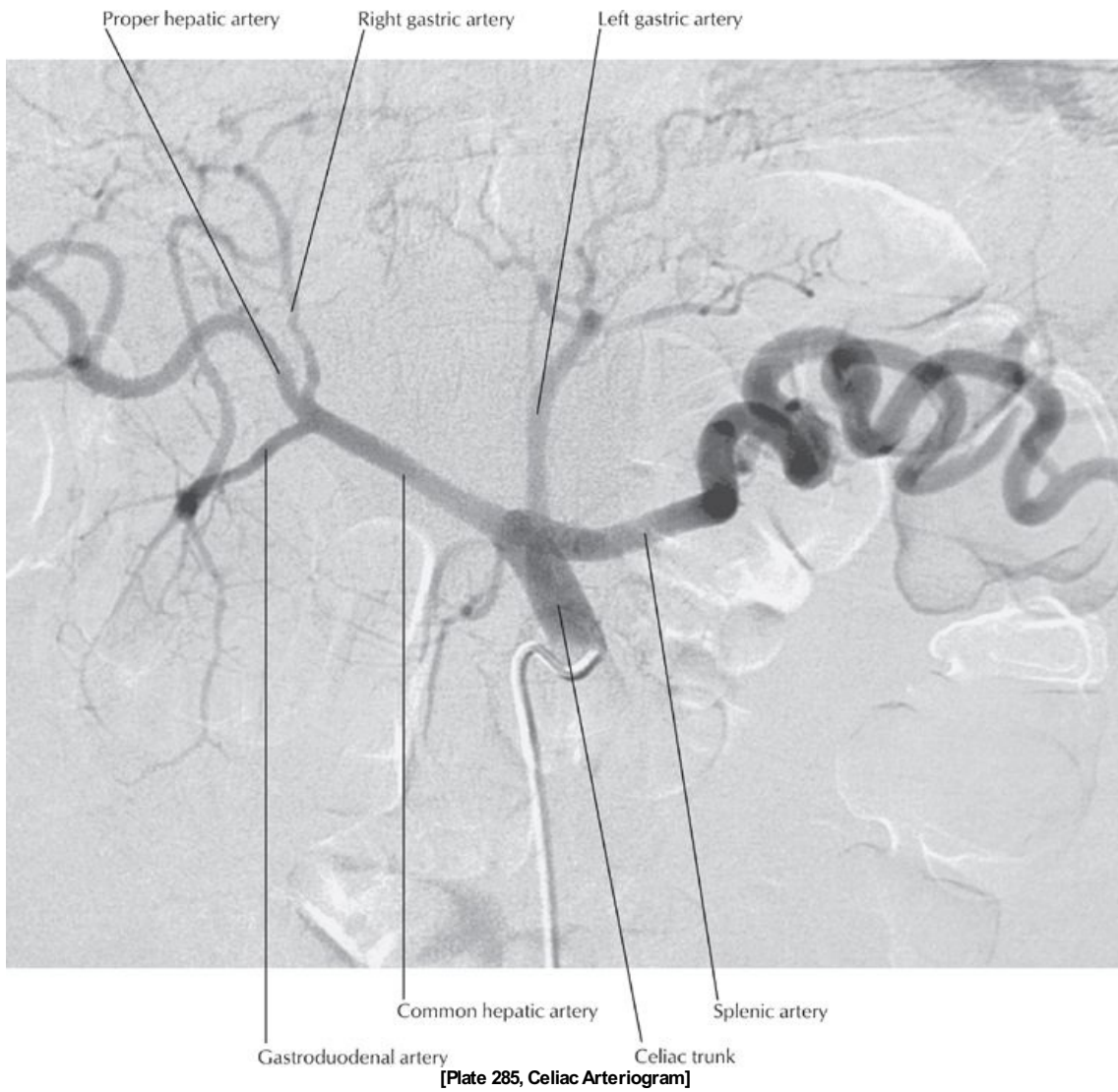Abdomen: Visceral Vasculature

Arterial supply: Unpaired branches of the abdominal aorta (Section 4-2: Abdomen-Body Wall)

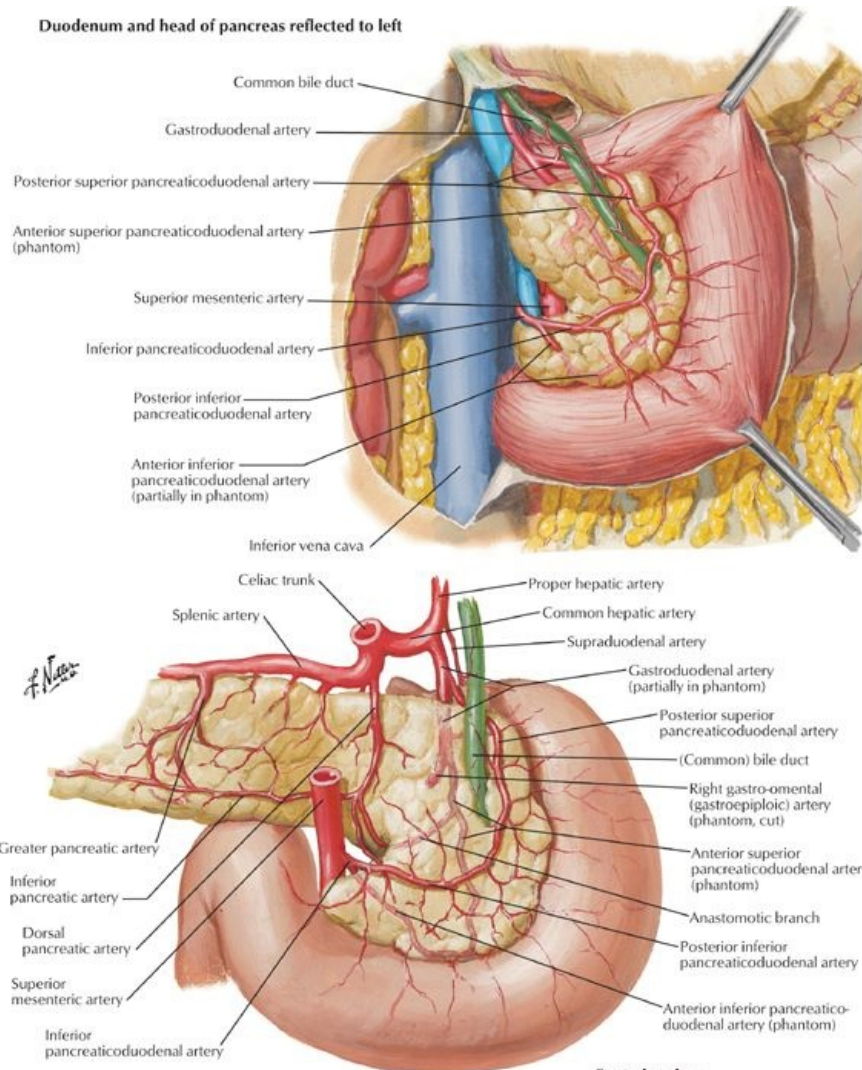


[Plate 284, Arteries of Liver, Pancreas, Duodenum, and Spleen]

F. Netter



Duodenum and head of pancreas reflected to left



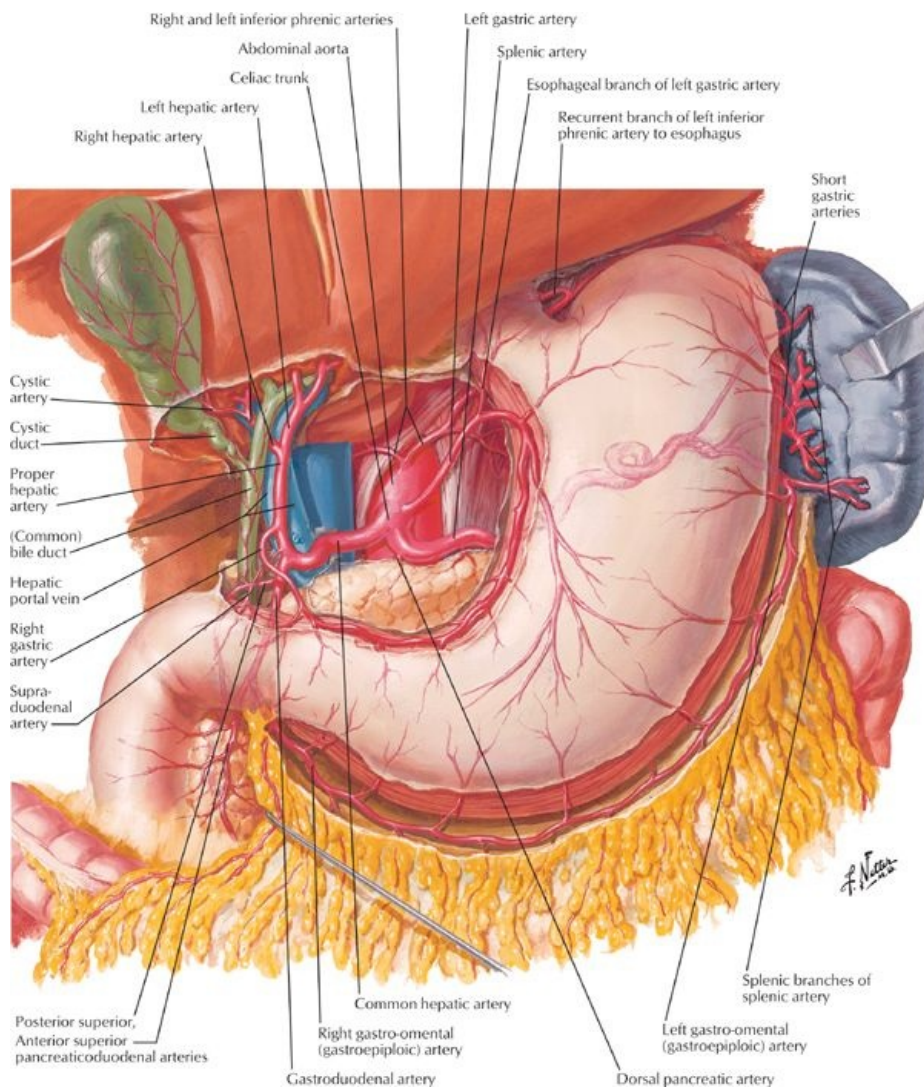
[Plate 286, Arteries of Duodenum and Head of Pancreas]

page 153
page 154

- Celiac trunk
 - Arises at T12
 - Supplies
 - Lower one third of esophagus
 - Stomach
 - First and second parts of duodenum
 - Pancreas
 - Spleen
 - Liver
 - Biliary system
 - Branches
 - Left gastric artery
 - Common hepatic artery
 - Splenic artery
 - Left gastric artery
 - Supplies distal esophagus and lesser curvature of stomach
 - Anastomosis with right gastric artery
 - Splenic artery
 - Supplies body of pancreas and spleen directly
 - Branches:
 - a. Left gastroepiploic: supplies left side of greater curvature of stomach, anastomoses with right gastroepiploic
 - b. Short gastric arteries: supply fundus of stomach
 - Common hepatic artery
 - Extends retroperitoneally to the right to reach hepatoduodenal ligament
 - Divides into gastroduodenal and proper hepatic arteries
 - Gastroduodenal artery branches:
 - a. Superior pancreaticoduodenal supplying the head of pancreas and proximal duodenum
 - b. Right gastroepiploic artery supplying right side of greater curvature of stomach
 - Proper hepatic branches:
 - a. Right and left hepatic arteries to right and left lobes of liver

- b. Right gastric artery to right portion of lesser curvature of stomach
 - c. Cystic artery usually from the right hepatic artery supplies the gallbladder and cystic duct
- Superior mesenteric artery (SMA)
 - Arises at L1
 - Supplies the gut from the second part of duodenum as far as the distal one third of the transverse colon
 - Major branches include:
 - Inferior pancreaticoduodenal
 - a. Supplies duodenum (distal to entry of bile duct), pancreas, and spleen
 - b. Anastomosis with superior pancreaticoduodenal
 - Jejunal and ileal branches
 - a. Form anastomotic loops (arterial arcades)
 - Fewer large loops in jejunum
 - Many shorter loops in ileum
 - b. Loops give off vasa recta (straight arteries)
 - Longer in jejunum
 - Shorter in ileum
 - Ileocolic artery:
 - a. Supplies caecum and some of the ascending colon
 - b. Supplies appendix via appendicular branch
 - Right colic artery: supplies ascending colon and proximal transverse colon
 - Middle colic artery: supplies proximal two thirds of transverse colon
- Inferior mesenteric artery (IMA)
 - Arises at L3
 - Supplies distal one third of the transverse colon → proximal rectum
 - Branches include:
 - Left colic artery: supplies distal transverse, descending and sigmoid colon
 - Superior sigmoid artery(ies): supplies sigmoid colon
 - Superior rectal artery (terminal branch of inferior mesenteric): supplies proximal rectum
- Median sacral artery
 - Arises from posterior aspect of aorta just above bifurcation
 - Descends to supply lower lumbar vertebrae, sacrum and coccyx

Arterial supply: Paired branches of the abdominal aorta



[Plate 283, Arteries of Stomach, Liver and Spleen]

- Inferior phrenic arteries
 - First branches of abdominal aorta (or from celiac trunk)
 - Supply inferior surface of diaphragm
 - Give rise to six to eight superior suprarenal arteries on either side
- Middle suprarenal arteries
 - One or more on either side
 - Originate from aorta near origin of celiac trunk
- Renal arteries
 - Arise at level of L1/L2 intervertebral disc
 - Right renal artery longer and passes posterior to inferior vena cava (IVC)
 - Divide close to hilum into five segmental end arteries
- Gonadal arteries
 - Arise inferior to renal arteries but superior to inferior mesenteric
 - May arise at different levels on either side
 - Run anterior to ureters, cross origin of external iliac vessels in suspensory ligament of ovary and enter broad ligament
 - Divide into ovarian and tubal branches to supply ovary and uterine tube
 - Branches anastomose with correspondingly named branches of uterine artery
- Lumbar arteries
 - Usually four pairs
 - Given off from posterior aspect of aorta
 - Each gives off a dorsal branch
 - Supplies musculature of back
 - Gives off a spinal branch to vertebral column and spinal roots
 - Rest of artery supplies anterolateral abdominal wall
- Common iliac arteries
 - Formed by bifurcation of aorta at level of iliac crest (slightly below level of umbilicus)
 - Follow medial borders of psoas muscle to pelvic brim
 - Bifurcate into internal and external iliac arteries at pelvic brim
 - Supply pelvic viscera and lower limb

Venous Drainage (Section 4-2: Abdomen-Body Wall)

- Veins draining the abdominal viscera are tributaries of one of two venous systems
 - Inferior vena cava
 - Portal vein
- No vein equivalent to celiac trunk or gastroduodenal vein
- Splenic vein and superior mesenteric vein unite to form the portal vein
 - Tributaries of the splenic vein
 - Inferior mesenteric vein and its tributaries (left colic, sigmoid, superior rectal)
 - Pancreatic veins
 - Left gastroepiploic vein
 - Short gastric veins
 - Tributaries of the superior mesenteric vein
 - Inferior pancreaticoduodenal vein
 - Right gastroepiploic vein
 - Right colic vein
 - Ileocolic vein
 - Jejunal veins
 - Ileal veins
 - Veins draining directly into portal vein
 - Cystic vein
 - Superior pancreaticoduodenal
 - Left and right gastric veins also may
 - Tributaries of the IVC
 - Common iliac veins
 - Lumbar veins
 - Enter IVC in irregular pattern
 - Second lumbar vein may enter left renal vein
 - Anastomose with tributaries of epigastric veins
 - Are connected to each other on either side by a vertical anastomotic channel, the ascending lumbar vein
 - Ascending lumbar veins connect with azygos vein on the right and hemiazygos vein on the left
 - Right gonadal vein (left drains to left renal vein)
 - Right and left renal veins
 - Right suprarenal vein (left drains to left renal vein)
 - Right inferior phrenic vein (left drains to left renal vein)
 - Hepatic veins
 - Two to three in number
 - Empty into IVC just below diaphragm
 - Blood from the hepatic portal vein constitutes approximately 70% of the liver's blood supply

Lymphatic Drainage (Section 4-2: Abdomen-Body Wall and Section 4-4: Abdomen-Viscera (Gut) and 4-5: Abdomen-Viscera (Accessory Organs) for specific organs)

-
- Lymphatics generally follow arteries
 - Drain to local, then regional lymph nodes (lumbar, celiac, superior, and inferior mesenteric nodes)
 - Main lymphatic ducts of abdomen from regional nodes
 - Intestinal lymphatic trunks (single or multiple)
 - Right and left lumbar lymphatic trunks
 - Thoracic duct
 - Begins with union of main lymphatic ducts of abdomen, unless cisterna chili is present
 - Ascends into thoracic through aortic hiatus in diaphragm
 - Cisterna chili
 - Thin walled sac or dilation at union of main lymphatic ducts of abdomen
 - Drains to thoracic duct
 - If present, occurs at the level of L1/2
 - Not seen in all individuals
 - Can vary in size and shape

FACTS & HINTS

High-Yield Facts

Clinical Points

Portal Hypertension

- Raised venous pressure within the portal circulation.
- Resistance to portal blood flow may occur due to intrahepatic obstruction (fibrosis of the liver from cirrhosis)
- Resistance may also occur as a result of posthepatic obstruction (such as heart failure or Budd-Chiari syndrome) or prehepatic obstruction.
- Clinical consequences are ascites in the abdomen, congestive splenomegaly, hepatic encephalopathy, and the enlargement of portocaval venous anastomoses

Clinical Points

Budd-Chiari Syndrome

- Caused by hepatic vein obstruction (for example by thrombosis or tumors)
- Patients present with acute epigastric pain and shock
- May also have insidious portal hypertension, ascites, jaundice, and cirrhosis
- Surgery may relieve the obstruction
- Liver transplantation may be needed

page 156
page 157

Clinical Points

Abdominal Aortic Aneurysm

- Localized enlargement of aorta as a result of congenital or acquired weakness of wall
- Pulsations can be detected left of midline
- Common site is just above bifurcation of aorta to common iliac arteries
- Unrecognized rupture of an aneurysm has 90% mortality rate

30 Innervation

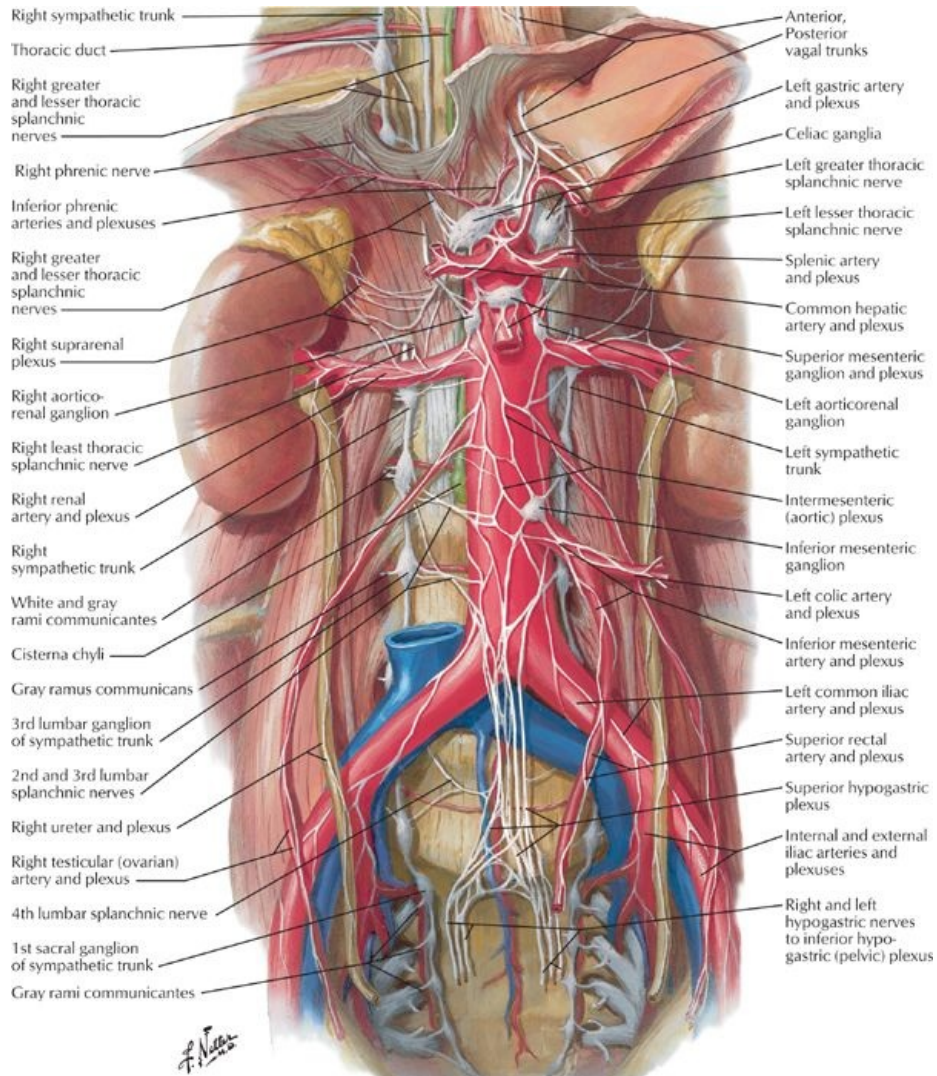
STUDY AIMS

At the end of your study, you should be able to:

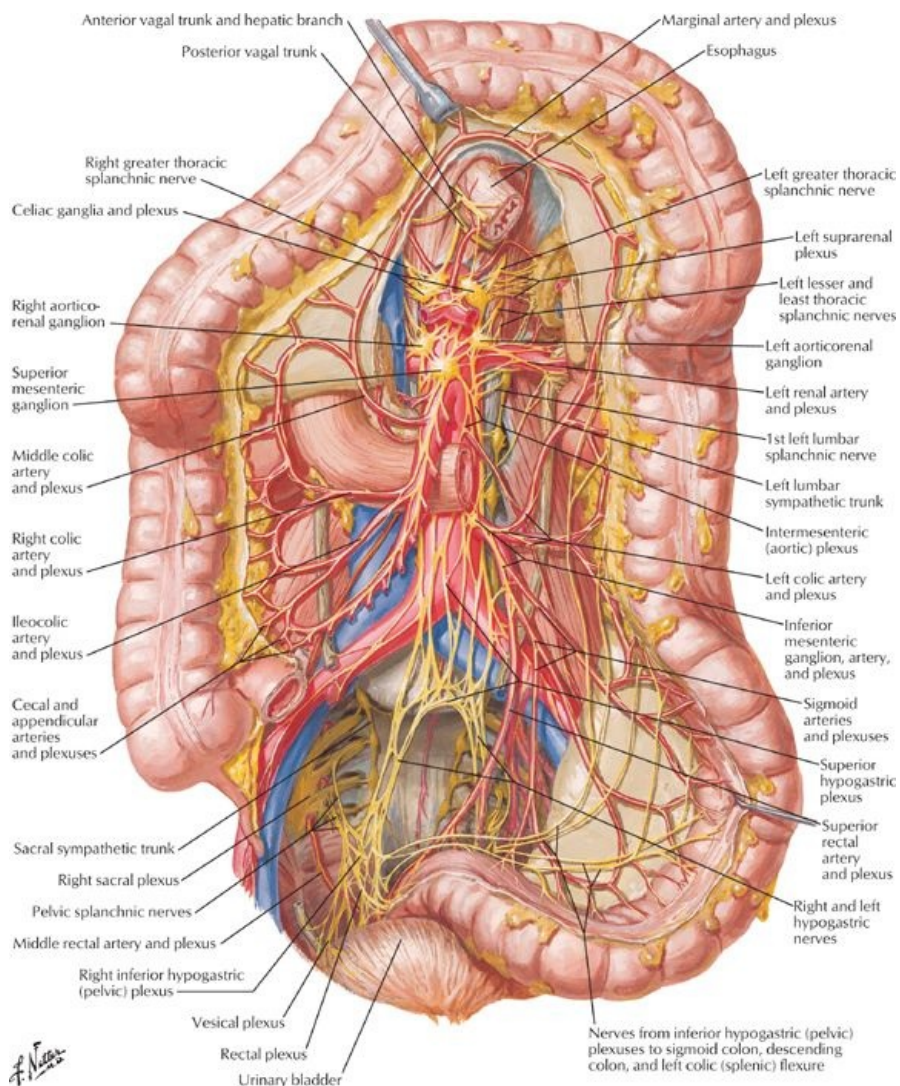
- Describe the parasympathetic contribution to the autonomic innervation of abdominal viscera
- Describe the sympathetic contribution to the autonomic innervation of abdominal viscera
- Understand the organization of the autonomic plexuses of the abdomen
- Describe the somatic innervation of the abdominal wall
- Know the branches of the lumbar plexus
- Understand the principle of referred pain and describe common patterns of pain referral from the abdominal viscera

GUIDE

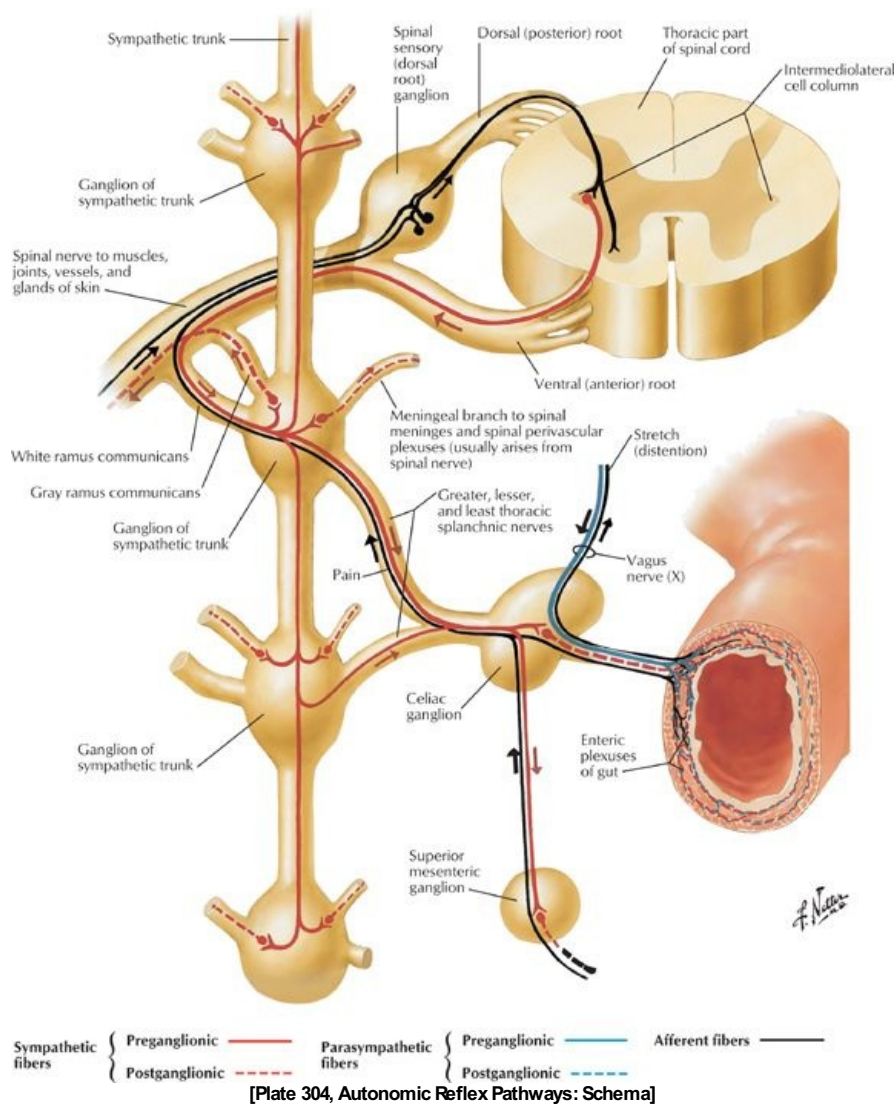
Abdomen: Innervation



[Plate 297, Autonomic Nerves and Ganglia of Abdomen]



[Plate 302, Autonomic Innervation of Large Intestine]



Autonomic Nerves

page 158
page 159

- Parasympathetic nerves
 - Preganglionic fibres
 - Provided by vagus nerve and sacral splanchnic nerves
 - Synapse with postganglionic fibres in the walls of the relevant organs
 - Vagus nerve (CN X)
 - Give rise to anterior and posterior vagal trunks in thorax
 - Trunks enter abdomen at the esophageal hiatus
 - Anterior trunk (mainly from the left vagus)
 - Enters anterior to the esophagus
 - Gives branches to the anterior surface of the stomach and to the liver
 - Posterior trunk (mainly from the right vagus)
 - Enters posterior to the esophagus
 - Gives branches to the posterior surface of the stomach and celiac plexus
 - Fibers pass inferiorly to root of superior mesenteric artery
 - Fibers contribute to perivascular plexuses
 - Accompanying celiac and superior mesenteric artery and their branches
 - Extend as far as the arterial supply (*two thirds of the way along the transverse colon*)
 - Pelvic splanchnic nerves
 - From spinal cord levels S2-S4
 - Emerge through pelvic sacral foramina
 - Ascend from pelvis running in sigmoid mesocolon and peritoneum of posterior abdominal wall
 - Supply distal one third of transverse colon, descending colon, sigmoid colon, and superior rectum
 - Postganglionic (postsynaptic) parasympathetic neurons found in enteric ganglia in wall of viscus
- Sympathetic nerves
 - Right and left sympathetic trunks
 - Enter behind the medial arcuate ligament of the diaphragm
 - Descend along psoas major, with right trunk behind inferior vena cava (IVC)
 - Lie on anterolateral sides of lumbar vertebrae
 - Receive white rami communicantes from, and send gray rami communicantes to, ventral rami of L1-L3 spinal nerves

- Postganglionic fibers in gray rami communicantes to corresponding ventral rami of spinal nerves distributed to the body wall and lower limb
 - Give off three to four lumbar splanchnic nerves (presynaptic sympathetic fibers) medially to:
 - Intermesenteric plexus
 - Inferior mesenteric plexus
 - Superior hypogastric plexus
 - Postsynaptic fibers from these plexuses innervate nearby target organs.
 - Sympathetic (*paravertebral*) ganglia
 - Total of four abdominal sympathetic ganglia per trunk
 - *Prevertebral* sympathetic ganglia
 - Cell bodies of postsynaptic sympathetic neurons
 - Found in plexuses around roots of major branches of aorta
- Aortic plexuses
 - Network of parasympathetic and sympathetic nerves
 - Parasympathetic mainly from posterior vagal trunk (*see above*)
 - Sympathetic fibers from thoracic and lumbar splanchnic nerves (*Section 3: Thorax*)
 - Contain prevertebral ganglia
 - Include:
 - Celiac plexus
 - Aorticorenal plexus
 - Renal plexus
 - Superior mesenteric plexus
 - Intermesenteric plexus
 - Inferior mesenteric plexus
 - Perivascular plexuses derived from the aortic plexuses
 - Visceral afferent fibers
 - Carry pain information
 - Travel with sympathetic fibers back to spinal cord
- Referred pain
 - Information carried by visceral afferent fibers
 - Fibers travel back to T5-L2/3 spinal cord levels via thoracic and lumbar splanchnic nerves
 - Clinical phenomenon of referred pain is visceral pain perceived as somatic pain over the dermatomes innervated by cutaneous nerves with fibers from those spinal cord levels:

Organ	Spinal Level	Area of Referred Pain
Stomach	T5-T9	Epigastric or left hypochondrium
Duodenum	T5-T8	Epigastric or right hypochondrium
Jejunum	T6-T10	Periumbilical
Ileum	T7-T10	Periumbilical
Caecum	T10-T11	Periumbilical or right lower quadrant
Appendix	T10-T11	Periumbilical, then to right iliac fossa
Ascending colon	T10-T12	Periumbilical or right lumbar
Sigmoid colon	L1-L2	Left lower quadrant
Spleen	T6-T8	Left hypochondrium
Liver & gallbladder	T6-T9	Epigastric, later to right hypochondrium
Pancreas	T7-T9	Inferior epigastrium
Kidney	T10-L1	Small of back, flank
Ureter	T11-L1	Loin to groin

Somatic Nerves

- Thoracoabdominal nerves
 - Ventral primary rami of T7-T11
 - Travel in the neurovascular plane between the internal oblique and transversus abdominis muscles
 - Innervate anterolateral abdominal wall, including parietal peritoneum
- Subcostal nerves
 - Ventral primary rami of T12
 - Follow the inferior border of the 12th rib
 - Enter abdomen behind lateral arcuate ligaments
 - Cross quadratus lumborum muscles and pierce transversus abdominis muscles to enter neurovascular plane
 - Innervate anterolateral abdominal wall (*including parietal peritoneum*)
- Lumbar plexus
 - Iliohypogastric nerve (L1)
 - Divides into lateral and anterior cutaneous branches
 - Pierces internal and external oblique muscles
 - Supplies buttocks and suprapubic region
 - Ilioinguinal nerve (L1)
 - Travels in inguinal canal
 - Joins spermatic cord after piercing internal abdominal oblique (*Note: does not enter inguinal canal through deep inguinal ring*)
 - Provides cutaneous branches to skin of inguinal region
 - Genitofemoral nerve (L1,2)
 - Emerges from anterior surface of psoas major muscle
 - Genital branch enters deep inguinal ring to innervate the cremaster muscle
 - Femoral branch passes beneath inguinal ligament in vascular compartment to enter femoral triangle and provides

-
- cutaneous branches to anteromedial thigh
 - Lateral femoral cutaneous nerve (L2,3)
 - Passes beneath or through inguinal ligament, medial to anterior superior iliac spine (ASIS)
 - Innervates anterolateral thigh
 - Obturator nerve (L2-L4)
 - Emerges from medial border of psoas major muscle
 - Passes through pelvis
 - Exits via obturator canal
 - Supplies skin and adductor muscles of medial thigh
 - Femoral nerve (L2-L4)
 - Emerges from lateral psoas major muscle
 - Innervates iliacus
 - Passes beneath inguinal ligament on surface of iliopsoas muscle in muscular compartment
 - Enters femoral triangle to innervate flexors of the hip/extensors of leg at knee, and skin of anterior thigh, medial aspect of leg and foot.
 - Lumbosacral trunk (L4,5)
 - Enters pelvis passing over ala of sacrum
 - Contributes to formation of sacral plexus with ventral rami of S1-S4 spinal nerves

FACTS & HINTS

High-Yield Facts

Anatomic Points

Autonomic innervation of the abdominal viscera

- A perivascular plexus of nerves accompanying the arterial supply to each organ provides autonomic innervation to the abdominal viscera.
- Each plexus has sympathetic and parasympathetic input, both with motor and sensory divisions.
- Motor control governs glandular secretion, smooth muscle activity, and vascular tone.
- Afferent nerves mediate distension of organs and tension on mesenteries.

31 Kidneys and Suprarenal Glands

STUDY AIMS

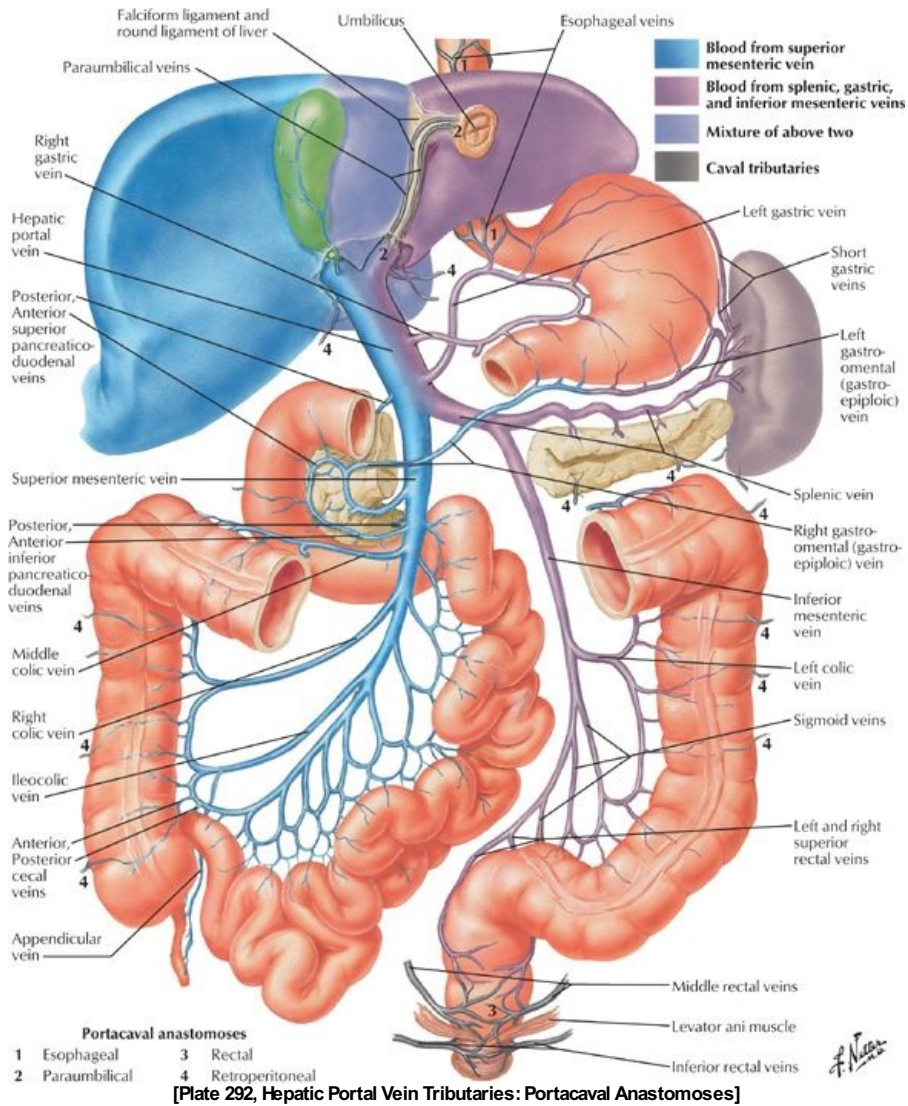
At the end of your study, you should be able to:

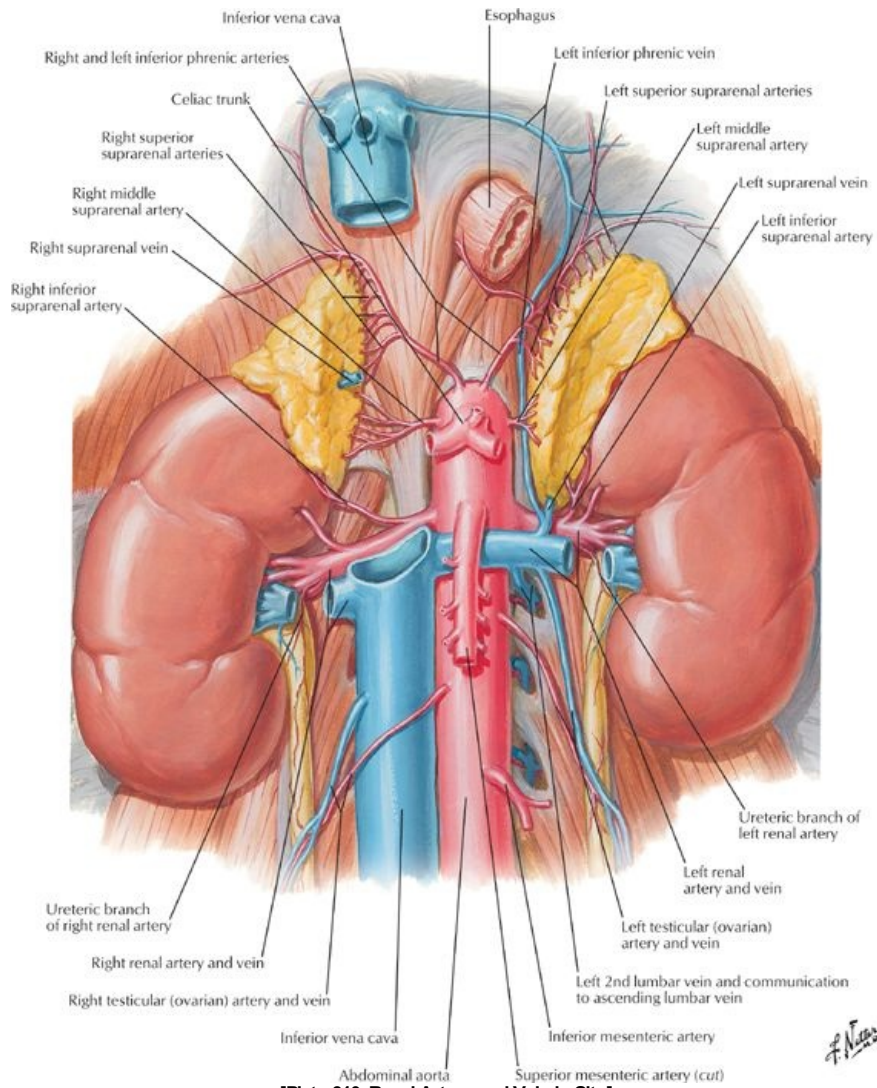
- Describe the structure of the kidneys, their immediate anatomic relations, and neurovascular supply
- Understand the arrangement of perirenal fat, pararenal fat, and renal fascia
- Describe the course of the ureters, points of constriction along their path, and their neurovascular supply
- Describe the structure of the suprarenal glands and their neurovascular supply
- Know the products of the suprarenal cortex
- Understand the products of the medullary cells and the relationship of these cells to the sympathetic nervous system

GUIDE

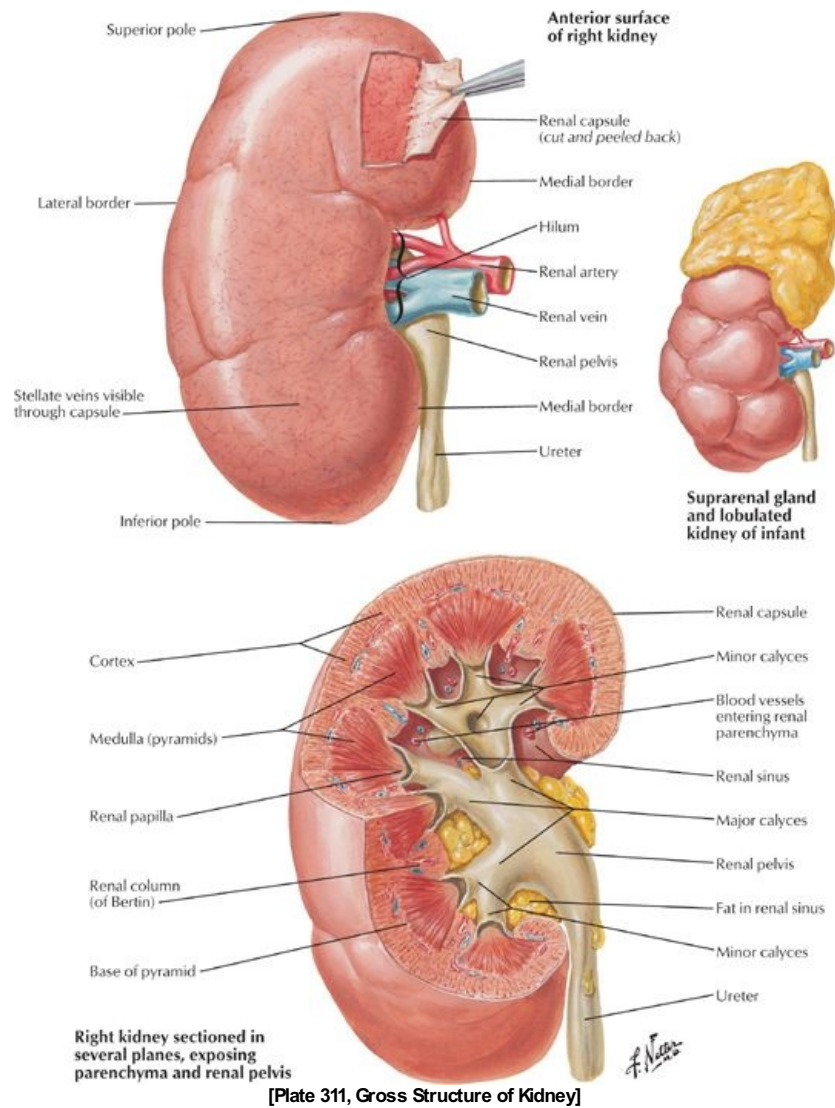
Abdomen: Kidneys and Suprarenal Glands

Kidneys





[Plate 310, Renal Artery and Vein in Situ]



page 162
page 163

- Bean-shaped retroperitoneal organs
- Remove excess water, salts, products of protein metabolism
- Composed of 1 to 4 million nephrons
- Structural parts of a nephron
 - Renal corpuscle
 - Proximal convoluted tubule
 - Thin and thick limbs of loop of Henle
 - Distal convoluted tubule
 - Collecting ducts
- Returns nutrients and necessary salts and chemicals to the blood
- Lie on posterior abdominal wall at the level T12-L3
- Left kidney lies higher than right because of right lobe of liver
- Anatomic relations:
 - Superoposterior: diaphragm
 - Inferoposterior: quadratus lumborum
 - Anterior (right): liver (separated by hepatorenal recess), duodenum and ascending colon
 - Anterior (left): stomach, spleen, pancreas, jejunum, descending colon
- Medial margin (concave) = hilum
 - Renal artery enters
 - Renal vein (artery posterior to vein) and renal pelvis (posterior to vessels) exit
 - Entrance to space within kidney: renal sinus
- Anatomical structures of the kidney
 - Superior and inferior poles
 - Hilum
 - Renal sinus: expansion of proximal end of ureter
 - Divides into two to three major calyces
 - Each major calyx divides into two to three minor calyces
 - Each minor calyx encircles a renal papilla: apex of renal pyramid
 - Cortex
 - Outer layer of kidney

- Contains glomerulus, renal corpuscle, proximal and distal convoluted tubules, proximal collecting ducts
 - Medulla
 - Inner layer of kidney
 - Divided into 10 to 18 pyramidal blocks of tissue: medullary pyramids
 - Contains thick and thin limbs of loops of Henle, distal parts of proximal and distal convoluted tubules, distal collecting ducts
- Renal fascia
 - Separates, but encloses kidneys and suprarenal glands with surrounding perirenal fat
 - Continuous superiorly with fascia of diaphragm
 - Helps to hold kidney in relatively fixed position
- Perirenal fat
 - Continuous at hilum with fat in the renal sinus
 - Surrounds kidney and suprarenal gland
 - Cushions and helps to hold kidney in relatively fixed position
- Pararenal fat
 - External to perirenal fat and renal fascia
 - Most obvious posteriorly
 - Cushions and helps to hold kidney in relatively fixed position
- Vascular supply
 - Right and left renal arteries
 - Branches of aorta (at L1/2), with the right passing posterior to the inferior vena cava (IVC)
 - Lie anterior to renal pelvis
 - Each artery divides into five segmental end arteries; four anterior segmental arteries and one posterior segmental artery
 - Right and left renal veins
 - Anterior to renal arteries
 - Left passes anterior to the aorta and posterior to descending superior mesenteric artery (SMA) = so-called nutcracker
 - Lymphatics
 - Follow the renal veins
 - Drain into the lumbar (aortic) lymph nodes
- Nerves (*Section 4-7: Abdomen-Innervation*)
 - From renal plexus
 - Parasympathetic fibers from the vagus nerve
 - Sympathetic fibers from the thoracic splanchnic nerves

Ureters

page 163
page 164

- Retroperitoneal, muscular ducts from renal pelvis to urinary bladder
- Constricted at three sites along course:
 - Junction of ureter and renal pelvis
 - As they cross the pelvic brim
 - In wall of urinary bladder
 - Potential sites of obstruction of urinary calculi
- Vascular supply:
 - Arteries are branches from
 - Renal arteries
 - Gonadal arteries
 - Aorta
 - Can divide into ascending and descending branches
 - Freely anatomise
 - Veins drain into the renal and gonadal veins
 - Lymphatics
 - Join the renal lymphatic vessels
 - Or pass directly to lumbar (aortic) and common iliac nodes
- Nervous supply
- From the renal, aortic, superior, and inferior hypogastric plexuses
- Visceral afferent fibers (pain) follow sympathetic fibers to T11-L2 spinal cord segments

Suprarenal (adrenal) glands

- Endocrine glands concerned with metabolism
- Have different shapes
 - Triangular right gland
 - Semilunar left gland
- Located between upper pole of kidney and diaphragm
- Surrounded by perinephric fat, inside the renal fascia
- Anatomic relations:
 - Right gland
 - Anterior to diaphragm
 - Contacts IVC and liver
 - Left gland related to spleen, stomach, and left crus of diaphragm
 - Parts
 - Cortex and medulla
 - Have different embryologic origins and functions
- Cortex
- Derived from mesoderm
- Secretes
 - Glucocorticoids

-
- Mineralocorticoids
 - Corticosteroids
 - Secretions affect kidneys to control sodium and water retention
 - Medulla
 - Primarily nerve tissue filled with sinusoids and capillaries
 - Medullary cells derived from neural crest cells: chromaffin cells
 - Are innervated by preganglionic (presynaptic) sympathetic neurons
 - Act as postganglionic (postsynaptic) neurons
 - Secrete adrenaline (epinephrine) and noradrenaline (norepinephrine)
 - Secretions lead to typical sympathetic response to traumatic stress
 - Increase heart rate and blood pressure (BP)
 - Dilate bronchioles
 - Vascular supply:
 - Arteries
 - Superior suprarenal arteries (6-8) from the inferior phrenic artery
 - Middle suprarenal artery (ies) from the aorta
 - Inferior suprarenal artery (ies) from the renal artery
 - Veins
 - Drainage into a single, large suprarenal vein
 - Drains into the renal vein on the left and the IVC on the right
 - Lymphatics
 - Arise from a plexus deep to the capsule of the gland
 - Arise from plexus in medulla
 - Many vessels leave glands draining to lumbar nodes
 - Innervation
 - From the celiac plexus and thoracic splanchnic nerves
 - Fibers are myelinated presynaptic fibers
 - Synapse on chromaffin cells

FACTS & HINTS

High-Yield Facts

Anatomic Points

Vascular supply to the kidney

- Variation in the vascular supply to the kidney is fairly common.
- Embryologically, the kidneys develop in the pelvis and ascend to their abdominal position.
- In doing so, they acquire successively more superior vessels from the aorta and IVC, whereas inferior vessels degenerate.
- Failure of degeneration of any of these vessels may result either in branches to the poles of the kidney, or in accessory vessels at the hilum.
- Furthermore, the renal arteries are not infrequently divided prior to their arrival at the hilum.

Clinical Points

Nephrolithiasis (kidney stones)

- Renal calculi (stones) may be found anywhere between the renal calices and urinary bladder
- A stone in the ureter can cause significant distension
- This results in colicky pain radiating from loin to groin as ureteric contractions try to move the stone distally
- In the past, an intravenous urogram (pyelogram) was the imaging tool to determine a filling defect in the ureter
- More recently, a computed tomography (CT) scan has become the tool of choice, because patients may have an allergic response to the dye used in the urogram.
- Management is usually conservative (waiting for the stone to pass), but may be surgical or involve lithotripsy (sonic disruption of the stone).

Renal cysts

- Cysts are a common finding in the kidney.
- They may be solitary or multiple.
- Solitary cysts are usually of no clinical consequence.
- Multiple cysts may cause gross distortion and enlargement of the kidneys, culminating in renal failure.
- Multiple cysts may be caused by adult polycystic kidney disease, because of an autosomal dominant gene.

Pelvis and Perineum

page 165
page 166

32 Topographic Anatomy

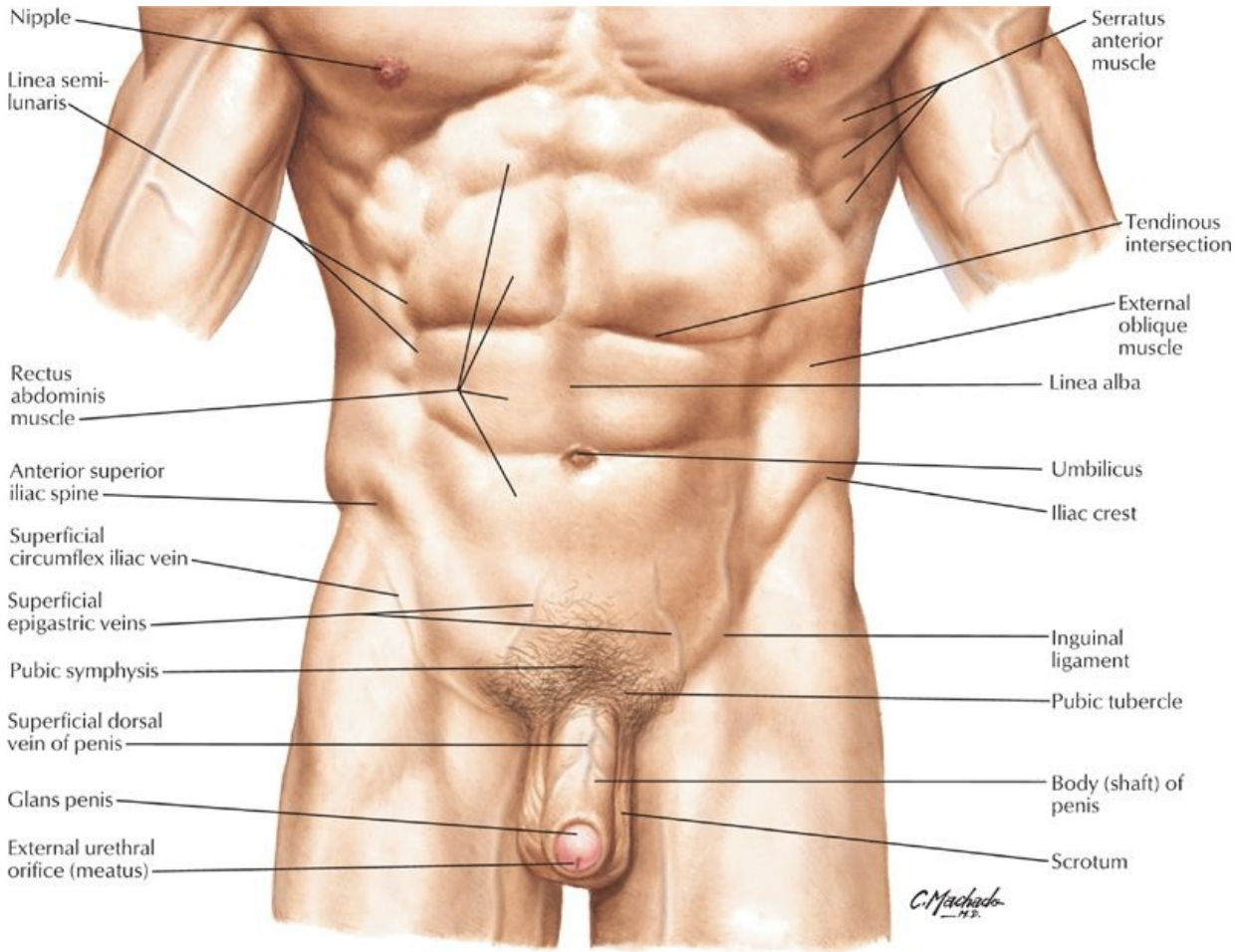
STUDY AIMS

At the end of your study, you should be able to:

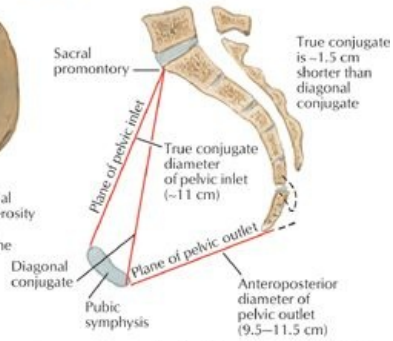
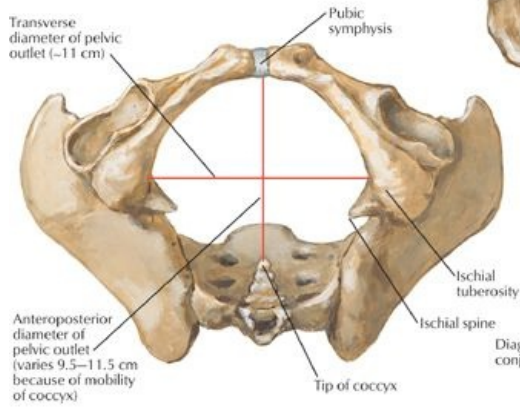
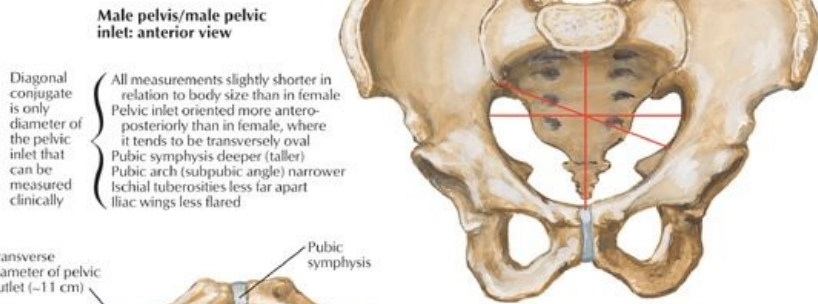
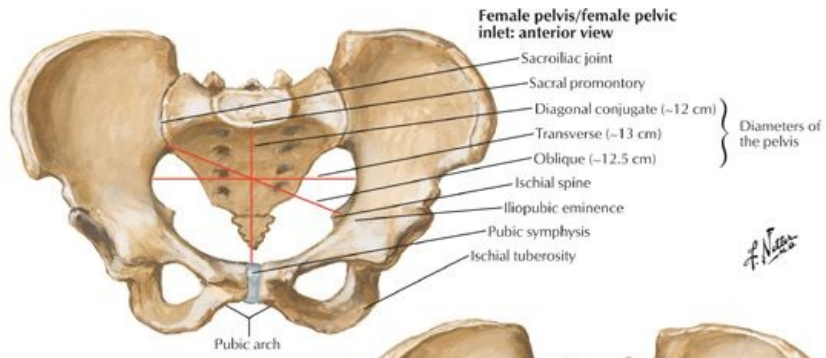
- Know the functions of the bony pelvis and pelvic girdle
- Identify prominent landmarks and their clinical relevance

GUIDE

Pelvis and Perineum: Topographic Anatomy



[Plate 331, Pelvis and Perineum]

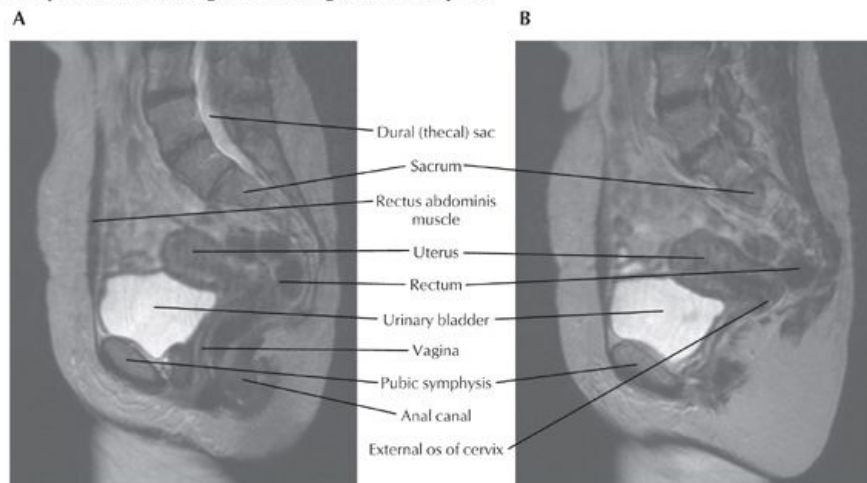


Female pelvis/female pelvic outlet: inferior view

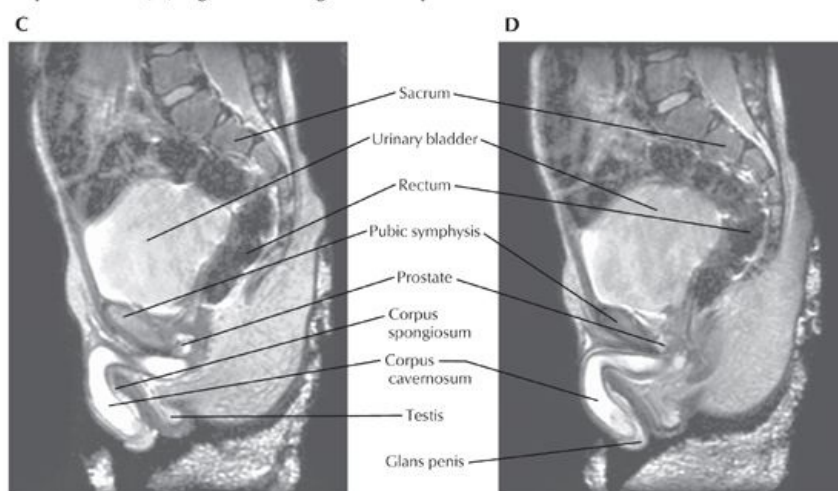
Female: sagittal section

[Plate 334, Sex Differences of Pelvis: Measurements]

Median (A) and paramedian (B) sagittal MR images of female pelvis



Median (C) and paramedian (D) sagittal MR images of male pelvis



[Plate 377, Pelvic Scans: Sagittal MR Images]

Functions of the Pelvic Girdle

- Site of attachment of axial skeleton and lower limbs
- Transmits weight of upper limbs, head, neck and trunk to lower limb
- Involved in balance
- Protects and contains pelvic viscera (distal ureters, bladder, rectum, sigmoid colon, reproductive organs)

Key Landmarks

- Anterior superior iliac spine (ASIS)
 - Site of lateral attachment of inguinal ligament
 - Site of attachment of sartorius and tensor fascia lata muscles
- Pubic tubercle
 - Medial point of attachment of inguinal ligament
- Pubic symphysis
 - Secondary cartilaginous joint
 - Location of T12 dermatome along its superior margin
- Midpoint between pubic tubercle and ASIS marks the site for palpating the femoral artery and vein (the midinguinal point)
- Iliac crest
 - Follows a curve between the anterior and posterior superior iliac spines
 - Highest point is at approximately the level of the umbilicus-level of L4 vertebral body
 - Supracristal plane passes between the highest points of the iliac crests
- Intergluteal or natal cleft
 - The cleft between the buttocks
 - Site of pilonidal sinus and abscess formation

FACTS & HINTS

High-Yield Facts

Clinical Points

- **Pregnancy:** In pregnancy the placenta can be palpated above the pubic symphysis at 12 weeks, at the umbilicus at 12 weeks, and at the xiphisternum at 40 weeks.
- **Acute Urinary Retention:** The bladder, if distended, may be palpated and percussed up to the umbilicus. On examination, the bladder is dull to percussion and in acute urinary retention, the patient may also complain of tenderness on palpation in the suprapubic region.
- **Supracristal Line:** A useful landmark when performing a lumbar puncture since it corresponds to the 4th lumbar vertebral body. Lumbar puncture in adults is performed in the lateral decubitus position in the L4-L5 interspace.
- **Pilonidal Sinus:** A blind ending hair-filled tract most commonly found in the midline of the natal cleft overlying the lower sacrum and coccyx and occurs in 26/1000 persons in the United States. The sinus can become infected, creating a so-called **pilonidal abscess** that usually requires drainage and/or excision of the sinus.

33 Bones and Ligaments

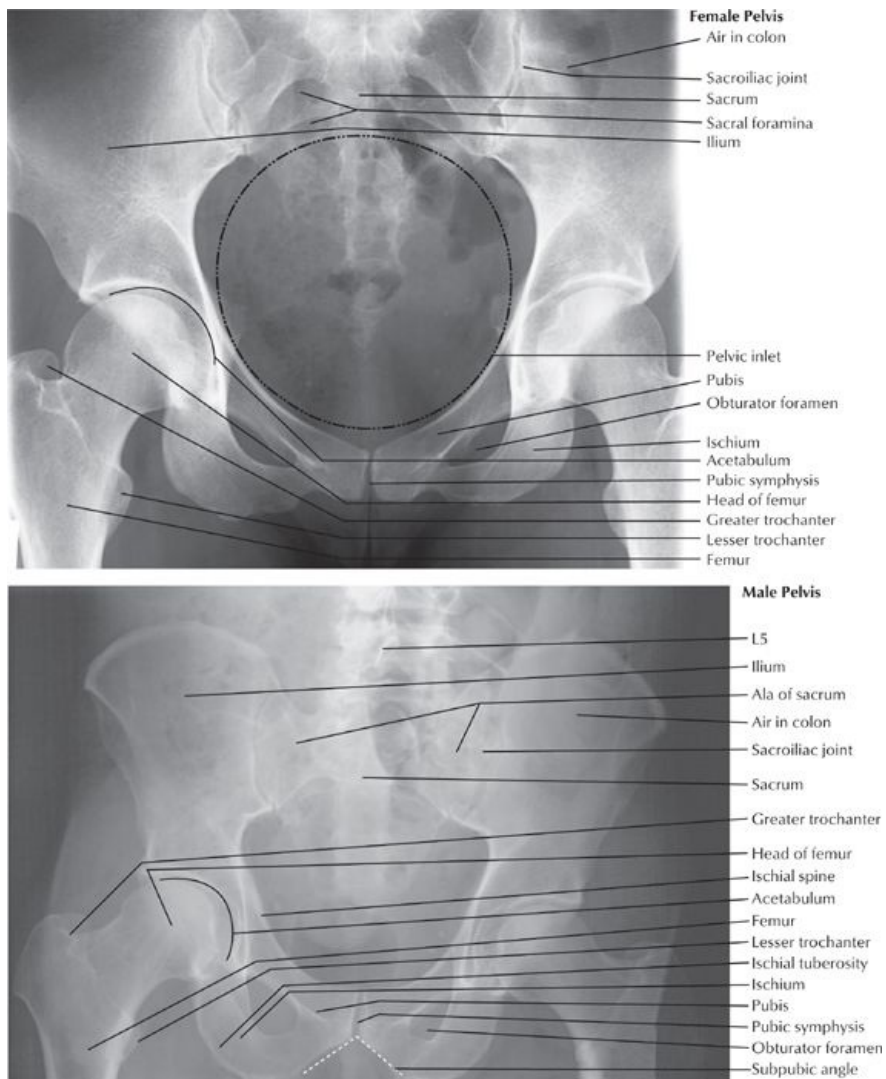
STUDY AIMS

At the end of your study, you should be able to:

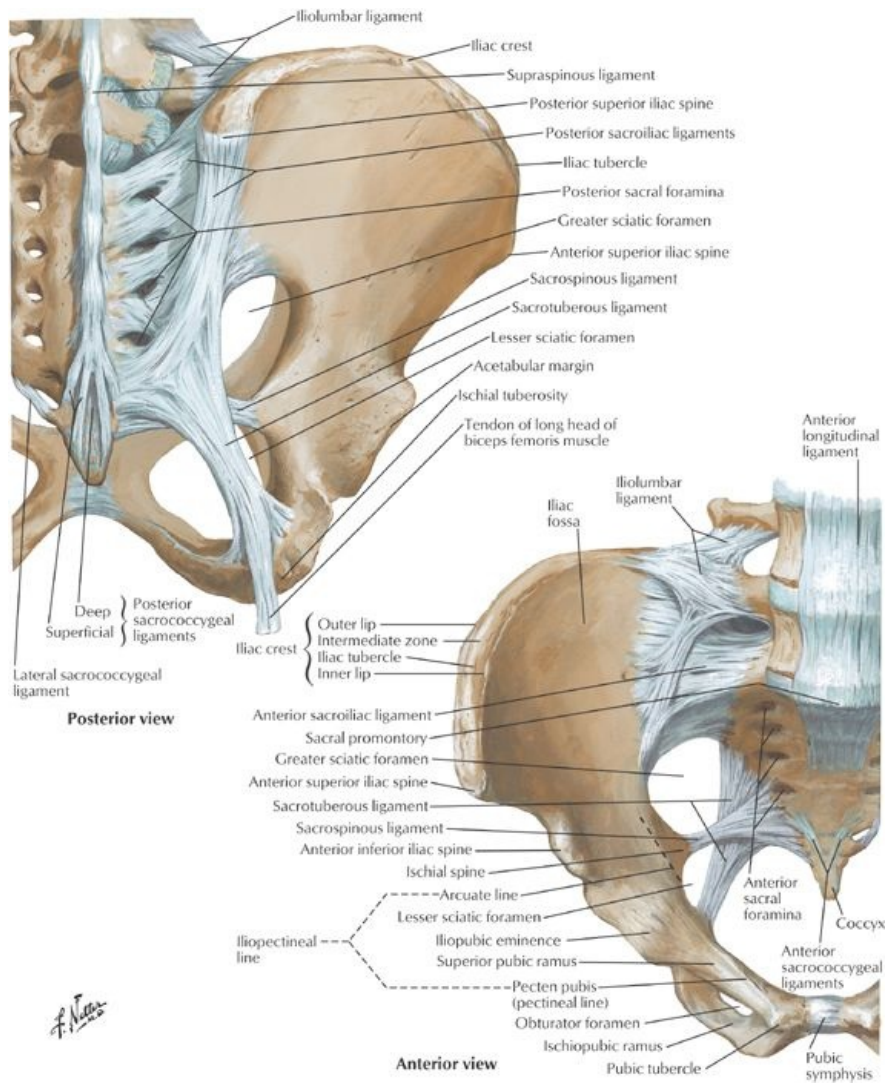
- Identify the components of the bony pelvis
- Define the boundaries of the pelvic cavity
- Describe the joints of the pelvis
- Describe the ligaments that strengthen the pelvis
- Outline the key differences between the male and female pelvis
- List the structures that pass through the greater and lesser sciatic foramina

GUIDE

Pelvis and Perineum: Bones and Ligaments



[Plate 333, Radiographs of Male and Female Pelvis]



[Plate 335, Bones and Ligaments of Pelvis]

Bones and Boundaries of the Pelvis

Bony pelvis

- Is a strong ring
- Supports the weight of the body
- Provides attachment for powerful muscles that move the lower limb
- Composed of four bones
 - Two hip bones or innominate bones
 - Sacrum-five fused sacral vertebrae
 - Coccyx-four (+ 1) fused coccygeal vertebrae
- Hip or innominate bones each formed from
 - Ilium
 - Ischium
 - Pubis
 - Fuse at puberty
 - Are united by cartilage at the acetabulum
- Pelvic girdle
 - Is formed of hip bones and sacrum
 - Transmits weight from upper body to lower limbs

Pelvic walls

- Formed by bones of bony pelvis, ligaments, muscle, and fascia
- Surround pelvic cavity

Pelvic cavity

- Basin shaped
- Surrounded by bony pelvis

- Boundaries:
 - Superiorly-pelvic inlet and inferior abdominal cavity
 - Inferiorly-pelvic diaphragm
 - Anterior wall-bodies and rami of pubic bone and pubic symphysis
 - Posterior wall-sacrum and coccyx, adjacent ilia and overlying piriformis muscle
 - Lateral walls-hip bones, obturator foramen and membrane, and overlying obturator internus muscle

Pelvic inlet, outlet, and brim

- Inlet defined by an oblique plane
 - Extends from promontory to the superior aspect of the pubic symphysis
 - Lies at an angle approximately 55 degrees from horizontal
- Rim of pelvic inlet = pelvic brim, composed of a bony line running through
 - Sacral promontory
 - Arcuate line of the ilium
 - Pectineal line of the pubis (pecten pubis)
 - Pubic crest
 - Superior edge of pubic symphysis
- Pelvic outlet is bounded by
 - Tip of coccyx
 - Sacrotuberous ligaments
 - Inferior ischiopubic rami and ischial tuberosities
 - Inferior edge of pubic symphysis
- Pelvic inlet divides pelvis into two parts
 - True pelvis or lesser pelvis or pelvis minor, which
 - lies between pelvic inlet and outlet
 - contains the pelvic viscera
 - False pelvis or greater pelvis or pelvis major, which
 - lies above pelvic brim
 - between the iliac fossae
 - contains part of the ileum and sigmoid colon
- The birth canal includes the pelvic inlet, true pelvis, cervix, vagina, and pelvic outlet

Joins of the Pelvis

Lumbosacral joints

- Composed of
 - Intervertebral joint via intervertebral disc between L4 and S1
 - Two posterior zygapophysial joints
- Reinforced by iliolumbar ligaments

Sacroiliac joint

- Articulation between ear-shaped surfaces of the sacrum and ilium
- Atypical synovial joint formed with fibrocartilage rather than hyaline cartilage
- Movement is very limited
- Stabilized by interosseous and anterior and posterior sacroiliac ligaments

Pubic symphysis

page 169
page 170

- Union of bodies of right and left pubic bones
- Secondary cartilaginous joint
- Fibrocartilaginous interpubic disc in the joint
- Stabilized by superior and inferior pubic ligaments
- Affected by the hormone relaxin during pregnancy to permit freer movement between vertebral column and to increase pelvic diameter during childbirth

Sacrococcygeal joint

- Articulation between sacrum and coccyx
- Secondary cartilaginous joint
- Stabilized by anterior and posterior sacrococcygeal ligaments

Ligaments of the Pelvis

- The weight of the body acting through the spine will tend to rotate the sacrum, tipping the lower part backwards.
- This movement is prevented by the sacrospinous and sacrotuberous ligaments.
 - Sacrospinous ligament: extends from lateral border sacrum to ischial spine
 - Sacrotuberous ligament: larger and extends from dorsum and lateral border sacrum and posterior surface ilium to ischial tuberosity
- Attachments of sacrospinous and sacrotuberous ligaments enclose the lesser and greater sciatic notches, respectively, forming the greater and lesser foramina

Structures Passing Through the Greater and Lesser Sciatic Foramina

Greater Sciatic Foramen	Lesser Sciatic Foramen
Piriformis muscle	Tendon of obturator internus
Sciatic nerve	Nerve to obturator internus
Inferior gluteal nerve and artery	Pudendal nerve
Internal pudendal nerve, artery, and vein	Internal pudendal artery
Nerve to obturator internus muscle	
Nerve to quadratus femoris	
Posterior cutaneous nerve of the thigh	

Sex Differences of Pelvis

- Differences linked to function
 - Pregnancy and childbirth in females
 - Heavier build and larger muscles of men
- Main differences
 - Pelvis is heavier and has more pronounced muscle attachment sites in men than in women
 - Pubic arch is narrower and the subpubic angle more acute in men than women
 - Ischial tuberosities are closer in men than in women, and the pelvis outlet is thus comparatively smaller.
 - All of the ilia are less flared in men than in women, so the greater pelvis is deeper.
 - Pelvic inlet is heart-shaped in men and more transversely oval in women
 - Obturator foramen is round in men and oval in women
 - Female pelvis is broader than in men, to allow the passage of the fetal head

FACTS & HINTS

Anatomic Points

page 170
page 171

Measurements of the Pelvic Inlet

- Used to determine capacity of female pelvis for childbearing
- True conjugate diameter
 - measured radiologically on a lateral x-ray
 - distance from superior border of pubic symphysis to sacral promontory
- Transverse diameter: widest distance of pelvic inlet
- Oblique diameter: distance from sacroiliac joint to contralateral iliopectineal line

Clinical Points

Fractures of the Pelvis

- A large force is required to fracture the pelvis and fractures usually result from direct trauma, such as occurs in automobile accidents
- The bony pelvis may fracture at any point and there may be associated damage to pelvic viscera, for example, bladder and urethral rupture can occur with fractures involving the pubis
- Pelvic fractures are classified as stable or unstable.
 - In a stable fracture, the pelvis remains stable and there is only one break-point in the pelvic ring with minimal hemorrhage.
 - In an unstable fracture, the pelvis is unstable with two or more break-points in the pelvic ring with moderate to severe hemorrhage.
- Signs of a fractured pelvis include: pain in the groin, hip or lower back; difficulty walking; urethral, vaginal or rectal bleeding; scrotal hematoma; and shock as a result of concealed hemorrhage (contained bleeding into the pelvic cavity)
- A fracture can be confirmed on x-ray and is seen as a break in continuity of the pelvic ring.

Decubitus Ulcers

- Also called pressure sores
- Can be a partial- or full-thickness loss of skin, underlying connective tissue and can extend into muscle, bone, tendons, and joint capsules.
- Two thirds of pressure sores occur in patients older than 70 years
- Results from prolonged pressure on an area of skin, connective tissue and muscle from a mattress, wheelchair seat, or bed rail.
- Commonly occur in those with poor mobility, bed-bound, poor nutrition, and incontinence.
- Can become infected with bacteria from poor skin care, or fecal or urinary incontinence
- The hip and buttock regions account for 67% of all pressure sores, with ischial tuberosity, trochanteric, and sacral locations being most common.
- In the sitting position, the ischial tuberosity bears the weight of the whole body and thus is a prime site of ulceration

34 Pelvic Floor and Contents

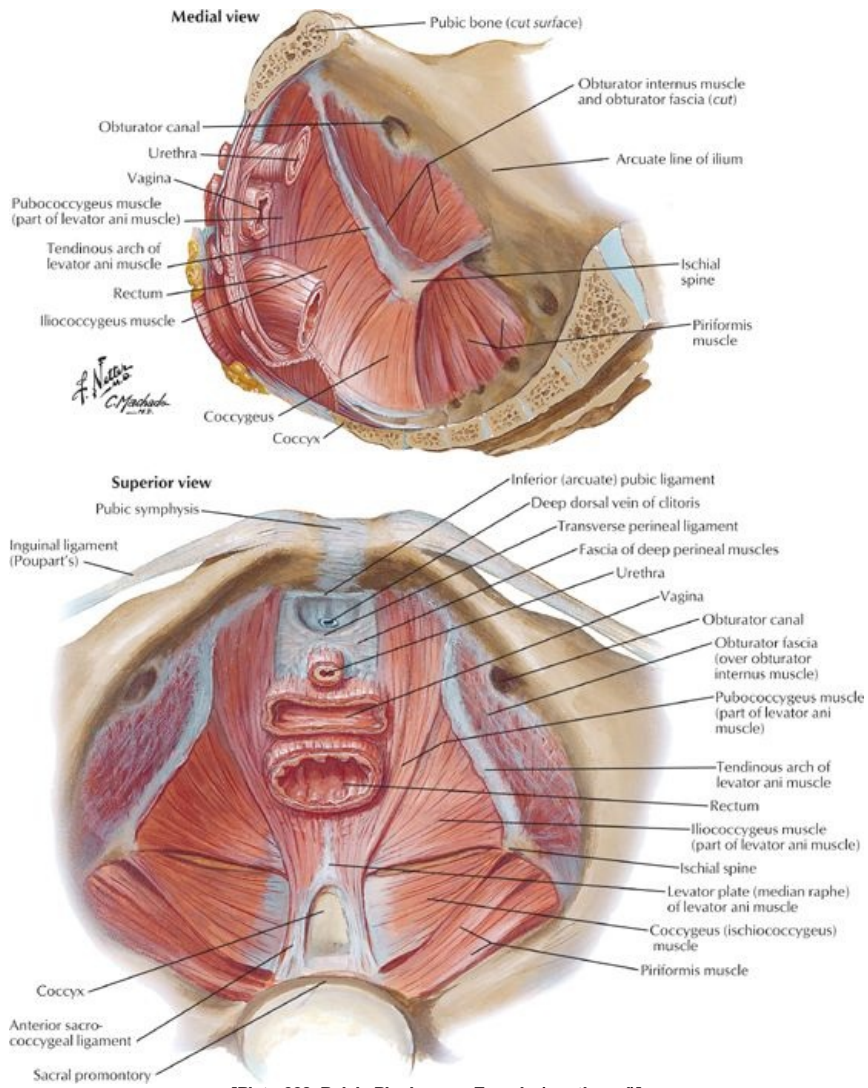
STUDY AIMS

At the end of your study, you should be able to:

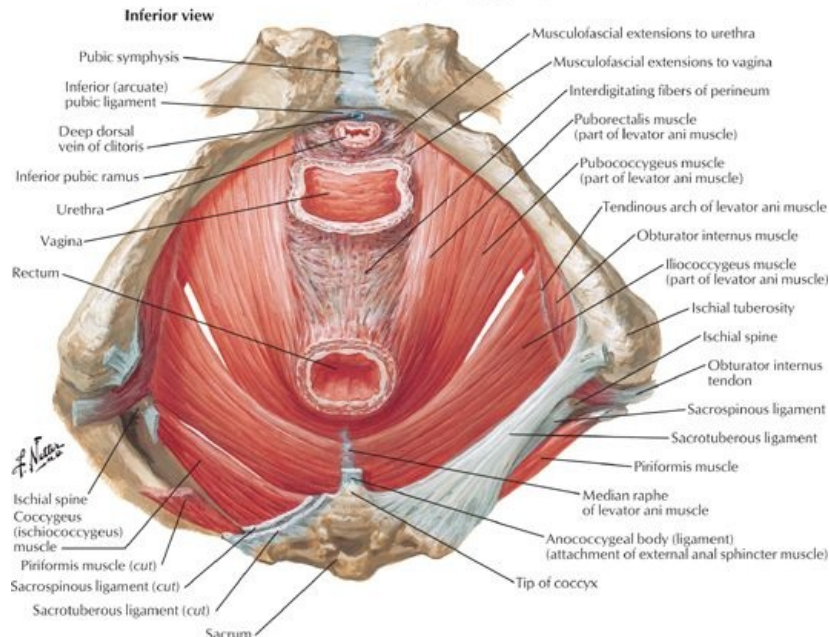
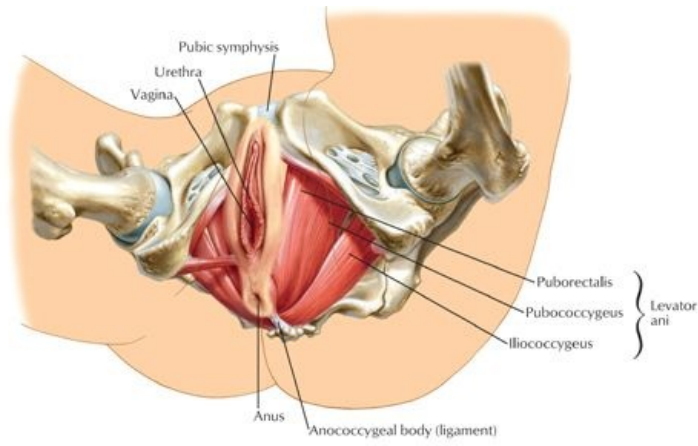
- State the structures that form the pelvic floor
- Describe the two main muscles that form the pelvic floor and their attachments
- List the functions of the pelvic floor muscles
- Describe the attachments of the peritoneum within the pelvis and the location of the vesico- and recto-uterine pouches in females and rectovesical pouch in males
- Understand the organization and function of the pelvic fascia
- Describe the clinical problems that may arise with weaknesses of the pelvic floor muscles

GUIDE

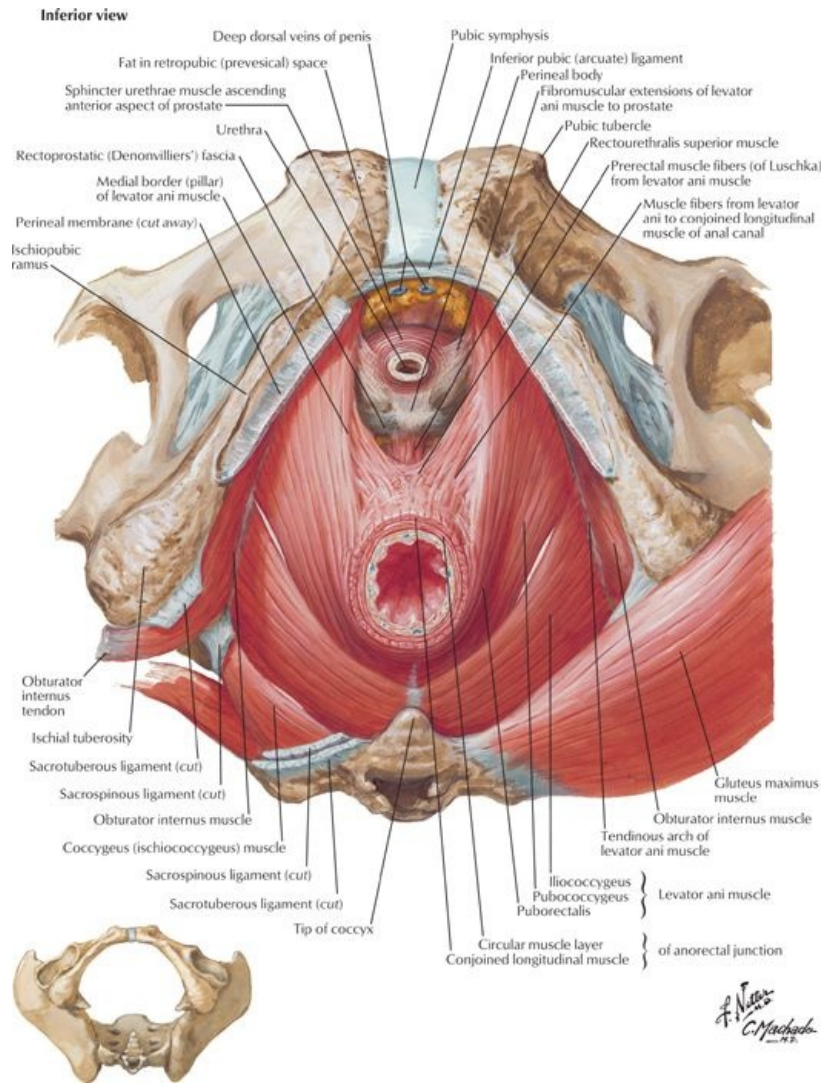
Pelvis and Perineum: Pelvic Floor and Contents



[Plate 338, Pelvic Diaphragm: Female (continued)]

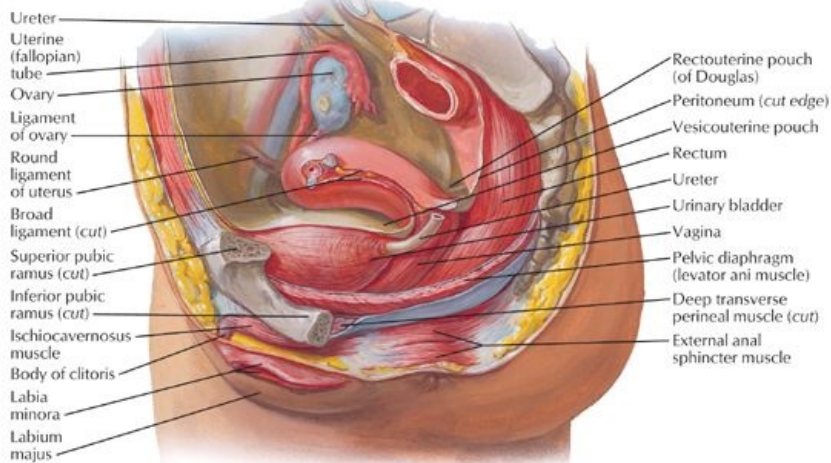


[Plate 339, Pelvic Diaphragm: Female (Continued)]

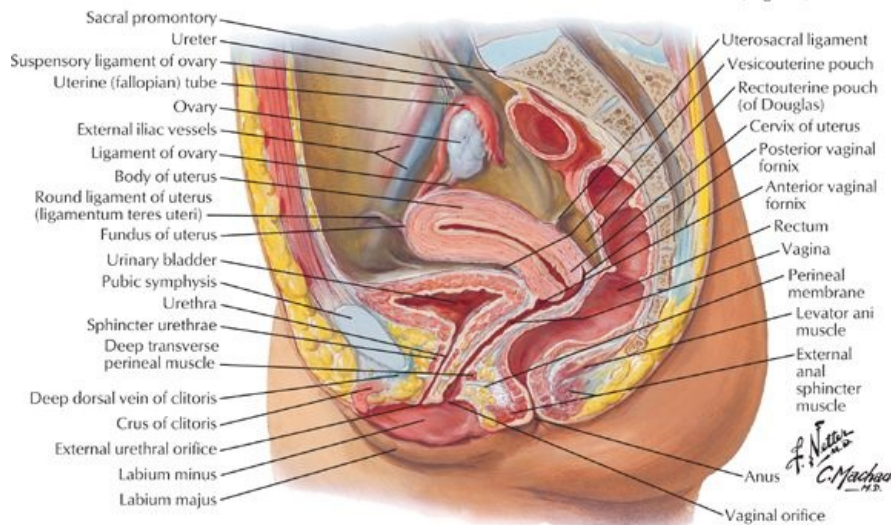


[Plate 341, Pelvic Diaphragm: Male (Continued)]

Paramedian (sagittal) dissection



Median (sagittal) section



[Plate 342, Pelvic Viscera and Perineum: Female]

Pelvic Floor

- Formed by the pelvic diaphragm
- Funnel-shaped
- Muscular partition from the pubis to the coccyx and from lateral wall to lateral wall
- Separates pelvic cavity from perineum inferiorly
- Transmits urethra, vagina (in females) and anal canal

Muscles of Pelvic Floor

- The pelvic diaphragm is composed of two paired muscles
 - Levator ani
 - Coccygeus
- Levator ani muscle
 - Paired muscle
 - Principal muscle of pelvic floor
 - Supports pelvic contents
 - Actively maintains position of pelvic viscera
- Arcus tendineus: a thickened line of the fascia over the obturator internus muscles running in an arching line from the pubis to the ischial spine
- Central perineal tendon or perineal body
 - A fibromuscular body extending from the perineum into the urogenital hiatus
 - The site of numerous muscle attachments in the perineum
- Components of the levator ani muscle
 - Pubococcygeus
 - Is anterior part of levator ani
 - Main contributor to the levator ani
 - Arises from the posterior body of the pubic bone and anterior part of the arcus Tendineus
 - Runs posteriorly to attach to the anococcygeal ligament and the coccyx

page 172

page 173

- o Iliococcygeus
 - Posterior part of the levator ani is thin and poorly developed
 - Arises from the posterior part of the arcus tendineus and the ischial spine
 - Attaches to the anococcygeal raphe and the coccyx
- o Puborectalis
 - Athickened band of muscle best seen inferior to the pubococcygeus
 - Unites with its partner to make a U-shaped sling around the rectum at its junction with the anus
 - Has a sphincter-like action by pulling the anorectal junction forward and contributing to anal continence
- Medial muscle fibers of the pubococcygeus border the urogenital hiatus
 - o Most anterior fibers insert into the urethra
 - o Other fibers sweep behind the vagina or prostate and insert into the central perineal tendon, and are called the levator prostatae or pubovaginalis
- Coccygeus muscle
 - o Reinforces pelvic floor posteriorly
 - o Arises from ischial spine
 - o Inserts on lower two sacral and upper two coccygeal segments
 - o Blends with sacrospinous ligament on its external surface
- Innervation of the levator ani and coccygeus muscles
 - o Levator ani innervated by branches from the anterior rami of S3-S4 spinal nerves
 - o Puborectalis also innervated by branch of pudendal nerve (S2,3,4)
 - o Coccygeus supplied by branches of the anterior rami of S4-S5 spinal nerves
- Functions of the levator ani
 - o Acting together raise the pelvic floor to increase abdominal pressure, such as when coughing, sneezing, urinating, defecating, lifting heavy objects.
 - o Important in voluntary control of micturition (urinating)
 - o Supports pelvic viscera
 - o Supports head of the fetus

Muscles Lining the Lateral Walls of the Pelvis

- Obturator internus muscle
 - o Proximal attachment: pelvic surfaces of ischium and ilium and obturator membrane
 - o Distal attachment: greater trochanter of femur
 - o Innervated by nerve to obturator internus (L5, S1-S2)
 - o Lateral rotator of thigh
- Piriformis muscle
 - o Proximal attachment: pelvic surfaces of S2-4 segments of sacrum, sacrotuberous ligament
 - o Distal attachment: greater trochanter of femur
 - o Innervated by ventral rami of S1-S2 spinal nerves
 - o Lateral rotator of thigh

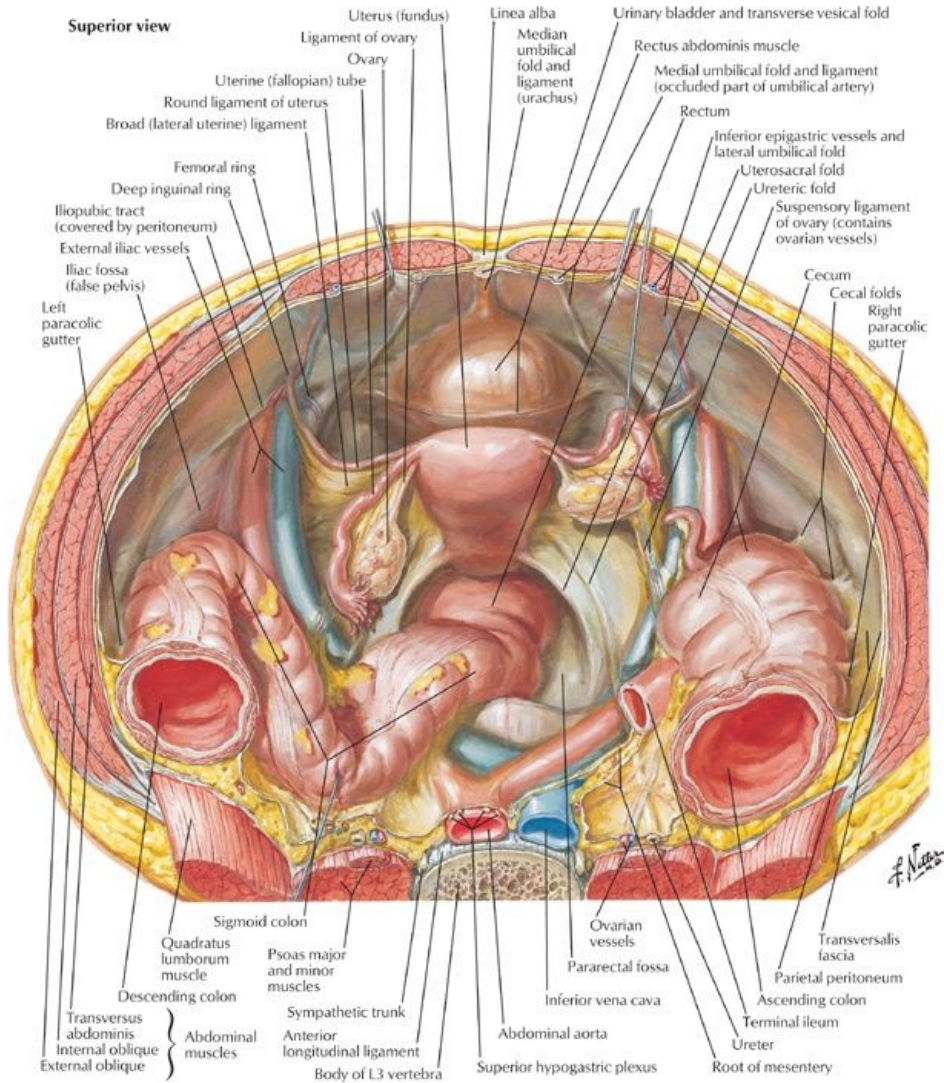
Muscle	Proximal Attachment (Origin)	Distal Attachment (Insertion)	Innervation	Main Actions
Obturator internus	Pelvic aspect of obturator membrane and pelvic bones	Greater trochanter of femur	Nerve of obturator internus	Rotates external thigh laterally; abducts flexed thigh at hip
Piriformis	Anterior surface of second to fourth sacral segments and sacrotuberous ligament	Greater trochanter of femur	Ventral rami of S1-S2	Rotates external thigh laterally; abducts flexed thigh; stabilizes hip joint
Levator ani	Body of pubis, tendinous arch of obturator fascia, and ischial spine	Perineal body, coccyx, anococcygeal raphe, walls of prostate or vagina, rectum, and anal canal	Ventral rami of S3-S4, perineal nerve	Supports pelvic viscera; raises pelvic floor
Coccygeus (ischiococcygeus)	Ischial spine and sacrospinous ligament	Inferior sacrum and coccyx	Ventral rami S4-S5	Supports pelvic viscera; draws coccyx forward

Pelvic Fascia

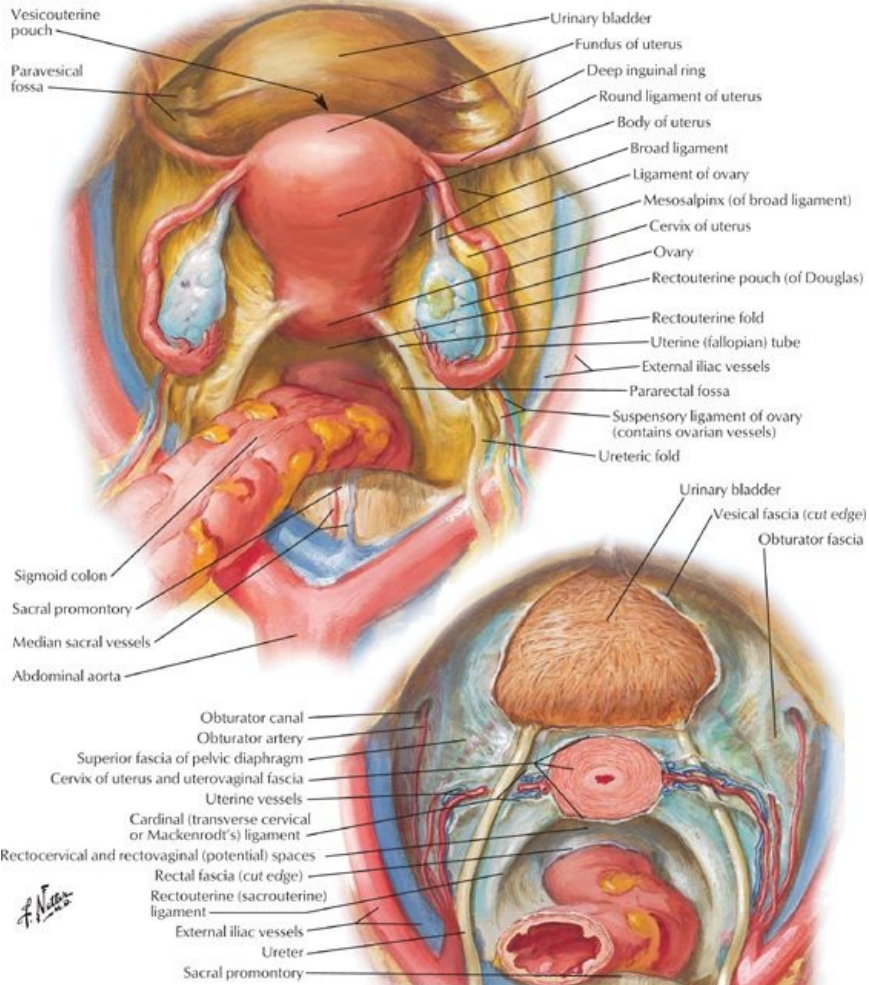
- Occupies space between peritoneum and muscles of the pelvic floor and walls
- Parietal pelvic fascia lines the internal surface (facing the pelvic cavity) of the muscles of the floor and walls
- Visceral pelvic fascia invests each of the pelvic organs
- Visceral and parietal fascia are continuous where organs penetrate pelvic floor
 - o Where they are continuous, fascia thickens to form the tendinous arch of pelvic fascia (arcus tendineus fasciae pelvis)
 - o Arches are bilateral bands running from pubis to sacrum, adjacent to viscera
- Puboprostatic ligament
- Pubovesical ligament
- Sacrogenital ligaments
- Between parietal and visceral fascia is endopelvic fascia
 - o Matrix or filler material
 - o In certain areas, condenses and becomes more fibrous to form fascial "ligaments" or septa
- Major condensation is the hypogastric sheath
 - o Runs from lateral pelvic wall to pelvic viscera
 - o Separates retropubic space from presacral space
 - o Serves as a conduit for vessels and nerves
- Transverse cervical (cardinal) ligaments are part of hypogastric sheath
 - o Runs from lateral wall to the uterine cervix and vagina
 - o Uppermost part is beneath broad ligament and transmits the uterine artery
 - o Is sufficiently fibrous to provide passive support for the uterus

- Uterosacral (female) or genitosacral (male) ligaments
- Septa separate the pelvic organs and include
 - Vesicovaginal septum
 - Rectovesical septum
 - Rectovaginal septum
- Weakness of the pelvic floor muscles or in the pelvic fascia, which support the pelvic organs, can result in prolapse of the pelvic organs, e.g., vaginal or rectal prolapse.

Pelvic Contents



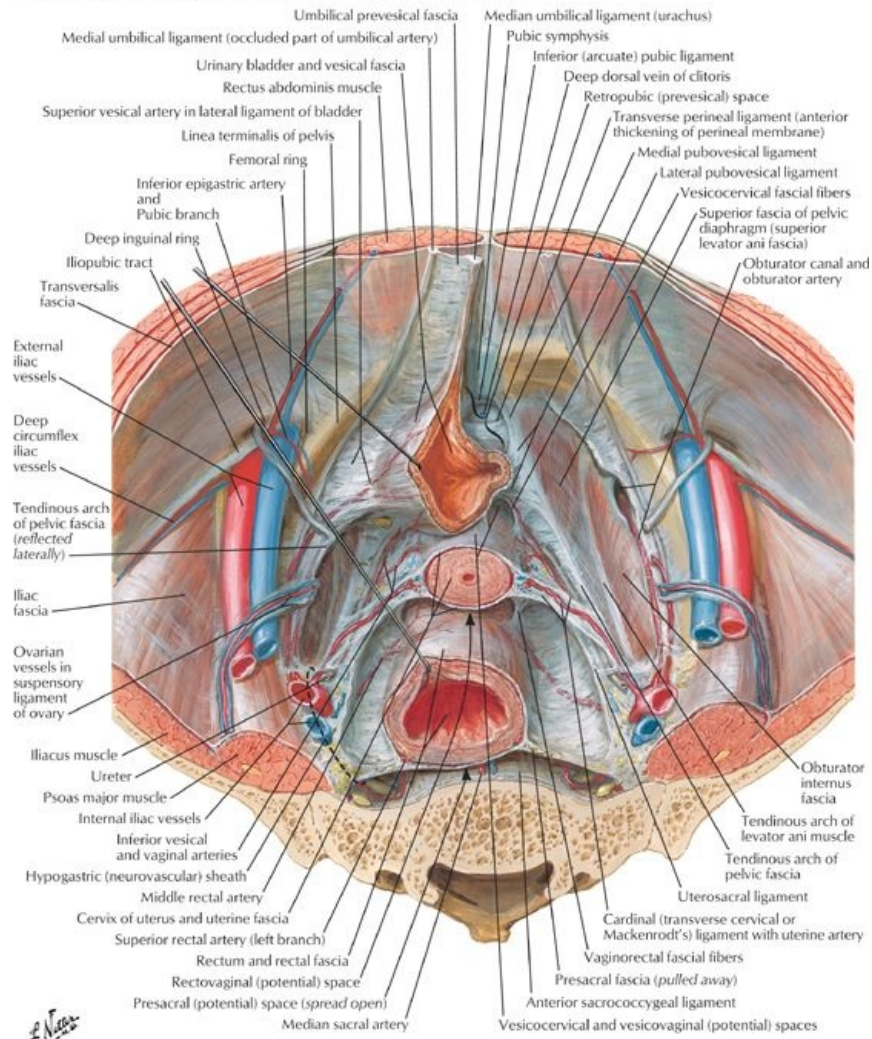
Superior view with peritoneum intact



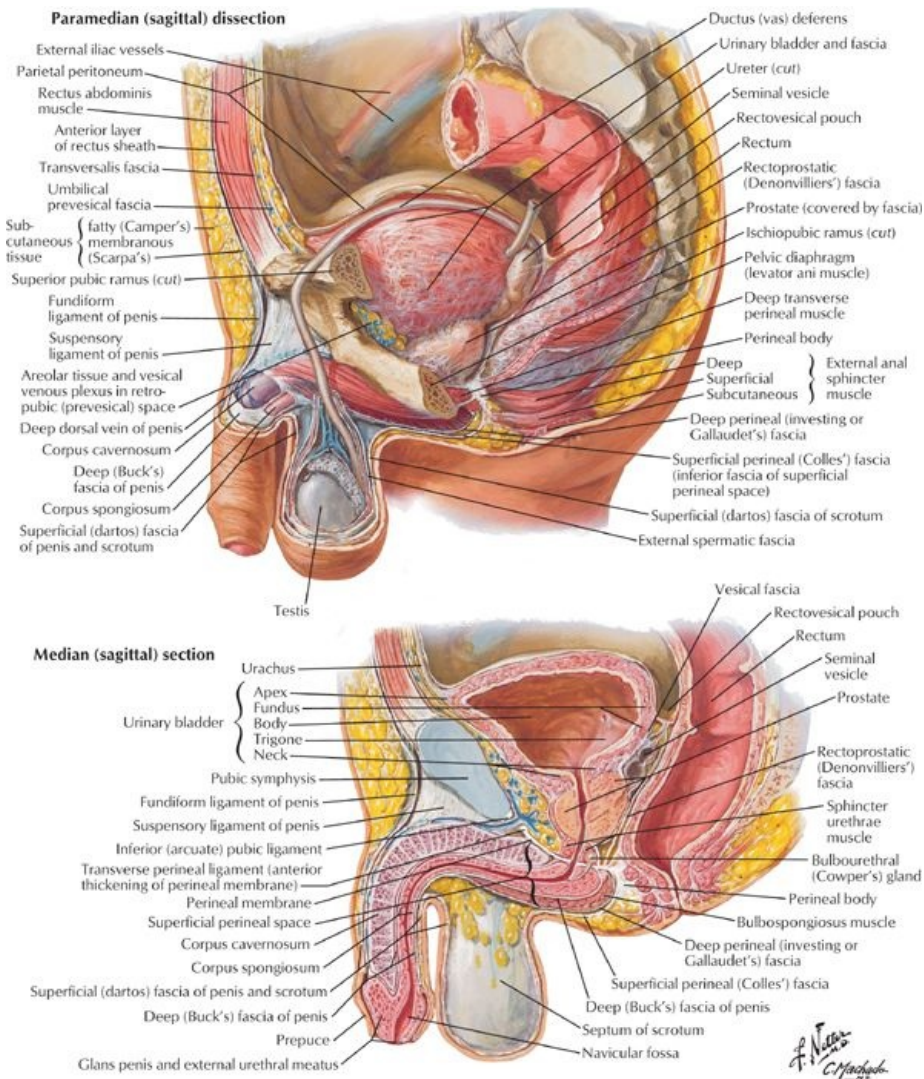
Superior view with peritoneum and uterus removed

[Plate 344, Pelvic Viscera: Female]

Female: superior view (peritoneum and loose areolar tissue removed)

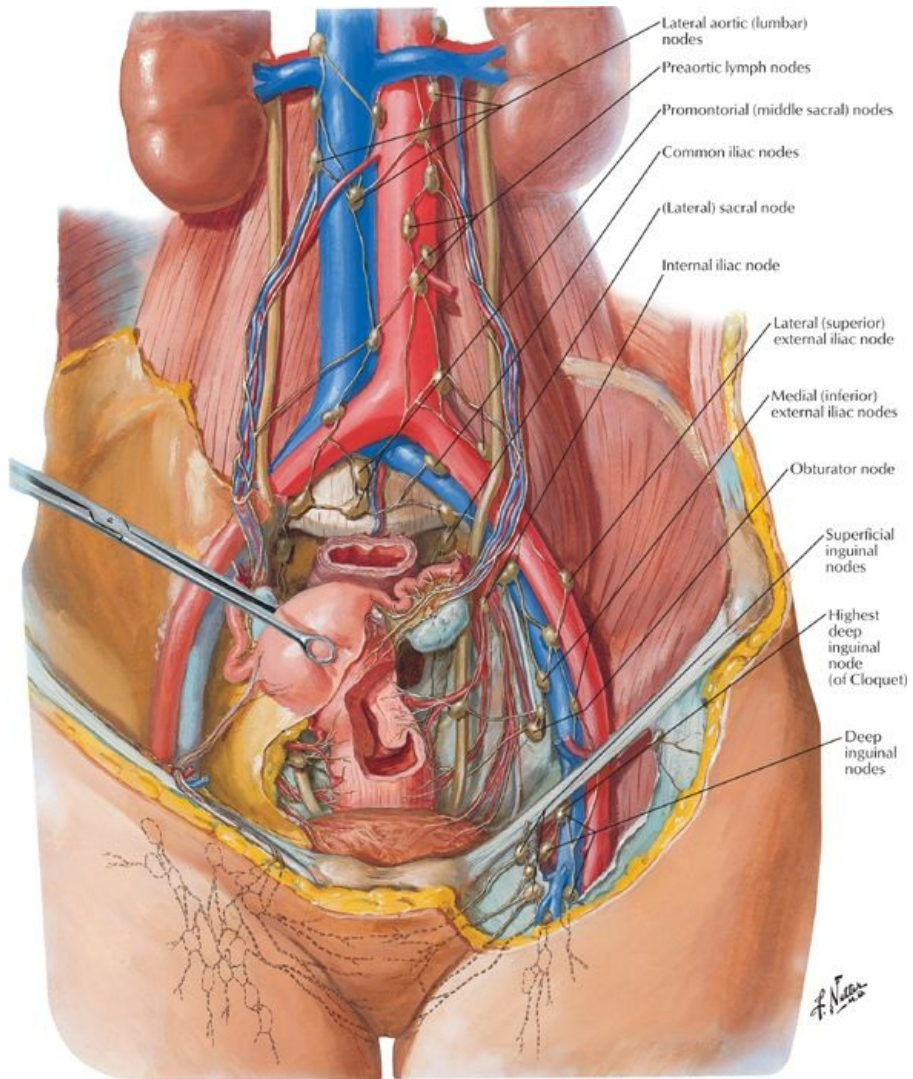


[Plate 345, Endopelvic Fascia and Potential Spaces]



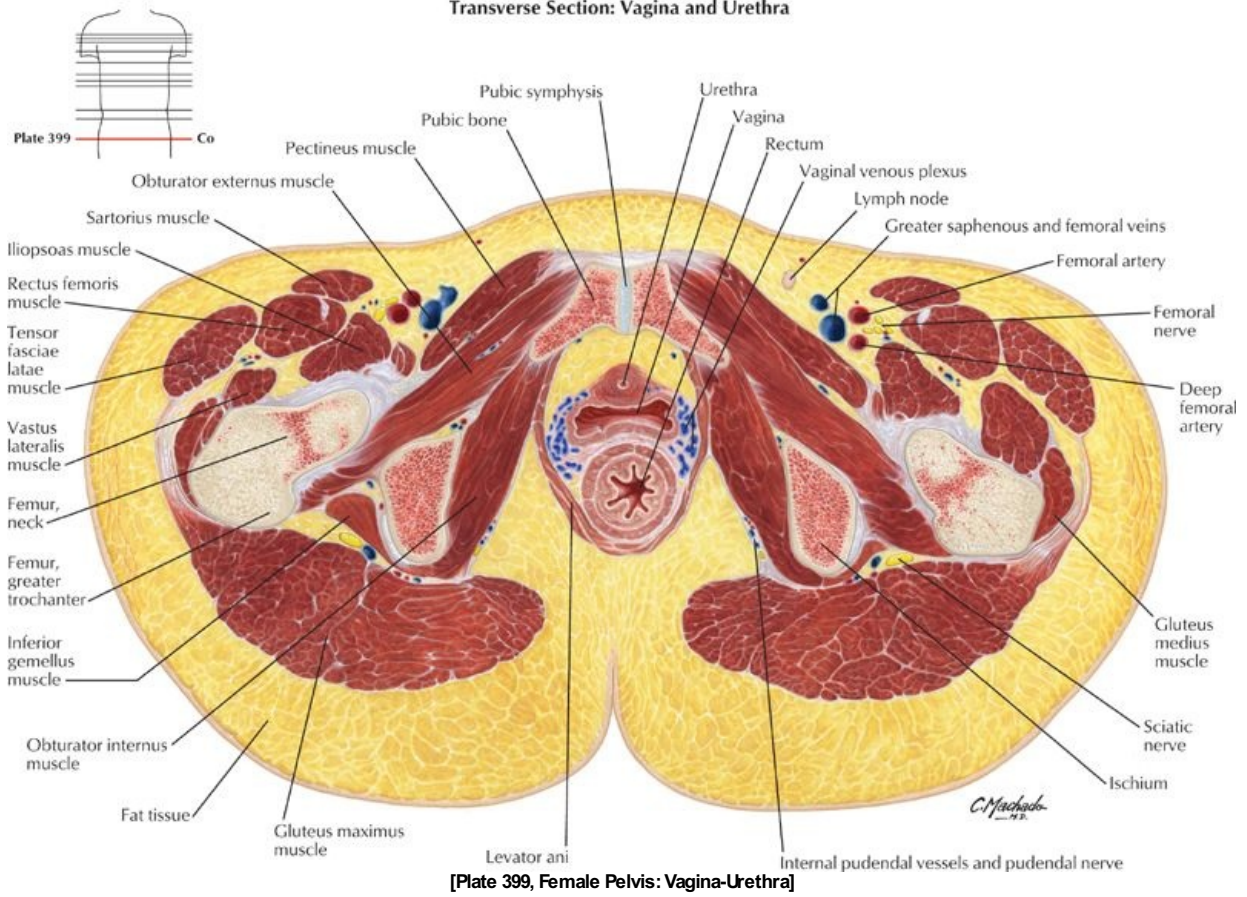
[Plate 346, Pelvic Viscera and Perineum: Male]

F. Netter M.D.
C. Manaraa



[Plate 386, Lymph Vessels and Nodes of Pelvis and Genitalia: Female]

Transverse Section: Vagina and Urethra



[Plate 399, Female Pelvis: Vagina-Urethra]

page 174
page 175

- **Female Pelvic Viscera and Perineum See:**
 - Section 5-4: Urinary Bladder
 - Section 5-5: Uterus, Vagina and Supporting Structures
 - Section 5-9: Rectum
- **Male Pelvic Viscera and Perineum See:**
 - Section 5-4: Urinary Bladder
 - Section 5-8: Testis, Epididymis, and Ductus Deferens
 - Section 5-9: Rectum

FACTS & HINTS

High-Yield Facts

Clinical Points

Peritoneal Reflections

- **Pelvic peritoneum**
 - Lines lateral and posterior pelvic walls and pelvic floor
 - Covers the rectum, urinary bladder, uterus, and adnexa in the female
 - Covers the anterior and lateral surfaces of the upper portion of the rectum in both sexes
- **In men:**
 - Sweeps forward from the rectum to the bladder
 - Creates a recess between the rectum and the bladder: the rectovesical pouch
 - Continues over the superior surface of the bladder and ascends on the internal side of the anterior abdominal wall
- **In women:**
 - Sweeps forward from the rectum onto the posterior fornix of the uterus and the posterior uterine wall
 - Creates a recess between the rectum and the uterus: the rectouterine pouch (of Douglas)
 - Covers the posterior, superior and anterior surfaces of the uterus before reflecting onto the superior surface of the bladder
 - Ascends on the internal side of the anterior abdominal wall
- Fluid (blood, pus) can collect in the rectovesical or rectouterine pouches causing an infection and forming pelvic abscesses.

35 Urinary Bladder

STUDY AIMS

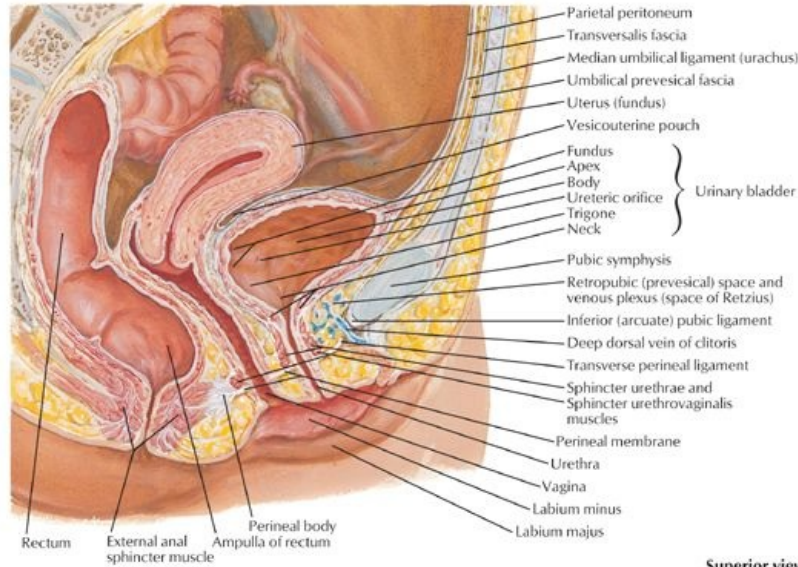
At the end of your study, you should be able to:

- Describe the course of the pelvic ureters
- Outline the gross structure of the bladder
- Describe the relations of the bladder
- Describe the structure of the male urethra
- Describe the structure of the female urethra

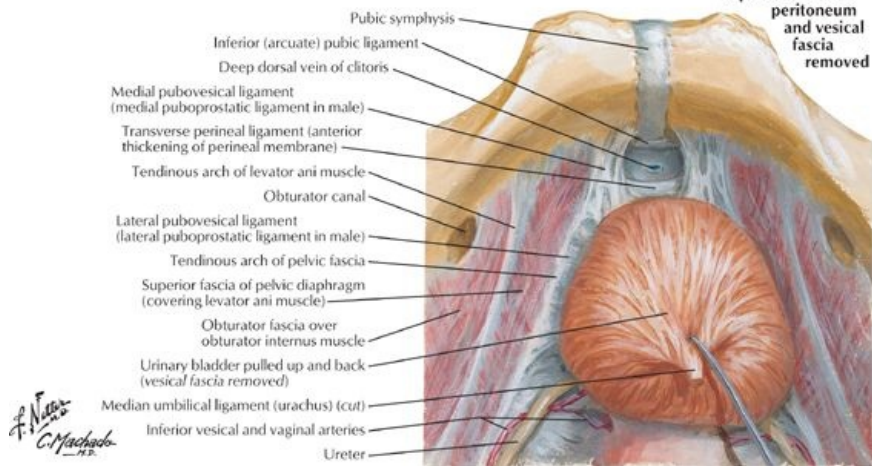
GUIDE

Pelvis and Perineum: Urinary Bladder

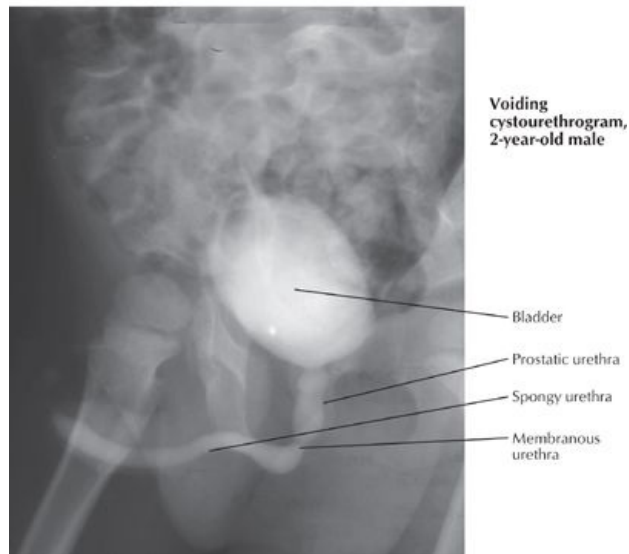
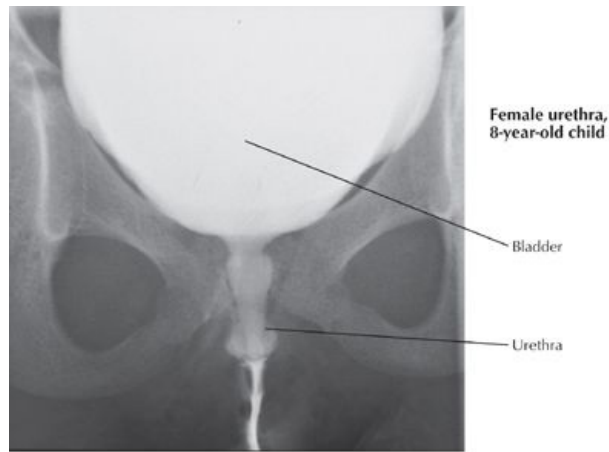
Female: midsagittal section



Superior view with peritoneum and vesical fascia removed



[Plate 348, Urinary Bladder: Orientation and Supports]



[Plate 351, Male and Female Cystourethrograms]

Ureters

- Cross pelvic brim at the level of sacroiliac joint, anterior to the bifurcation common iliac artery to pierce the posterior surface of the bladder
- Enters the posterolateral surface of the bladder and runs obliquely through the bladder wall, creating a flap valve
- In males: the ureter passes under the ductus deferens, superior to the seminal vesicles
- In women: the ureter descends posterior to the ovary and into the base of the broad ligament passing under the uterine artery ("water under the bridge")
- Supplied by branches of common and internal iliac arteries and uterine artery (inferior vesicle artery in males) and drained by veins with same names.
- Innervated by fibers from adjacent autonomic plexuses

Urinary Bladder

General structure

- Lies posterior to pubic bones and pubic symphysis
- When empty is tetrahedron in shape and lies entirely within true pelvic cavity; spherical when full and may reach as high as umbilicus
- When empty has a base (posterior surface) and a superior and two inferolateral surfaces.
- Base (posterior surface) of bladder defined internally by two ureteric openings at superolateral corners and internal urethral opening inferiorly
- Triangular area defined by these openings is the vesicle trigone
- Ridge between two urethral openings is the interureteric fold
- Neck of bladder is where base and inferolateral sides meet, inferiorly
- Anterior angle or apex is site of attachment of urachus-fibrous remnant of fetal allantois, which is seen as the median umbilical ligament on the anterior abdominal wall
- Bladder wall is composed of a thick layer of interwoven bundles of smooth muscle running transversely, longitudinally, and obliquely- detrusor muscle
- In region of neck, detrusor muscle runs circularly as involuntary internal sphincter
- Bladder mucosa is thrown into rugae except within trigone, which is smooth

Relations of the Urinary Bladder

Border	Structure
Superior	Peritoneum Ileum Sigmoid colon
Inferolateral	Obturator internus muscle Levator ani muscle Obturator nerve Obturator artery and vein Superior vesical artery and vein
Anterior	Retropubic space-containing adipose tissue and veins Pubic crest
Posterior-male	Seminal vesicles Ampulla of ductus deferens Rectovesical pouch Ampulla of rectum
Posterosuperior-female	Vesicouterine pouch Body of uterus
Posterior-female	Cervix Anterior wall vagina
Inferior-male	Prostate Prostatic venous plexus

Arterial supply

- Superior vesicle arteries (branches of internal iliac artery) supply apex and superior part of bladder
- Inferior vesical arteries supply fundus and neck in males
- Vaginal arteries (branches of uterine arteries) supply fundus and neck in females
- Obturator arteries (branches of internal iliac artery) provide arterial twigs

Venous drainage

- Vesical venous plexus drains to internal iliac plexus via inferior vesical veins
- Communicates with prostatic venous plexus in males and uterovaginal venous plexus in females

Female urethra

- Three- to 4-cm long fibromuscular tube, bound to anterior vaginal wall
- Extends from internal urethral meatus of bladder to external meatus situated just anterior to the vaginal opening in the vestibule
- Descends with vagina through urogenital hiatus and pelvic diaphragm and through perineal membrane where it is surrounded by external sphincter urethrae
- Paraurethral glands, homologs to the prostate, open on either side near external urethral orifice
- Supplied by internal pudendal and vaginal arteries
- Drained by veins of same name
- Innervated by branches of pudendal nerve via S2-S4 spinal cord segments and afferents run with pelvic splanchnic nerves

page 177
page 178

Male urethra

- Twenty-cm fibromuscular tube
- Conveys both urine and semen
- Extends from internal urethral meatus of bladder to external urethral meatus in glans penis
- Divided into three parts: prostatic; membranous and spongy urethra

Comparison of Prostatic, Membranous and Spongy Parts of the Male Urethra

	Prostatic Urethra	Membranous Urethra	Spongy Urethra
Length	3 cm	2 cm	15 cm
Extent	Internal urethral meatus to apex of prostate	Apex of prostate to perineal membrane	Bulb of penis to glans penis
Key Anatomical Features	Urethral crest (midline ridge) Prostatic sinuses (site of opening prostatic ducts) Prostatic utricle (blind-ending sac on urethral crest; remnant of fetal duct forming uterus in females) Ejaculatory duct (opens either side of the utricle)	Surrounded by striated muscle of external urethral sphincter Bulbourethral glands lie posterolaterally Pubic symphysis lies anteriorly attaching via pubourethral ligaments	
Blood Supply	Inferior vesical and rectal arteries	Inferior vesical and rectal arteries	Internal pudendal artery via dorsal arteries of penis
Venous Drainage	Veins of same names and prostatic venous plexus	Veins of same names and prostatic venous plexus	Prostatic venous plexus and internal pudendal veins
Nerve	Pudendal nerve (S2-S4) and prostatic plexus	Pudendal nerve (S2-S4) and	Pudendal nerve (S2-S4)

280 / 425

Supply

prostatic plexus

and prostatic plexus

FACTS & HINTS

High-Yield Facts

Clinical Points

Micturition

- The bladder has a capacity of 400 to 500 mL
- During micturition coordinated reflexive contraction of the detrusor and relaxation of the external urethral sphincter occur
- Controlled by autonomic and visceral innervation
 - Visceral afferent fibers traveling along tract of parasympathetic fibers stimulated by stretching (and pain in lower bladder)
 - Parasympathetic innervation via pelvic splanchnic nerves and pelvic plexus reflexively stimulates detrusor contraction during micturition.
 - Sympathetic fibers via hypogastric plexus to bladder neck relaxes bladder neck (internal urethral sphincter) and prevents retrograde ejaculation during micturition in males

page 178

page 179

Clinical Points

Fractures of the Pelvis and Bladder Injury

- The bladder lies immediately posterior to the pubic symphysis and fractures of the pubis can be complicated by rupture of the bladder.
- The rupture can result in the extravasation of urine intraperitoneally if the peritoneum is torn

Urinary Tract Infections (UTIs)

- As a result of a shorter urethra, women are more susceptible to UTIs
- Commonly occurs in women following sexual intercourse
- Pathogen is commonly *Escherichia coli*
- Infection may lead to urethritis, cystitis, or pyelonephritis (inflammation of urethra, bladder, and kidneys, respectively).
- Symptoms include: dysuria, urgency, frequency, and occasionally hematuria

Urinary Stress Incontinence

- Factors maintaining continence in the female are the external urethral sphincter (striated muscle surrounding middle third of urethra) and support of the bladder and urethra by the levator ani muscles
- Urinary stress incontinence is an involuntary loss of urine that occurs during coughing, sneezing, laughing, lifting, or exercise, because of the inability of these muscles to counter the increase in intra-abdominal pressure.
- Urinary stress incontinence is often seen in women who have had multiple pregnancies and vaginal childbirths and in men following prostate surgery
- About 50% of all women have occasional urinary incontinence

Mnemonics

Memory Aids

"Water under the bridge" -denotes relationship of ureter (**water**) to uterine artery, as it passes under the artery.

36 Uterus, Vagina and Supporting Structures

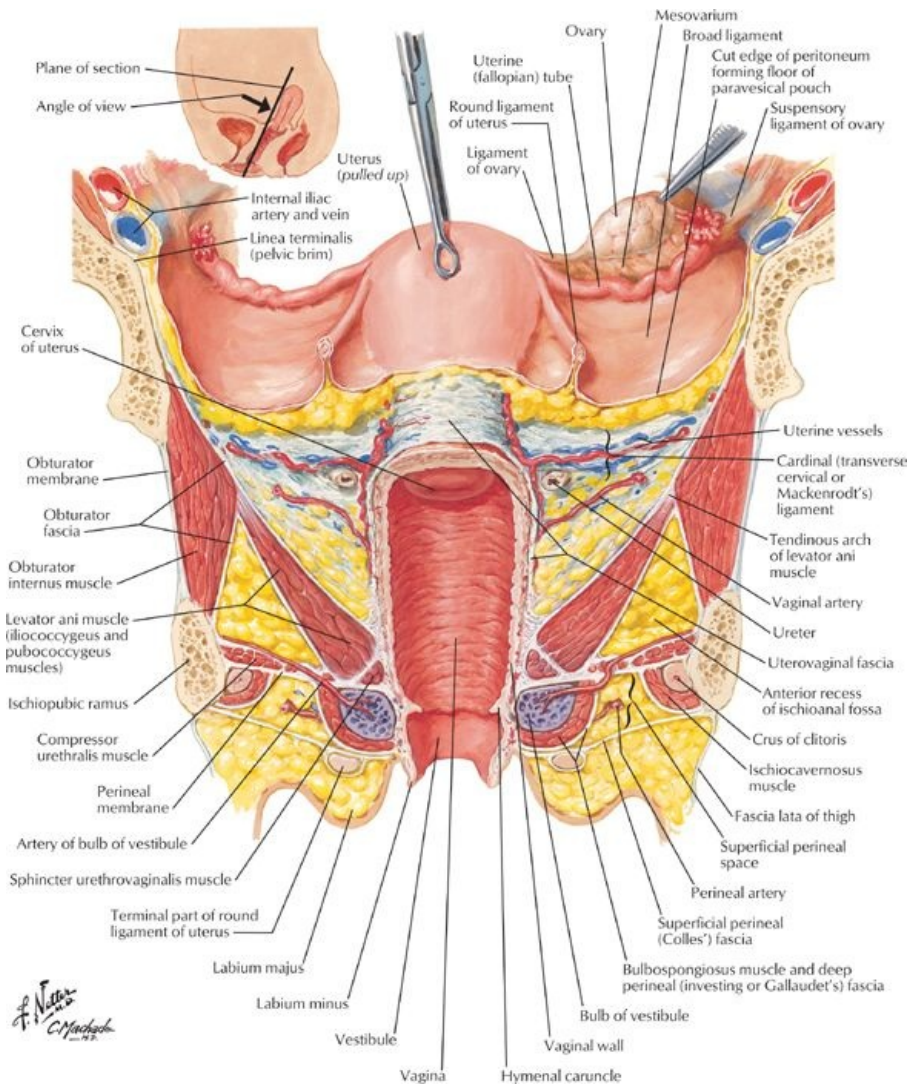
STUDY AIMS

At the end of your study, you should be able to:

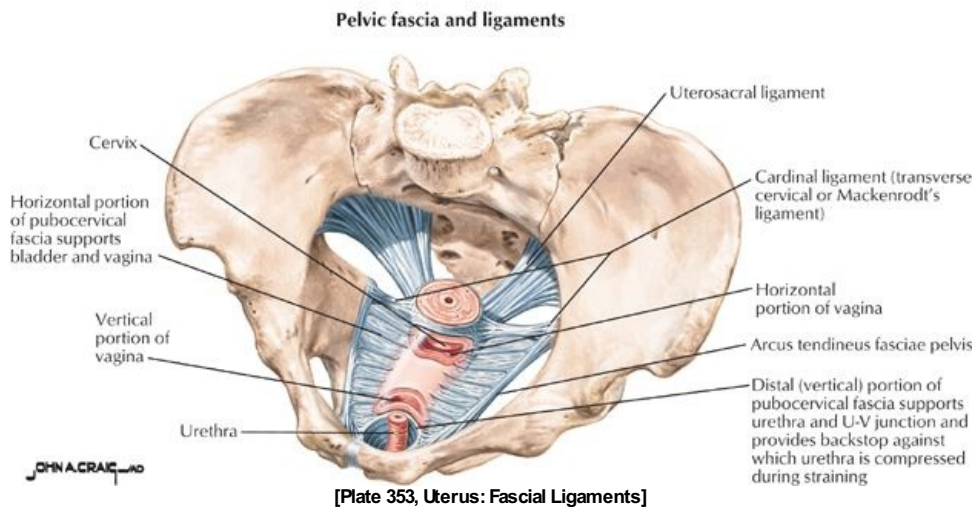
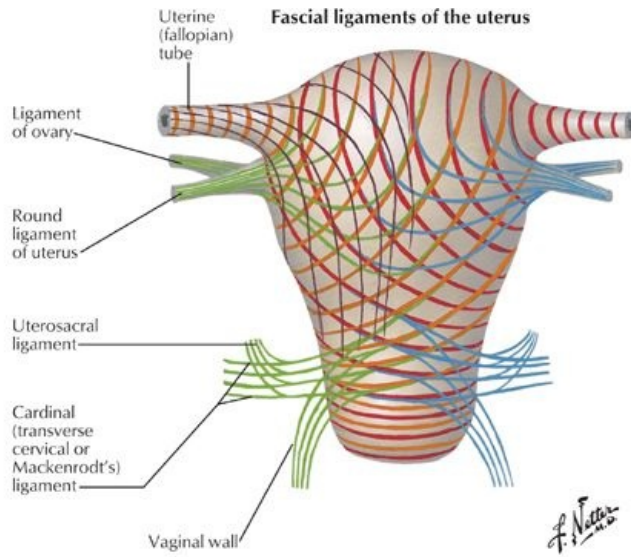
- Describe the anatomy of the uterus and its supporting ligaments
- Know the anatomy of the ovary and the uterine tubes in relation to the pelvic cavity, the peritoneum, and the uterus
- Know the anatomy of the cervix
- Understand the orientation of the cervix relative to the position of the uterus and changes with childbirth
- Understand the anatomy of the vagina

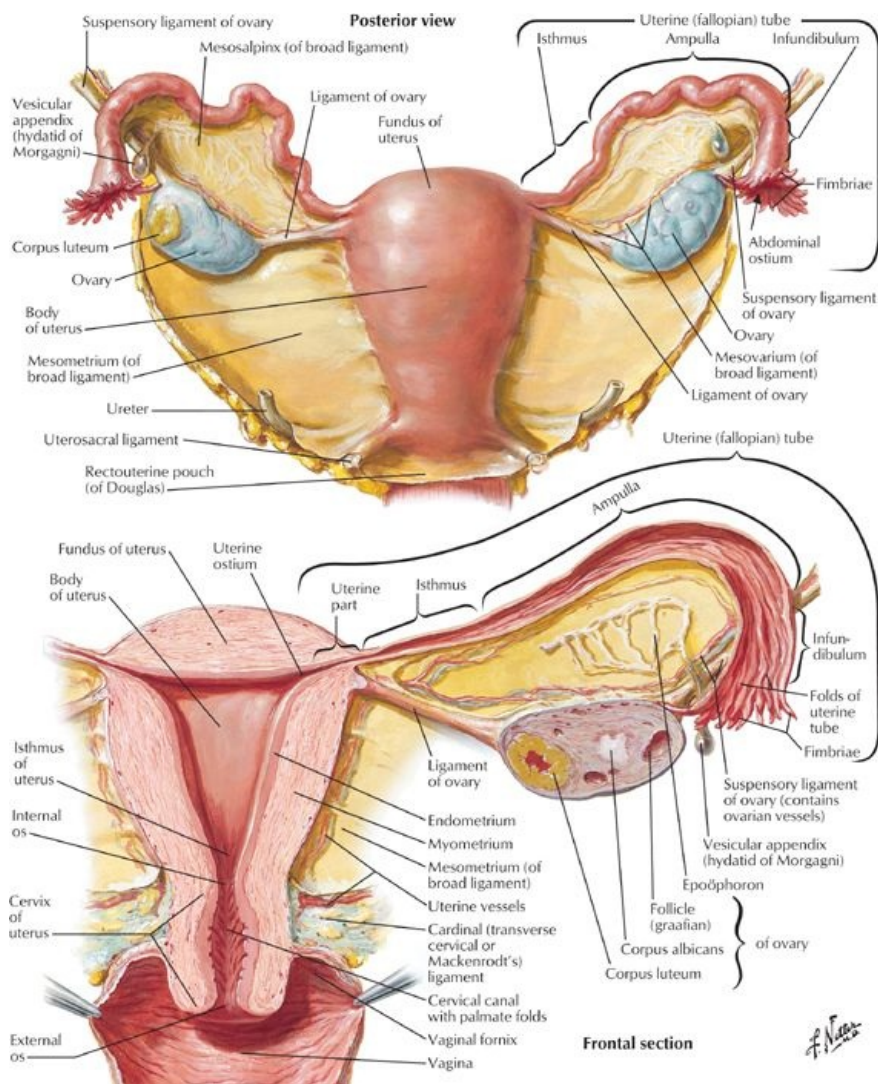
GUIDE

Pelvis and Perineum: Uterus, Vagina, and Supporting Structures



[Plate 352, Uterus, Vagina and Supporting Structures]





[Plate 355, Uterus and Adnexa]

Uterus

Basic structure

page 180
page 181

- Pear-shaped organ
- Approximately 8 cm long and 5 cm wide
- Supported by the pelvic diaphragm
- Composed of
 - Body (corpus) - upper two thirds
 - Fundus - rounded upper part superior to the entrances of the uterine tubes
 - Isthmus - narrower area just above the cervix
 - Cervix (neck) - cylindrical inferior part that projects into the superior vagina
- Uterine cavity is small (6 cm in length) and slit-like
- Uterine horns are superolateral regions where the uterine (Fallopian tubes) enter
- Uterine wall has three layers
 - Perimetrium - outer layer of peritoneum with underlying connective tissue
 - Myometrium - middle, thick layer of smooth muscle
 - Endometrium - vascular inner mucosal layer the thickness of which varies with menstrual cycle and age
- The uterus has two surfaces: anteroinferior and posterosuperior
- A portion of the cervix, body, and fundus of the uterus is covered with peritoneum
- Cervix
 - Thick-walled canal, 2.5 cm long, connecting the body of the uterus with the vagina
 - Communicates superiorly via internal os with uterus
 - Communicates with vagina inferiorly via external os
 - Approximately half of the cervix lies above the vagina (supravaginal) and is covered posteriorly with the peritoneum of the rectouterine pouch
 - The bladder is separated from the anterior surface of the supravaginal part of the cervix by connective tissue
 - The lower half of the cervix (vaginal part) protrudes into the vagina and can be examined clinically

Relationships of the uterus

Laterally-	Broad ligament, transverse cervical (cardinal ligaments), ureters
------------	---

286 / 425

Anterior-	Vesicouterine pouch, superior surface of bladder
Posterior-	Rectouterine pouch and anterior surface of rectum, loops of intestine in pouch

Vascular supply of uterus (including cervix)

- Arterial
 - Uterine arteries (branches of internal iliac arteries)
 - Vaginal arteries (branches of uterine arteries with anastomoses with internal pudendal arteries)
- Venous drainage: via uterine venous plexus to internal iliac veins
- Lymphatics drain to
 - External iliac nodes
 - Internal iliac and sacral nodes
 - Superficial inguinal nodes (along round ligament)

Innervation

- From the uterovaginal plexus, a subdivision of the inferior hypogastric (pelvic) plexus
- Sympathetic, parasympathetic, and visceral afferents to and from the uterus pass through this plexus
- Sympathetic innervation from lower lumbar spinal cord segments via lumbar splanchnic nerves and intermediate plexuses
- Parasympathetic innervation from pelvic splanchnic nerves (S2,3,4 spinal cord levels) via pelvic plexus
- Afferent fibers with pain information from body and fundus ascend through plexuses to lumbar splanchnic nerves to reach upper lumbar/lower thoracic spinal cord segments
- Afferent fibers with pain information from cervix and all information except for pain from body and fundus follow parasympathetic fibers back to central nervous system

Vagina

Basic structure

- Muscular tube, 8 to 10 cm long
- Superior end surrounds the cervix: upper two thirds lie within pelvic cavity
- Slopes downward and forward through the pelvic diaphragm
- Opens inferiorly into vestibule between labia minora
- Lining has multiple transverse folds-rugae
- Recessed area of vagina around the cervix is called the vaginal fornix; composed of shallow anterior, deep posterior, and lateral fornices
- Posterior fornix directly related to rectouterine pouch

Relationships of the vagina

Superior	External os cervix
Inferior	Vestibule between labia minora
Anterior	Posterior wall bladder
Posterior	Rectouterine pouch Ampulla of rectum
Lateral	Levator ani muscles

Blood supply

- Uterine arteries supplies superior part
- Vaginal arteries supply middle part
- Lower part supplied by middle rectal and internal pudendal arteries

Venous drainage

Vaginal venous plexus to uterine venous plexus to internal iliac veins

Innervation

- Upper three fourths same as uterus
- Lower one fourth is somatic via the pudendal nerve
- Visceral and sympathetic fibers reach the lower one fourth via the pudendal nerve; no parasympathetics

Variations in Position of the Uterus

- When the bladder is empty, body of the uterus bent anteriorly on the cervix: ante flexion
- Axis of cervix also bent forward relative to axis of vagina: ante version
- Thus the body of uterus lies on superior surface bladder
- Full bladder reduces these angles
- Reversal of these angles is called retroversion and retroflexion

Ligaments Associated with the Uterus

Broad ligament

- Double layer of peritoneum that sweeps up and over the uterus, ovaries, and the uterine tubes
 - Thus has an anterior and a posterior lamina
 - Extends from the sides of the uterus to the lateral pelvic walls

- Part that suspends the ovary from the posterior lamina is the mesovarium
- Part of broad ligament above the level of the ovary and mesovarium that sweeps over the uterine tubes is the mesosalpinx
- Part of broad ligament below the mesovarium or the mesentery of the uterus
- Uterine arteries and veins run medially from the internal iliac arteries to the uterus at its base
- Encloses the plexus of uterine veins

Ligament of the ovary

- Extends from the medial pole of ovary to the lateral wall of the uterus, just beneath the entrance of the uterine tube, on each side
- Remnant of proximal part of embryonic gubernaculum

page 182

page 183

Round ligament of the uterus

- Extends from the lateral wall of the uterus, just beneath the entrance of the uterine tube, to the lateral pelvic wall on each side
- Crosses external iliac vessel to enter deep inguinal ring
- Passes through inguinal canal to labium majus
- Remnant of distal part of embryonic gubernaculum

Suspensory ligament of the ovary

- An extension of the broad ligament superiorly on the posterolateral pelvic wall
- Covers the ovarian vessels, associated nerves, and lymphatics

Uterine (Fallopian) Tubes

Basic anatomy

- Approximately 10 cm long, extending laterally from the uterine horns to the peritoneal cavity near the ovaries
- Run in free upper border of broad ligament (mesosalpinx)
- Provide a channel for ova from ovary to uterine cavity and site for fertilization
- Divided into four parts for descriptive and functional purposes
 - Infundibulum
 - Horn-shaped distal end
 - Opens into peritoneal cavity
 - Has finger-like processes (fimbriae) at distal end that spread over surface of ovary
 - Ampulla
 - Widest and longest part
 - Where fertilization usually occurs
 - Connects infundibulum and isthmus
 - Isthmus
 - Thick-walled
 - Enters uterine horn
 - Uterine part: passes through the wall of the uterus

Blood supply

- Arterial (anastomoses)
 - Uterine arteries
 - Ovarian arteries
- Venous drainage
 - Uterine venous plexus
 - Ovarian veins

Lymphatics

To lumbar lymph nodes

Innervation

Ovarian and uterine plexuses = subdivisions of pelvic plexus

page 183

page 184

Ovaries

Basic structure

- Ovoid in shape
- Approximately 4 cm long and 2 cm wide
- Lie in the ovarian fossa on lateral pelvic wall between external and internal iliac vessels
- Attached to the broad ligament by mesovarium, which transmits ovarian vessels
- Connected to lateral wall by suspensory ligaments of the ovary, containing ovarian vessels, nerves, and lymphatics

Arterial supply

- Ovarian artery

-
- Branch of abdominal aorta
 - Terminates in ovarian and tubal branches

Venous drainage

- Pampiniform plexus combines to form single ovarian vein
- On right this drains into the inferior vena cava
- On the left drains into the left renal vein

Lymphatics

Follow ovarian vessels to lumbar lymph nodes

Innervation

- Sympathetic and afferent fibers reach the ovary via the ovarian vessels
- Parasympathetic fibers from pelvic splanchnic nerves (S2,3,4 spinal cord levels) reach ovary via same route

FACTS & HINTS

High-Yield Facts

Clinical Points

page 184

page 185

- The thickness of the endometrium (vascular mucosal lining) changes throughout the menstrual cycle, undergoing thickening and shedding.
- Following menopause the uterus and vagina undergo atrophy
- Because the upper two thirds of the vagina lie within the pelvic cavity, weakness of the pelvic floor muscles can lead to vaginal prolapse.
- The lumen of fallopian tubes communicates with the peritoneal cavity at its distal (ovarian) end.
- The ovary is covered only by a thin layer of mesothelium, an extension of the mesovarium, to permit ovulation of the mature ovum into the peritoneal cavity.
- Ectopic pregnancies are therefore possible within the peritoneum.
- Fertilization of an ovum usually occurs within the fallopian tubes at the ampulla (the widest part)
- Ectopic pregnancies-implantation of a blastocyst other than in the uterine wall-can occur in the uterine tube (tubal pregnancy-most common ectopic pregnancy), into the ovary (ovarian pregnancy-rare) or into the abdominal wall (peritoneal pregnancy-very rare)
- Blockage of the uterine tubes as the result of disease is a common cause of infertility

Clinical Points

Cervical Cancer

- Common between age 40 and 60 years
- Was the leading cause of death of women in the United States until 1940, when detection of malignancies and premalignant conditions was made possible by the development of Pap (Papanicolaou) smears.
- Risk factors include: early sexual activity, multiple sexual partners, human papillomavirus infection, and smoking
- Eighty-five percent to 90% are squamous cell carcinomas; 10% to 15% are adenocarcinomas

Fibroids

- Benign tumors of smooth muscle cells of uterine myometrium
- Occur in 30% all women
- Can occur in any location within the uterus
- Growth stimulated by estrogen and oral contraceptive pill
- Symptoms usually a result of compression effects

37 Perineum and External Genitalia: Female

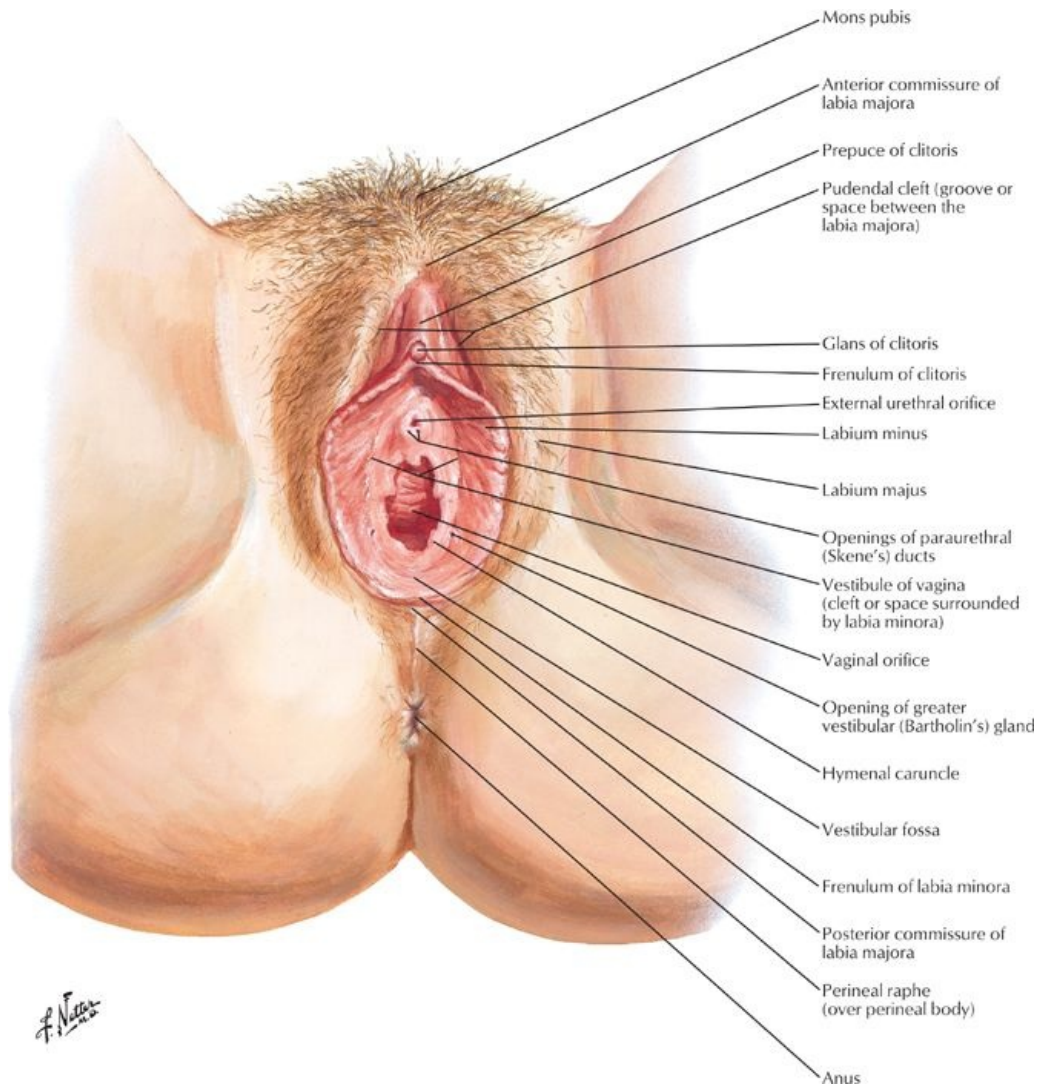
STUDY AIMS

At the end of your study, you should be able to:

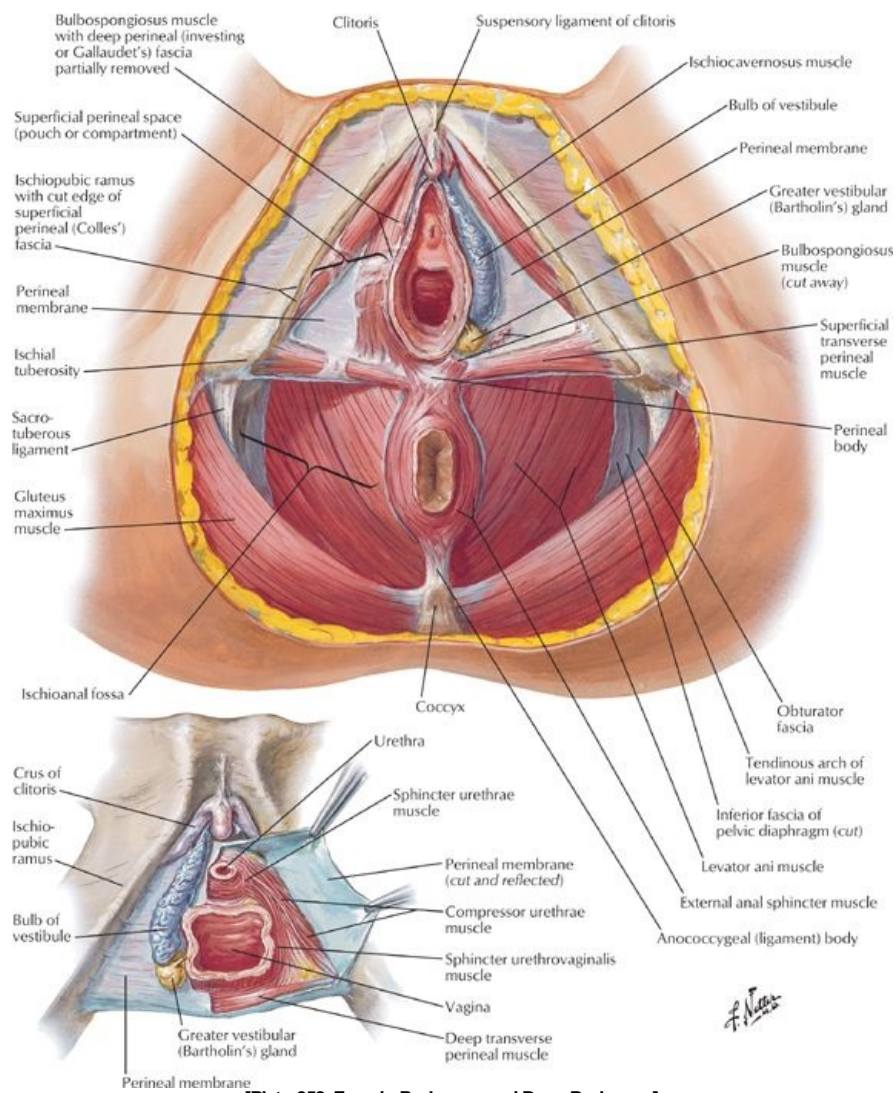
- Outline the general organization of the perineum
- Describe the contents of the urogenital and anal triangles
- Describe the central perineal tendon and perineal membrane
- Outline the fascial layers and spaces of the perineum
- Describe the anatomy of the clitoris, labia, and vestibule
- Outline the blood supply of the external genitalia
- Outline the innervation of the female external genitalia

GUIDE

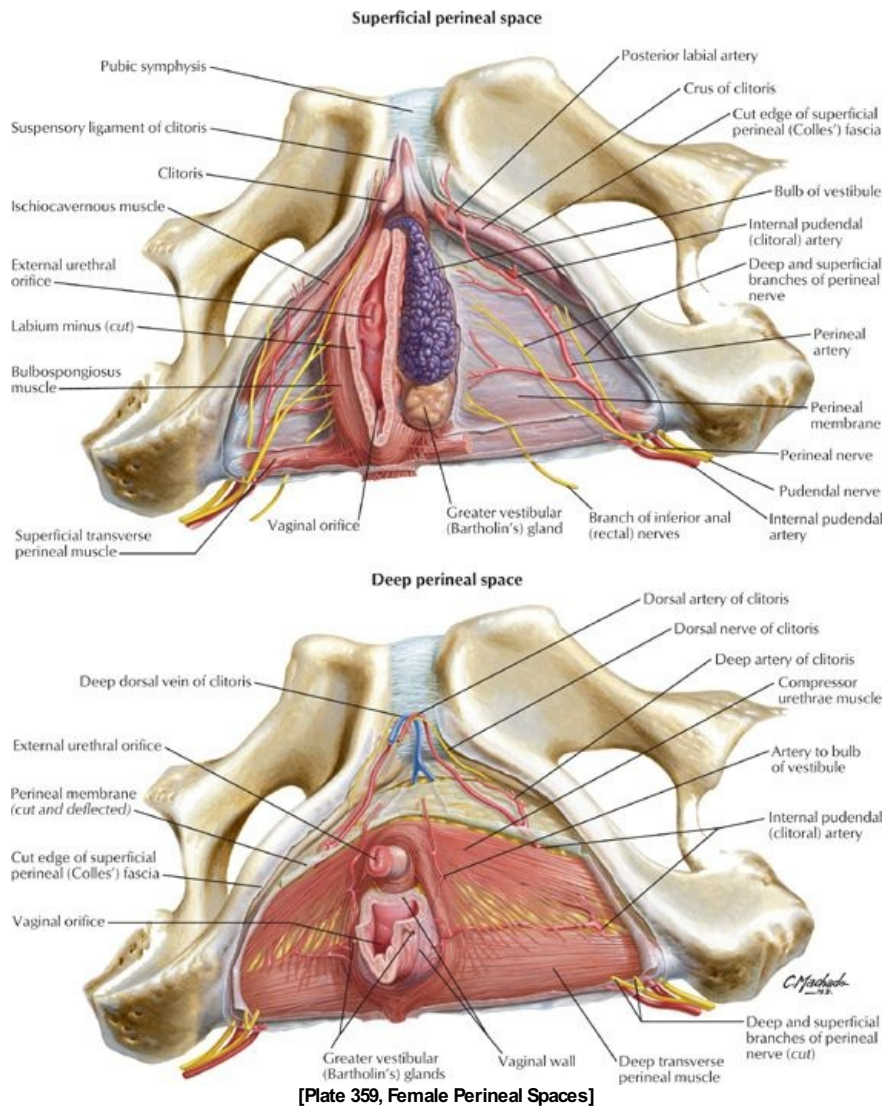
Pelvis and Perineum: Perineum and External Genitalia: Female



[Plate 356, Female Perineum and External Genitalia (Pudendum or Vulva)]



[Plate 358, Female Perineum and Deep Perineum]



Perineum

General organization (Same as male)

- Narrow region between superior medial aspects of thigh
- With lower limbs abducted in lithotomy position, becomes a diamond-shaped area
- Bounded by pelvic diaphragm superiorly and superficial fascia and skin inferiorly
- Anal canal, urethra, and vagina pass through the perineum
- Boundaries:
 - Anteriorly: Pubic symphysis
 - Posteriorly: Inferior sacrum and coccyx
 - Anterolaterally: Ischiopubic rami
 - Laterally: Ischial tuberosities
 - Posterolaterally: Sacrotuberous ligaments
- Divided into two triangles by imaginary line between ischial tuberosities
- Posteriorly is anal triangle
- Anteriorly is urogenital triangle

Contents of the anal triangle (Same as male)

- Anal canal and anus
- External and internal anal sphincters
- Ischiorectal fossa

Contents of urogenital triangle

- Membranous and distal urethra
- Vagina
- Vulva (labia majora, labia minora, and clitoris)
- Erectile bodies of vulva

Central perineal tendon (perineal body) (Same as male)

- Located at midpoint of the line dividing the urogenital from anal triangles
- Mass of collagenous and elastic fibers
- Deep to skin
- Anterior to anal canal
- Posterior to bulb of the penis (male) or vestibule (female)
- Site of attachment for
 - Bulbospongiosus
 - Superficial transverse perineal muscles
 - Deep transverse perineal muscles
 - External anal sphincter
 - Fascicles of muscle from external sphincter urethrae and levator ani

Perineal membrane

- Everything same as male, except
- Sphincter urethrae (external urethral sphincter)
 - May exist in females
 - Some fibers extending to the ischiopubic rami (compressor urethrae) and some encircling the vagina as well
- Pierced by vagina and urethra

Fascia and spaces of the urogenital triangle

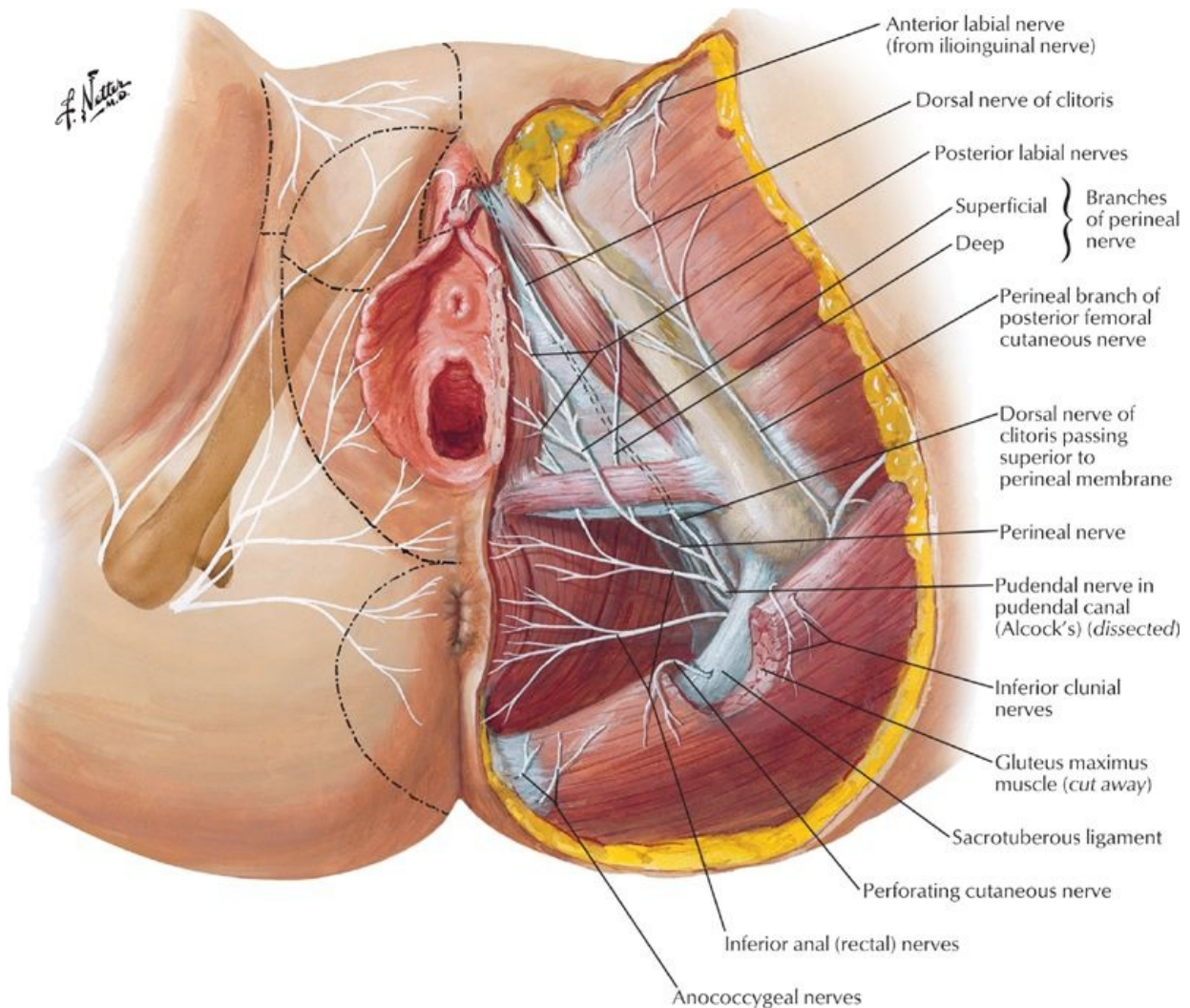
- Everything same as male, except
- Superficial perineal space (pouch)
 - Between membranous layer of superficial fascia and perineal membrane
 - Contains:
 - Crura of clitoris and associated muscles
 - Bulbs of vestibule and associated muscles
 - Superficial transverse perineal muscles
 - Branches of internal pudendal vessels and pudendal nerves
 - Greater vestibular glands
- Deep perineal space (pouch)
 - Lies between perineal membrane and pelvic diaphragm
 - Ischioanal fossae extend anteriorly into this space
 - Contains:
 - Proximal part of urethra
 - External sphincter urethrae muscle
 - Deep transverse perineal muscles
 - Vessels and nerves

Female External Genitalia**Anatomical features**

- Female external genitalia collectively called the vulva
- Female external genitalia include
 - Mons pubis
 - Labia majora
 - Labia minora
 - Clitoris
 - Vestibule of vagina
 - Bulbs of vestibule
 - Greater vestibular glands
- Mons pubis
 - Fatty tissue lying anterior to pubic symphysis and superior pubic rami
 - Skin continuous with anterior abdominal wall
 - After puberty is covered with pubic hair
- Labia majora
 - Longitudinal folds of skin containing fat, smooth muscle, and termination of round ligament of uterus
 - Lie on either side of pudendal cleft
 - Externally contain sebaceous glands and are covered by pubic hair
 - Internally are smooth and hairless
 - Unite anteriorly as the anterior commissure
 - Form a posterior commissure posteriorly, which disappears after childbirth
- Labia minora
 - Longitudinal folds of hairless skin without fat enclosed by labia majora
 - Surrounds vestibule of vagina
 - Extend from clitoris around urethra and vagina
 - Meet anteriorly as a small fold = frenulum of the clitoris, which passes deep to the clitoris
 - Posteriorly unite as frenulum (fourchette)
- Vestibule
 - Region enclosed by labia minora

- Contains external urethral meatus, vaginal introitus (most inferior opening) and opening of ducts of paraurethral gland
- Contains opening of ducts of greater vestibular (Bartholin's) glands
 - One gland on either side of vestibule
 - Posterior to vaginal orifice
 - Ductal openings either side of vagina; secrete mucus during sexual arousal
- Contains bulbs of vestibule
 - Elongated masses of erectile tissue
 - One on either side of vaginal introitus
 - Homologous to bulb of penis and corpus spongiosum
- Clitoris
 - Resembles inverted V
 - Composed of root and body, located where labia minora meet anteriorly
 - Lies 2 cm anterior to external urethral meatus
 - Body composed of two crura, two corpora cavernosa, and glans clitoris
 - Highly innervated, becomes engorged during sexual arousal
 - Prepuce of clitoris-anterior extension of labia minora

Vascular supply and innervation



[Plate 393, Nerves of Perineum and External Genitalia: Female]

- Arterial supply
 - External pudendal arteries (branches of femoral artery)
 - Internal pudendal arteries
 - Labial and clitoral branches of internal pudendal artery
- Venous drainage
 - Internal pudendal vein
 - Venae comitantes of internal pudendal artery

Lymphatic drainage

To superficial inguinal nodes

Innervation

-
- Anterior labial nerves from ilioinguinal nerve
 - Perineal branch from posterior femoral cutaneous nerve
 - Posterior labial nerves from pudendal nerve

FACTS & HINTS

High-Yield Facts

Clinical Points

Bartholin cyst

- Cystic swelling of greater vestibular (Bartholin's) glands
- Occurs when gland is infected or duct is blocked
- Can enlarge to 4 to 5 cm

Carcinoma of the vulva

- Mimics chronic ulcer
- Patient presents with pain, a discharging ulcer and occasionally a lump
- Metastasis is to inguinal lymph nodes
- Greater vestibular gland is origin of most vulvular adenocarcinomas

Childbirth and the perineal body

- Overt or occult tearing of perineal body results in permanent weakness of pelvic floor
- Can involve tearing of posterior vaginal wall and overlying skin
- Slow to heal because of lack of vascular supply
- Episiotomy done if tearing of perineum is predicted
- Incision usually made from posterior vaginal wall through midline to just anterior to anus

38 Perineum and External Genitalia: Male

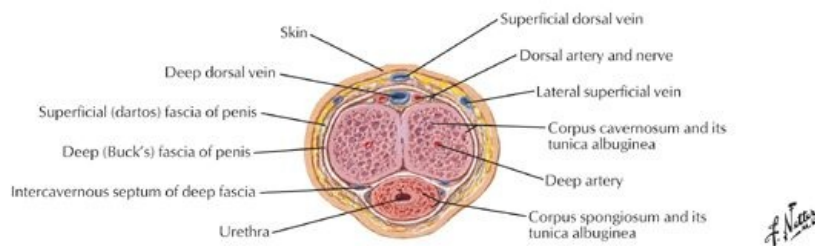
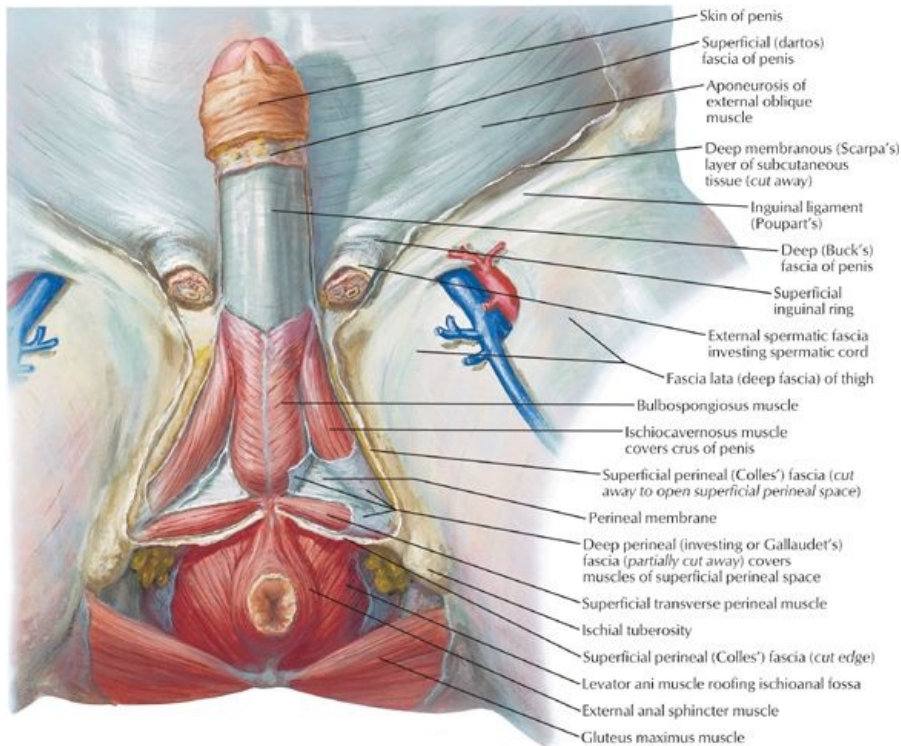
STUDY AIMS

At the end of your study, you should be able to:

- Outline the general organization of the perineum
- Describe the contents of the urogenital and anal triangles
- Describe the central perineal tendon and perineal membrane
- Outline the fascial layers and spaces of the perineum
- Describe the anatomy of the scrotum
- Describe the anatomy of the penis

GUIDE

Pelvis and Perineum: Perineum and External Genitalia: Male



Transverse section through body of penis
[Plate 361, Male Perineum and External Genitalia (Deeper Dissection)]

Perineum

General organization (Same as female)

- Narrow region between superior medial aspects of thigh
- With lower limbs abducted in lithotomy position, becomes a diamond-shaped area
- Bounded by pelvic diaphragm superiorly and superficial fascia and skin inferiorly
- Anal canal, urethra, and vagina (females) pass through the perineum
- Boundaries:
 - Anteriorly: Pubic symphysis
 - Posteriorly: Inferior sacrum and coccyx
 - Anterolaterally: Ischiopubic rami
 - Laterally: Ischial tuberosities
 - Posterolaterally: Sacrotuberous ligaments
- Divided into two triangles by imaginary line between ischial tuberosities
- Posteriorly is anal triangle
- Anteriorly is urogenital triangle

Contents of anal triangle (Same as female)

- Anal canal and anus
- External and internal anal sphincters
- Ischiorectal fossa

Contents of urogenital triangle

- Membranous and spongy urethra (males); distal urethra (females)

- Vagina (females)
- Proximal erectile bodies of the penis (males) and vulva (females)
- Attachment of the scrotum

page 190
page 191

Central perineal tendon (perineal body) (Same as female)

- Located at midpoint of the line dividing the urogenital from anal triangles
- Mass of collagenous and elastic fibers
- Deep to skin
- Anterior to anal canal
- Posterior to bulb of the penis (male) or vestibule (female)
- Site of attachment for
 - Bulbospongiosus
 - Superficial transverse perineal muscles
 - Deep transverse perineal muscles
 - External anal sphincter
 - Fascicles of muscle from external sphincter urethrae and levator ani

Perineal membrane

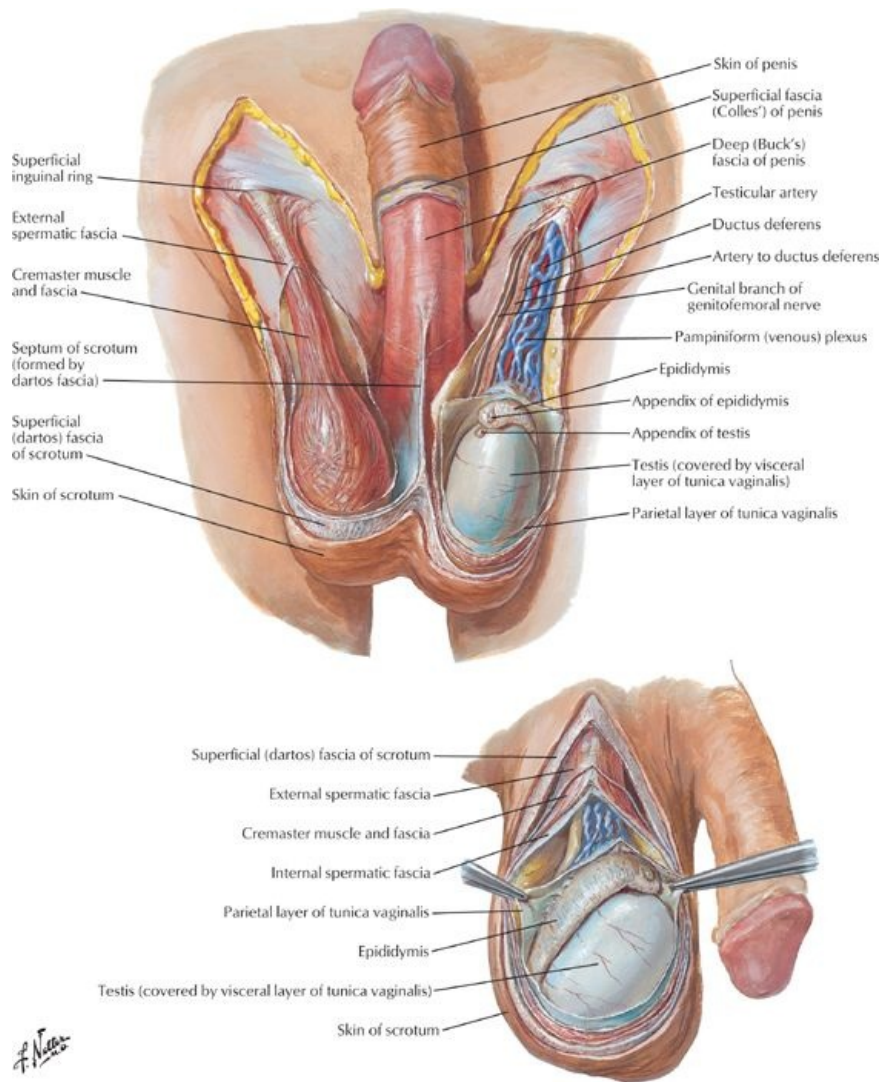
- Thin sheet of deep fascia
- Runs between the two ischiopubic rami
- Spans anterior pelvic outlet
- Pierced by urethra and ducts of bulbourethral glands
- Is attached to perineal body at midpoint of posterior margin
- Thickened anterior margin = transverse perineal ligament
- Superficial transverse perineal muscles
 - Lie superficial to (external to) perineal membrane
 - Extend from ischiopubic ramus on either side along posterior aspect of perineal membrane to attach to the perineal body
- Deep transverse perineal muscles
 - Lie deep to (internal to) perineal membrane
 - Extend from ischiopubic ramus on either side along posterior aspect of perineal membrane to attach to the perineal body
- Sphincter urethrae (external urethral sphincter)
 - Lies deep to (internal or superior to) perineal membrane
 - Circular fibers around membranous part of urethra in males
 - Anterior to deep transverse perineal muscles
- Deep transverse perineal muscles and sphincter urethrae traditionally termed *urogenital diaphragm*

Fascia and spaces of the urogenital triangle

page 191
page 192

- Superficial fascia of the urogenital triangle has two layers, similar to the abdomen
 - Superficial fatty layer
 - Deep membranous layer (Colles' fascia)
 - Superficial layer replaced in penis and scrotum by dartos layer (smooth or dartos muscle)
- Membranous layer of superficial fascia
 - Posteriorly attached to posterior margin of perineal membrane and perineal body
 - Laterally attached to deep fascia (fascia lata) of superior medial thigh
 - Anteriorly is continuous with membranous layer of superficial fascia of abdomen (Scarpa's fascia)
- Deep perineal fascia (Gallaudet's fascia)
 - Invests ischiocavernosus, bulbospongiosus, and superficial transverse perineal muscles
 - Fused to suspensory ligament of penis or clitoris
- Superficial perineal space (pouch)
 - Between membranous layer of superficial fascia and perineal membrane
 - Contains in males:
 - Bulb and crura of penis and associated muscles
 - Proximal spongy urethra
 - Superficial transverse perineal muscles
 - Branches of internal pudendal vessels and pudendal nerves
 - Contains in females:
 - Crura of clitoris and associated muscles
 - Bulbs of vestibule and associated muscles
 - Superficial transverse perineal muscles
 - Branches of internal pudendal vessels and pudendal nerves
 - Greater vestibular glands
- Deep perineal space (pouch)
 - Lies between perineal membrane and pelvic diaphragm
 - Ischioanal fossae extend anteriorly into this space
 - Contains:
 - Membranous urethra
 - External sphincter urethrae
 - Bulbourethral glands: secrete clear mucous during sexual excitation, ducts descend through perineal membrane and terminate in spongy urethra
 - Deep transverse perineal muscles

Male External Genitalia



[Plate 367, Scrotum and Contents]

Scrotum

- Sac derived from skin and superficial fascia of abdominal wall
- Contains testes, epididymis and distal portion spermatic cord
- Skin shows midline scrotal raphe = fusion of bilateral labioscrotal swellings in embryo
- Dartos fascia
 - Continuation of deep membranous layer of superficial fascia of abdomen
 - Contains significant smooth muscle = dartos muscle
 - Extends inward, forming scrotal septum, separating right and left halves
- Deep to dartos, tunics of spermatic cord (external spermatic, cremasteric and internal spermatic fascia form a fused layer around and external to tunica vaginalis)
- Supplied by external pudendal arteries and veins
- Lymphatics drain to superficial inguinal lymph nodes
- Innervated by
 - Anteriorly, ilioinguinal nerve and genital branch of genitofemoral
 - Posteriorly, posterior scrotal nerves (terminal branches of the pudendal) and perineal branches of the posterior femoral cutaneous nerves

Penis

- Male organ of copulation
- Composed of a *body* (shaft), *root* and *glans*
- *Body* is
 - Anchored in superficial perineal space (pouch) and attached to perineal membrane
 - Contains three cylindrical masses of erectile tissue
 - a. paired corpora cavernosa in parallel on dorsal surface

- b. corpus spongiosum in midline of urethral surface (facing scrotum)
 - Each erectile body covered by a fibrous tunic albuginea
- Corpora cavernosa
 - Diverge posteriorly to form the crura of the penis
 - Each crus attaches to the inferior surface of corresponding ischiopubic ramus, anterior to ischial tuberosity
- Glans of the penis is the distal expansion of the corpus spongiosum: proximally it forms bulb
- Membranous urethra pierces the perineal membrane and enters the bulb from above (so now is called spongy urethra) and terminates at external urethral meatus (at apex glans)
- Root of penis is formed by bulb and crura
- Two muscles are associated with erectile bodies
 - Bulbospongiosus muscle
 - Ischiocavernosus muscle
- Body is surrounded by deep fascia (Buck's fascia), external to tunic albuginea
- Skin of penis is connected to deep fascia by loose areolar connective tissue
- At neck of the glans, the skin and connective tissue of the penis extends and a double-layered fold, the prepuce or foreskin
- Vessels and nerves run on dorsum of penis
 - Between skin and deep fascia
 - Between deep fascia and tunica albuginea
- Innervation
 - Dorsal nerve of the penis from the pudendal nerve
 - Passes the length of the penis lateral to the dorsal artery on that side
 - Lies beneath deep fascia
 - Supplies skin and glans
 - Ilioinguinal nerve supplies skin of proximal shaft of penis
 - Erection controlled by parasympathetic nerves (pelvic splanchnic nerves), which relaxes smooth muscle in coiled arteries of penis supplying erectile bodies
- Arterial supply
 - Dorsal arteries of penis from internal pudendal arteries run on either side of deep dorsal vein beneath deep fascia
 - Deep arteries from internal pudendal arteries
 - Run distally within center of corpora cavernosa
 - Highly coiled branches (helicine arteries) supply erectile tissue
 - Artery of bulb of penis from internal pudendal artery supplies posterior corpus spongiosum
 - External pudendal arteries supply skin of penis (branch of femoral artery).
- Venous drainage
 - Deep dorsal vein of penis receives blood from venous plexus
 - Drains to prostatic venous plexus and then to internal iliac/internal pudendal veins.
 - Superficial dorsal vein of penis drains to superficial external pudendal vein
- Lymphatic drainage mainly to superficial inguinal nodes

Muscles of the penis

Muscle	Proximal attachment	Distal attachment	Innervation	Action
Bulbospongiosus	Ventral surface of bulb of penis Perineal body	Corpus spongiosus	Deep branch of perineal nerve from pudendal nerve	Compresses bulb of penis Forces blood into body of penis during erection Compresses outflow veins
Ischiocavernosus	Inferior internal surface of ischiopubic ramus and ischial tuberosity	Crus of penis	Deep branch of perineal nerve from pudendal nerve	Forces blood into body of penis during erection Compresses outflow veins

FACTS & HINTS

High-Yield Facts

Clinical Points

- Urethral rupture may occur spontaneously, or occur as a result of external (fractures of the pelvis, penetrating injury) or internal (following catheterization or instrumentation) trauma.
- Site of urethral rupture determines where urine will extravasate
- The superficial perineal fascia is continuous with the deep membranous layer of the superficial fascia of the anterior abdominal wall. If there is disruption of the spongy urethra, urine may extravasate into the superficial perineal pouch and ascend up the anterior abdominal wall beneath the deep membranous layer. It will not extend into the anal triangle, because the superficial perineal fascia is tacked down to the perineal membrane along its posterior margin. It will not extend into the thigh because the superficial perineal fascia is tacked down to superomedial fascia lata of the thigh.
- Penile trauma is rare. Rupture of the tunica albuginea and bleeding into the deep fascia can result in swelling of the penis.

Mnemonics

Memory Aids

Erectile Dysfunction (ED)	"Very Nervous People Hesitate and Disappoint"
	V ascular
	N eurologic
	P sycho g enic
	H ormonal
	D rugs

39 Testis, Epididymis & Ductus Deferens

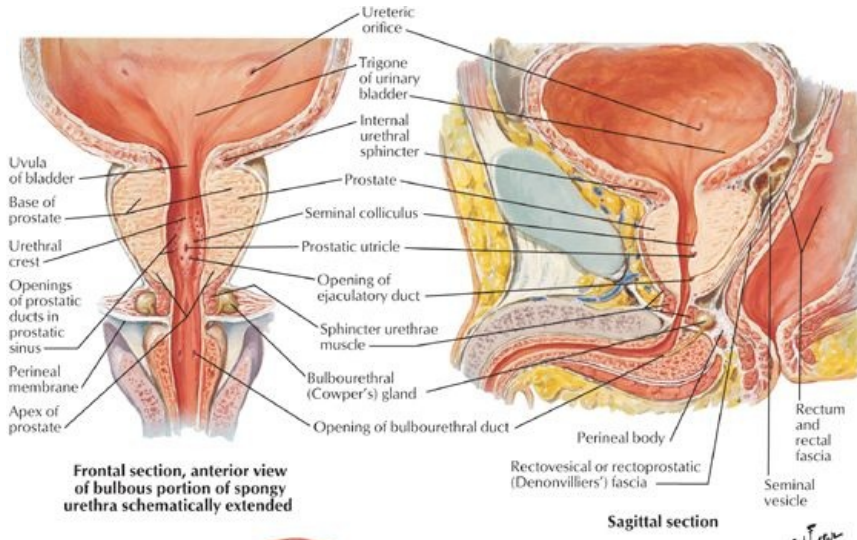
STUDY AIMS

At the end of your study, you should be able to:

- Describe the gross structure of the testes
- Understand the organization of the ducts of the testes: seminiferous tubes, rete testis, efferent ductules
- Describe the basic structure of the epididymis
- Describe the course of the ductus deferens from the testes to the urethra
- Understand the anatomy of the seminal vesicles and their ducts in relation to the formation of the ejaculatory duct
- Know the location of the ejaculatory ducts and where they enter the urethra
- Know the anatomy and organization of the prostate gland
- Outline the contents of semen and the factors that control ejaculation

GUIDE

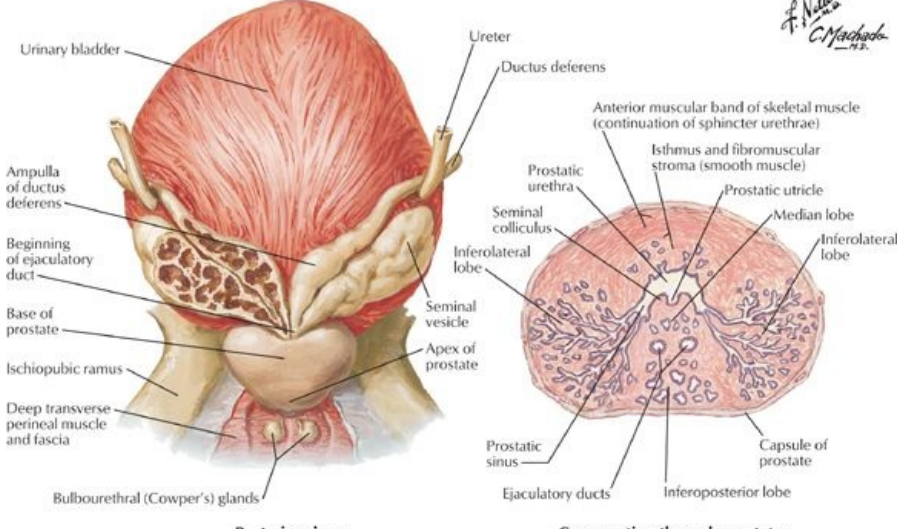
Pelvis and Perineum: Testes, Epididymis, and Ductus Deferens



Frontal section, anterior view of bulbous portion of spongy urethra schematically extended

Sagittal section

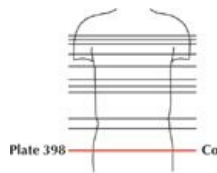
*F. Netter
C. Machado
M.D.*



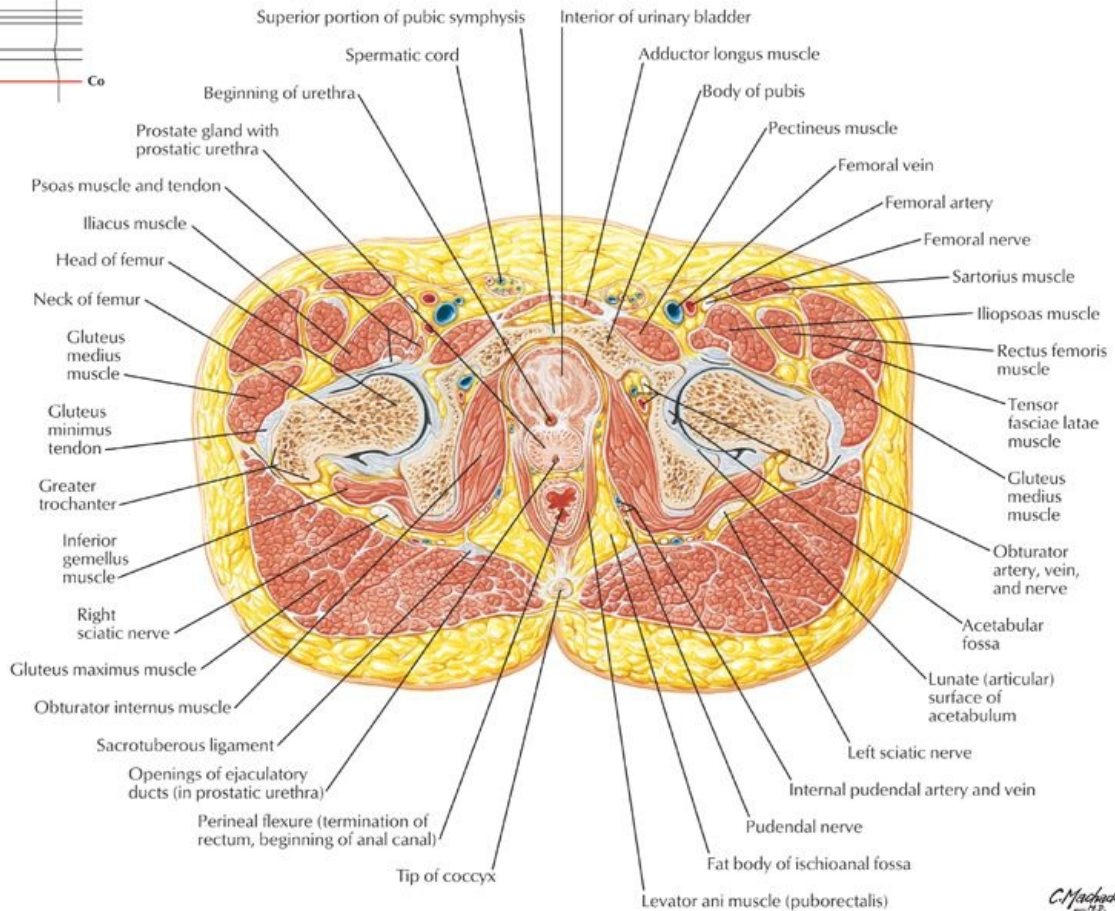
Posterior view

Cross section through prostate

[Plate 364, Prostate and Seminal Vesicles]



Transverse Section: Pubic Crest, Femoral Heads, Coccyx



[Plate 398, Male Pelvis: Bladder-Prostate Junction]

C. Machado

Testes

- Ovoid structure, approximately 5 cm long
- Site of sperm production
- Contains 200 to 300 lobules separated by connective tissue septa
- Two to 3 highly coiled seminiferous tubules in each lobule, 1 meter in length
- Tubules converge toward posterior testis and discharge contents into duct network of rete testis
- Mediastinum testis
 - Posterior region of testis where vessels and nerves enter and leave
 - Not covered by tunica vaginalis
 - Contains rete testis
 - Contains efferent ductules connecting rete testis to head of epididymis
- Suspended by spermatic cord and located in scrotum
- Is covered by three distinguishable layers:
 - Tunica albuginea-tough fibrous layer
 - Visceral layer of tunica vaginalis-serous layer
Applied to testis, epididymis, and distal spermatic cord
 - Parietal tunica vaginalis
Parietal and visceral tunica vaginalis derived from peritoneal outpocketing in embryonic life
Separated by small amount of serous fluid that allows testis to move in scrotal sac
Deficient posteriorly to transmit epididymis and blood vessels
- Blood supply: Testicular artery
- Venous drainage: Pampiniform plexus

Epididymis

- Formed from convolutions of narrow duct of the epididymis
- Located on posterior aspect testes within scrotum
- Consists of a head, a body, and a tail
- Head formed from ends of approximately 12 efferent ductules from the testis
- Tail is continuous with ductus deferens
- Where sperm are stored, mature, and become motile
- Blood supply: Testicular artery
- Venous drainage: Pampiniform plexus

page 195
page 196

Ductus deferens (Vas deferens)

- Twenty-five cm long
- Connects tail of epididymis to ejaculatory duct
- Course:
 - Commences at tail of epididymis
 - Travels in spermatic cord (where it can be palpated) through superficial inguinal ring and through inguinal canal
 - Emerges at deep inguinal ring and crosses over external iliac vessels to run along the lateral pelvic wall
 - Crosses above and medial to the ureter where it becomes dilated and forms the ampulla
 - Ampullae converge with each other on the posterior aspect of the bladder and narrow before uniting with duct of the seminal vesicle to form ejaculatory duct
 - Ejaculatory duct opens into the prostatic urethra
- Blood supply: Branch of inferior vesical artery = deferential artery
- Venous drainage: Deferential vein(s) to prostatic venous plexus to internal iliac veins.

Seminal vesicles

- Elongated, coiled structures between fundus of bladder and rectum
- Separated from rectum by rectovesical pouch
- Do not store sperm
- Secrete alkaline fluid that mixes with sperms in ejaculatory ducts and urethra
- Duct of each seminal vesicle joins ductus deferens to form ejaculatory duct
- Supplied by branches and tributaries of inferior and middle rectal vessels

Ejaculatory ducts

- Formed from union of ductus deferens with duct of seminal vesicle
- Short, approximately 2.5 cm
- Converge and open on seminal colliculus of prostatic urethra as two slits
- Supplied by deferential arteries
- Drained by prostatic and vesical plexuses

Prostate

page 196
page 197

- Encapsulated gland surrounding urethra between neck of bladder and pelvic floor
- Directly behind inferior edge of pubic symphysis
- Composed of
 - Two lateral lobes
 - Anterior lobe or isthmus connecting lateral lobes anteriorly
 - Posterior lobe below ejaculatory ducts and posterior to urethra
 - Middle lobe between urethra and ejaculatory ducts
- Contains glands that produce 20% of volume of semen
- Ducts of glands combine to form prostatic ducts opening into prostatic sinuses on either side of seminal colliculus in prostatic urethra
- Dense fascia sheath outside capsule contains prostatic venous plexus that drains to internal iliac veins
- Supplied by prostatic arteries from several sources including internal iliac or inferior vesical arteries

FACTS & HINTS

High-Yield Facts

Anatomic Points

Semen contains:

- Sperm from the testes: 40 to 600 million per ejaculate but only 10% of total ejaculate
- Seminal vesicle secretions: alkaline fluid rich in fructose, 70% of total ejaculate
- Prostatic secretions: lipids, acid phosphatase, proteolytic enzymes, citric acid
- Other contents: potassium, zinc, citric acid, phosphorylcholine, spermine, free amino acids, and prostaglandins

Mechanism of Ejaculation

- Controlled by sympathetic nervous system
- Contraction of smooth muscle of ductus deferens, seminal vesicles, and prostate propels secretions into prostatic urethra
- Simultaneous contraction of smooth muscle in bladder neck prevents retrograde ejaculation (reflux of semen into the bladder)
- Semen is expelled from the urethra by contraction of the bulbospongiosus muscles

Clinical Points

Hydrocele

- An accumulation of serous fluid in space between parietal and visceral layers of tunica vaginalis
- Presents as a fluctuant swelling in the testes
- Detection requires transillumination-bright light applied to the swelling presents as a red glow in a darkened room
- May be congenital, precipitated by trauma or inflammation of the epididymis

Clinical Points

Vasectomy

- A method of birth control because it produces sterility
- Failure rate less than 95%
- Performed under local anesthetic
- Vas deferens is isolated via a small scrotal incision in suprapubic scrotal wall
- A segment of duct is clamped or ligatured at each end, the segment is sectioned and the ends are cauterised

page 197
page 198

Clinical Points

Testicular Cancer

- Ninety-five percent are germ cell tumors
- Nearly all are malignant
- Peak incidence 15 to 34 years
- Presents as firm, painless lump in testes or a reactionary varicocele
- Potentially curable with surgical resection (orchidectomy) if detected early
- Metastasizes to lumbar lymph nodes

Mnemonics

Memory Aids

Table I03-1. Innervation of the Penis

"Point and Shoot"	Erection ("Point") is controlled by the Parasympathetic nervous system and ejaculation ("Shoot") by the Sympathetic nervous system.
"S2, 3, 4 keep the penis off the floor"	Innervation of the penis by branches of the pudendal nerve, derived from spinal cord levels S2-S4

40 Rectum

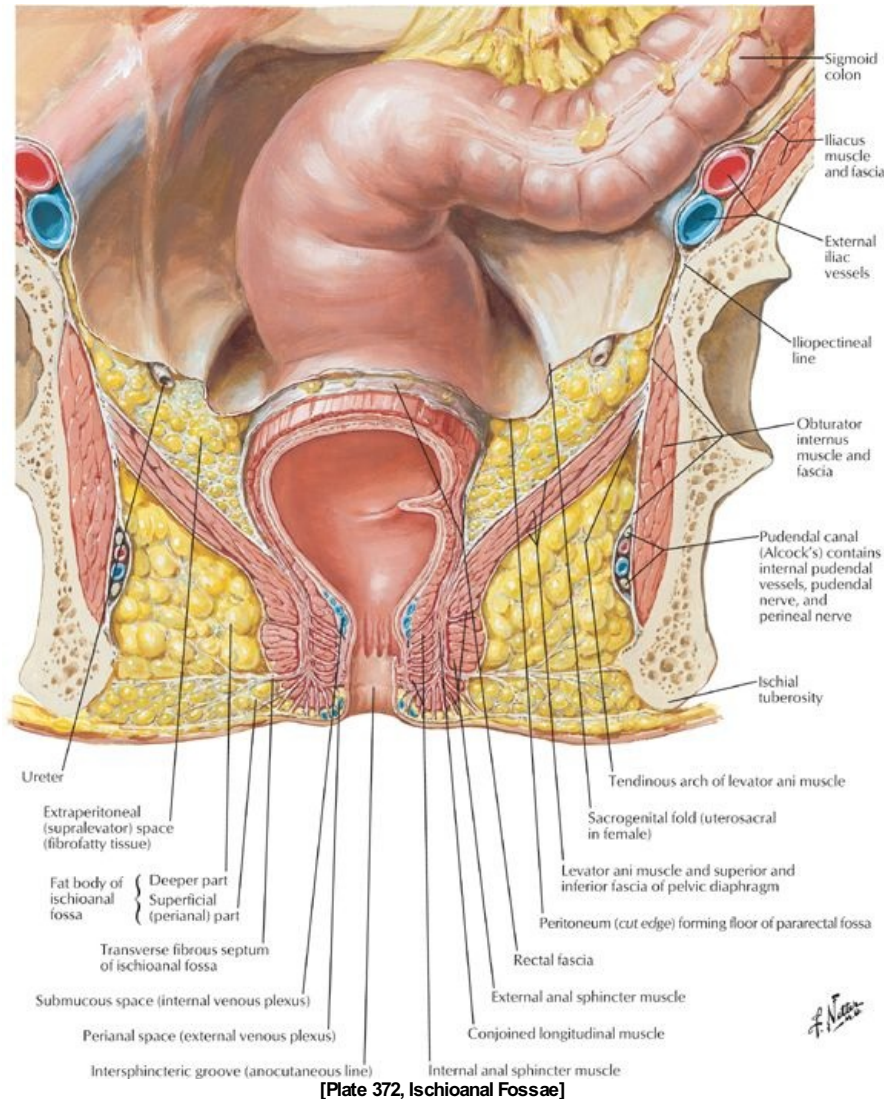
STUDY AIMS

At the end of your study, you should be able to:

- Describe the gross structure of the rectum, including its musculature
- List the relations of the rectum
- Outline the blood and vascular supply of the rectum
- Describe structures that may be palpated on digital rectal examination
- Describe the anatomy of the anus
- Describe the blood and vasculature supply to the different regions of the anus

GUIDE

Pelvis and Perineum: Rectum and Anal Canal



Rectum

Gross structure

- Approximately 12 cm in length
- Is a part of the large bowel
- Commences at level S3 vertebral body and follows the curve of the sacrum and coccyx
- Is a continuation of the sigmoid colon at rectosigmoid junction
- Extends from rectosigmoid junction to anal canal (anorectal junction)
- Anorectal junction
 - Lies at level of pelvic floor
 - Puborectalis muscle forms a U-shaped sling at this point
 - Perineal flexure annulates anorectal junction
 - Is palpated as anorectal ring on digital rectal examination
- Three lateral curves/flexures in the rectum (upper and lower curves deviate to the right; the middle to the left)
- Rectal ampulla
 - In region of middle and lower curves
 - Somewhat dilated
 - Very distensible
- Internal structure
 - Smooth mucosa, changes from rugose mucosa of sigmoid colon
 - Transverse rectal folds
 - Three infoldings of mucosa and submucosa project into lumen
 - Superior, middle, and inferior
 - Called rectal valves of Houston
 - Result from three lateral flexures

- Peritoneum
 - Upper third of rectum covered by peritoneum on anterior aspect and sides
 - Middle third of rectum covered by peritoneum on anterior surface only
 - Lower third of rectum below peritoneal reflection
- Pararectal fossae on lateral sides of rectum in peritoneal cavity
- Rectovesical septum of pelvic fascia separates rectum from prostate
- Rectovaginal septum of pelvic fascia separates rectum from vagina
- Lateral ligaments of rectum-condensations of pelvic fascia around middle rectal vessels

Relations of Rectum

	Relations
Posterior	Sacrum Coccyx Piriformis muscle Superior rectal vessels Hypogastric plexus (ANS) Sympathetic trunk nerves Sacral plexus
Inferior	Levator ani muscles
Lateral	Pelvic plexus nerves (ANS) Ureters
Anterior	Sigmoid colon Ileum
Anterior structures palpable on rectal examination	Prostate (males) Base bladder Seminal vesicles (males) Ampullae of ductus deferens (males) Cervix (females)

Blood supply

- **Arterial**
 - Mainly by superior rectal artery (continuation of inferior mesenteric artery)
 - Also supplied by the middle rectal arteries (from internal iliac arteries) to the middle and inferior parts
 - Inferior rectal arteries supply the anorectal junctions and anal canal
 - Superior, middle, and inferior rectal arteries anastomose with each other
- **Venous**
 - Chief drainage via a rectal venous plexus to the superior rectal vein
 - Middle and inferior rectal veins also drain the rectum
 - Superior rectal vein drains to the portal system
 - Middle and inferior rectal veins drain to the inferior vena cava via the internal iliac vein
 - Anastomoses between these veins link the portal and system systems
- **Lymphatic drainage**
 - Lymphatic vessels from superior half of rectum drain to pararectal nodes and from there to inferior mesenteric and lumbar nodes
 - Lymphatic vessels from the inferior half of the rectum travel with the middle rectal vessels to the internal iliac nodes and anastomose with the lymphatics of the anal canal
- **Nerve supply**
 - Sympathetic innervation
From lumbar sympathetic fibers via the inferior mesenteric arteries and the superior rectal arteries to the superior rectal plexus to blood vessels of rectum
 - Parasympathetic innervation
Are the main motor fibers to muscles of the rectal wall
From the pelvic splanchnic nerves (S2-S4) via the inferior hypogastric (pelvic) plexus to middle rectal plexus
 - Visceral afferent (sensory) fibers travel via the inferior hypogastric (pelvic) plexus and pelvic splanchnics back to spinal cord

Anal Canal

Gross structure

- Terminal part of gastrointestinal tract
- Is approximately 3 cm long
- Commences at anorectal junction and ends at anus
- Encircled by internal and external sphincter muscles
- Descends between perineal body and anococcygeal ligament
- Mucosal lining of superior has longitudinal ridges-anal columns
 - Inferior ends of columns joined by anal valves
 - Behind valves are small sinuses: anal sinuses
 - Anal glands (mucus) empty into anal sinuses
- Inferior end of anal valves forms an irregular line: pectinate (or dentate) line
- Pectinate line divides the superior portion of the anal canal, derived from embryonic endoderm (hindgut), from the inferior portion derived

from ectoderm (proctodeum)

- Inferior half lined by nonkeratinized squamous epithelium (skin)
- Vascular, nerve and lymphatic supply of these two regions different as a result of different embryologic origin

Vascular, Lymphatic, and Nerve Supply to the Anal Canal

Supply	Above Pectinate Line	Below Pectinate Line
Arterial	Superior rectal artery	Inferior rectal arteries
Venous	Internal plexus drains to superior rectal vein and portal system	Internal venous plexus drains to inferior rectal veins and caval system
Lymphatic	To internal iliac and common iliac and lumbar nodes	To superficial inguinal nodes
Nerve	From inferior hypogastric (pelvic) plexus (both sympathetic and parasympathetic; sensitive to stretching only)	From inferior rectal nerves, branches of the pudendal nerves (sensitive to pain, temperature and touch)

- Has two sphincters: external (voluntary) and internal (involuntary)
 - External sphincter
 - Described as having superficial, subcutaneous, and deep parts
 - Parts are not readily distinguishable
 - Fibers attach to the central perineal tendon (body) anteriorly and anococcygeal ligament posteriorly
 - Internal sphincter: internal circular muscular layer continuous from rectum around upper two thirds of anal canal

Anorectal Musculature

Ischioanal (Ischioanal) fossae

page 201
page 202

- Fat filled, wedge-shaped recesses either side of anal canal
- Communicate with each other posteriorly over the anococcygeal ligament
- Bounded by
 - Laterally: ischium and obturator internus muscle and fascia
 - Medially: anal canal surrounded by external anal sphincter
 - Anteriorly by external sphincter urethrae and deep transverse perineal muscles
 - Superiorly by pelvic diaphragm
 - Inferiorly by superficial perineal fascia and skin
- Filled with fat spanned by fibrous bands to support anal canal but compressible during defecation
- On lateral walls are found internal pudendal vessels and pudendal nerve within pudendal (Alcock's) canal in the fascia of the internal surfaces of obturator muscles
- Extends anteriorly superior to perineal membrane as anterior recesses of ischioanal (ischioanal) fossae
- Important site abscess formation

FACTS & HINTS

High-Yield Facts

Anatomic Points

Mechanism of Defecation (Emptying of Bowel)

- Occurs as the result of action of the pelvic splanchnic nerves-increase peristaltic action of rectum
- Feces move through anal canal
- Pressure in rectum causes reflex contraction of external anal sphincter
- Contraction of external anal sphincter causes relaxation of peristaltic contraction
- External anal sphincter relaxes and defecation occurs

Clinical Points

page 202
page 203

Anal Hemorrhoids (Varicosities)

- Can be internal or external
- Internal
 - Are prolapses of mucosal lining containing internal venous plexus
 - Can prolapse through anal canal, become strangulated by sphincters, and ulcerate
 - Are painless
- External
 - Are blood clots in external venous plexus
 - Are painful
- Are caused by
 - Anything that increases intra-abdominal pressure, such as chronic constipation (straining) or pregnancy
 - Portal hypertension (cirrhosis of the liver)
- Varicosities of the venous plexuses are normal
- Internal hemorrhages can occur without portal hypertension

Ischioanal and Perianal Abscesses

- A number of potential tissue spaces surround the anal canal and rectum and may become infected because of
 - Inflammation of anal sinuses
 - Extension of an infection from the pelvis
 - Tear in the mucous membrane of the anal canal
- Abscesses are classified according to the space occupied:
 - submucosal
 - peri-anal
 - intersphincteric
 - ischioanal
 - perirectal
- Perianal and ischioanal account for approximately 80% of all abscesses

Rectal prolapse

- Eversion of the lower part of the rectum and anal canal
- Occurs as a result of weakness of pelvic floor muscles and breakdown of pelvic fascia
- Common in elderly (older than 80 years)
- More common in women, since perineum is weakened by childbirth

Digital Rectal Examination

- Performed with patient in left lateral position
- Perianal region is initially inspected for fistulae, fissures, skin tags, and prolapsed hemorrhoids
- Ninety percent of rectal cancers palpable
- Surfaces of sacrum and coccyx and ischial spines and tuberosities can be palpated
- Enlarged internal iliac lymph nodes and ischioanal (ischioanal abscesses) can also be palpated
- In men: prostate and seminal vesicles can be palpated anteriorly
- In women: cervix can be palpated anteriorly

41 Vasculature

STUDY AIMS

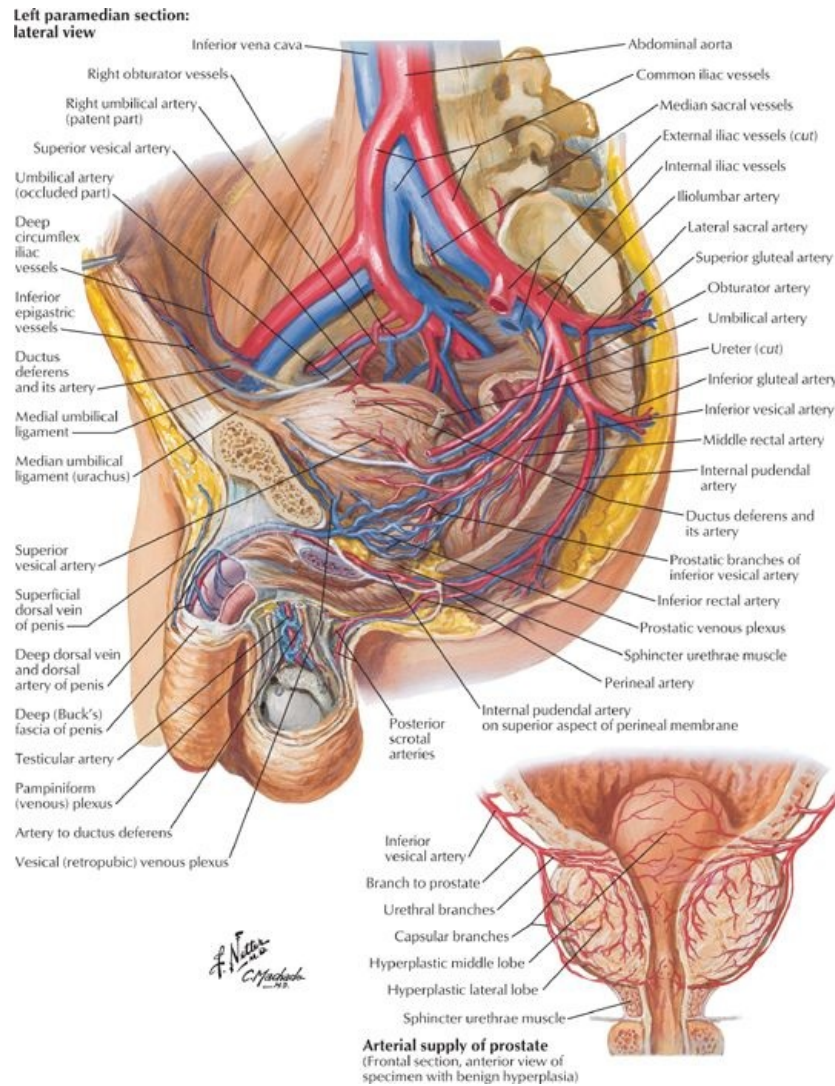
At the end of your study, you should be able to:

- Describe the arterial blood supply of the pelvis and perineum
- Name the visceral and parietal branches of the internal iliac artery
- Outline the venous drainage of the pelvis and perineum
- Outline the lymphatic drainage of the pelvis and perineum

GUIDE

Pelvis and Perineum: Vasculature

Pelvic Vasculature



[Plate 383, Arteries and Veins of Pelvis: Male]

Arterial supply to the pelvis

- Four arteries supply the true or lesser pelvis and its contents
 - Paired internal iliac arteries
 - Paired ovarian arteries
 - Medial sacral artery
 - Superior rectal artery
- Main arterial supply is from branches internal iliac artery
- Medial sacral artery from abdominal aorta supplies lower lumbar vertebrae, sacrum, and coccyx
- Superior rectal artery (branch inferior mesenteric artery) supplies upper region of rectum
- Ovarian arteries (from abdominal aorta) supply the ovaries, descending in the suspensory ligament of the ovary
- Internal iliac artery
 - One of two terminal branch common iliac arteries (other is external iliac)
 - Common iliac bifurcates anterior to sacroiliac joint
 - Internal iliac artery is crossed by ureter at its origin
 - Passes posteromedially into the true pelvis beneath the peritoneum, giving off branches to the buttocks, thigh, perineum, and pelvic viscera. Usually ends at the level of the superior edge of the greater sciatic foramen by dividing into anterior and posterior divisions

Branches of Internal Iliac Artery and Structures Supplied

Visceral Vessels	Structures Supplied	Comment
Umbilical artery	Superior urinary bladder via superior vesical Artery to ductus deferens in males	From anterior division of internal iliac Obliterates and becomes median umbilical ligament
Superior vesical artery	Superior urinary bladder Ureter in pelvis	From proximal part of umbilical Branch given to ductus deferens

Inferior vesical artery	Inferior urinary bladder Prostate Seminal vesicles Ductus deferens	From anterior division of internal iliac Only exists in males
Uterine artery	Vagina Uterus Uterine tubes	From anterior division of internal iliac Terminates by anastomosing with ovarian artery
Middle rectal artery	Inferior rectum Seminal vesicles +/- prostate	From anterior division of internal iliac
Vaginal artery	Vagina Cervix Inferior urinary bladder	From uterine
Parietal Branches	Structures Supplied	Comment
Obturator artery	Pelvic muscles Head of femur Muscles of medial compartment thigh	From anterior division of internal iliac Runs through obturator canal with obturator vein and artery Occasionally can take origin from inferior epigastric artery
Superior gluteal artery	Piriformis muscle All three gluteal muscles Tensor fascia lata	From posterior division of internal iliac Exits via greater sciatic foramen above piriformis muscle
Inferior gluteal artery	Pelvic diaphragm Piriformis Quadratus femoris Gluteus maximus Hamstring muscles	From anterior division of internal iliac Exits via greater sciatic foramen below piriformis muscle
Internal Pudendal Artery	Muscles and skin of anal and urogenital triangles Erectile bodies	From anterior division of internal iliac Passes through greater sciatic foramen below piriformis and enters perineum via lesser sciatic foramen
Iliolumbar artery	Psoas major Iliacus Quadratus lumborum	From posterior division of internal iliac Ascends deep to common iliac and anastomoses with lower lumbar arteries
Lateral sacral artery	Piriformis Contents of sacral canal Erector spinae	From posterior division of internal iliac Runs on piriformis Sends branches into pelvic sacral foramina

Venous drainage of the pelvis

- Veins accompany main branches of internal iliac artery
- Around pelvic organs they anastomose to form venous plexuses: rectal, vesical, prostatic, uterine and vaginal
- Extensive prostatic venous plexus and anastomoses occur around the pelvic viscera in a male
- Extensive anastomoses and venous plexus surrounding the uterus and vagina in female
- Venous plexuses communicate with each other
- Veins and plexuses eventually drain into internal iliac vein
- Some venous blood from the pelvis drains to the internal vertebral venous plexus
- Internal iliac veins are found deep to the arteries
- Become confluent with external iliac veins to form common iliac veins
- Aortocaval anastomosis occurs between the superior rectal vein and inferior rectal veins

page 205
page 206

Vasculature Supply of the Pelvic Organs

Organ	Blood Supply	Venous Drainage
Pelvic organs common to male and female		
Ureter	Renal, gonadal, common iliac, uterine/inferior vesical, and middle rectal arteries	Parallel to the arteries
Urinary bladder	Superior and inferior vesical arteries of anterior division of internal iliac artery	Internal iliac vein via vesical and prostatic venous plexuses
Male pelvic structures		
Seminal glands	Branches of inferior vesical and middle rectal arteries	Drain to internal iliac veins
Ductus deferens	Inferior epigastric artery, inferior vesical, and middle rectal arteries	Drain to internal iliac veins
Prostate gland	Inferior vesical and middle rectal arteries	Prostatic venous plexus receives the deep dorsal vein of penis and vesical veins. It drains into the internal iliac veins
Female pelvic structures		
Ovary	Ovarian artery from abdominal aorta, which anastomoses with the uterine artery (a branch of the	Ovarian vein drains to inferior vena cava on the right and left renal vein on the left

	internal iliac artery)	
Uterine tube	Ovarian artery from abdominal aorta, which anastomoses with the uterine artery (a branch of the internal iliac artery)	Ovarian vein drains to inferior vena cava on the right and left renal vein on the left
Uterus	Branches of ovarian artery (from the aorta), uterine and vaginal arteries (from the internal iliac artery)	Ovarian vein (see ovary), uterine and vaginal veins (drain to the internal iliac veins)

Lymphatic drainage of the pelvis

- Lymphatic vessels accompany arteries
- Most lymph drains to internal iliac nodes and then to common iliac nodes
- The ovaries, testes, and rectum drain to aortic nodes
- Some vessels from body of the uterus drain to superficial inguinal nodes, following the round ligament of the uterus

Perineal Vasculature

Arterial supply of the perineum

page 206
page 207

- Mainly from internal pudendal artery (branch internal iliac artery)
- Supplies muscles and skin of anal and urogenital triangles, erectile bodies of perineum
- Internal pudendal artery
 - Passes through greater sciatic foramen inferior to the piriformis muscle
 - Loops around the sacrospinous ligament
 - Enter the lesser sciatic foramen to reach the ischioanal (ischioanal) fossa and perineum
 - Traverses the fossa in the pudendal (Alcock's) canal
 - Gives off branches before entering the canal and in pudendal canal
 - Medial to ischial tuberosity, terminates as deep and dorsal arteries of penis (or clitoris)

Branches of Internal Pudendal Artery Supplying Perineum

Branch	Structure Supplied	Comment
Inferior rectal artery	Anal canal	
Posterior scrotal (labial) artery	Scrotum (labia in females)	
Branch to bulb of penis	Bulb of penis (vestibule in females)	
Branch to crus of penis	Crus of penis (clitoris in females)	
Dorsal artery of penis (clitoris)	Erectile tissue corpus cavernosum	Smaller artery in females
Deep artery of the penis (clitoris)	Erectile tissue corpus cavernosum	Smaller artery in females

Venous drainage of the perineum

- Branches of internal pudendal artery accompanied by venae comitantes
- Drain into internal iliac vein

Lymphatic drainage of the perineum

- Penis and vulva drain to the superficial inguinal nodes

FACTS & HINTS

High-Yield Facts

Clinical Points

Varicocele

- Abnormal dilatation of pampiniform venous plexus
- Almost always left-sided because left testicular vein drains into left renal vein not inferior vena cava as on the right
- Seen when patient stands, disappears on lying down
- Caused by defective valves in testicular artery or problem with left renal vein

42 Innervation

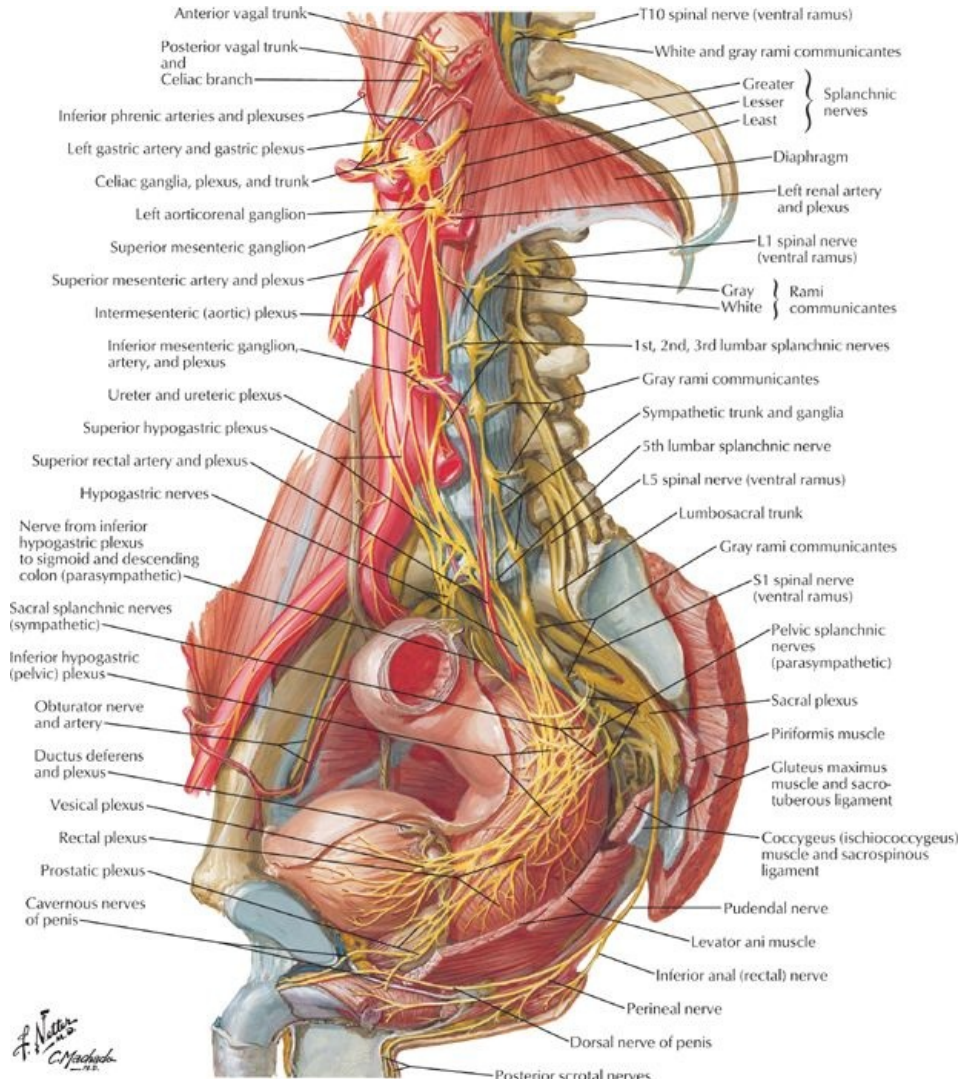
STUDY AIMS

At the end of your study, you should be able to:

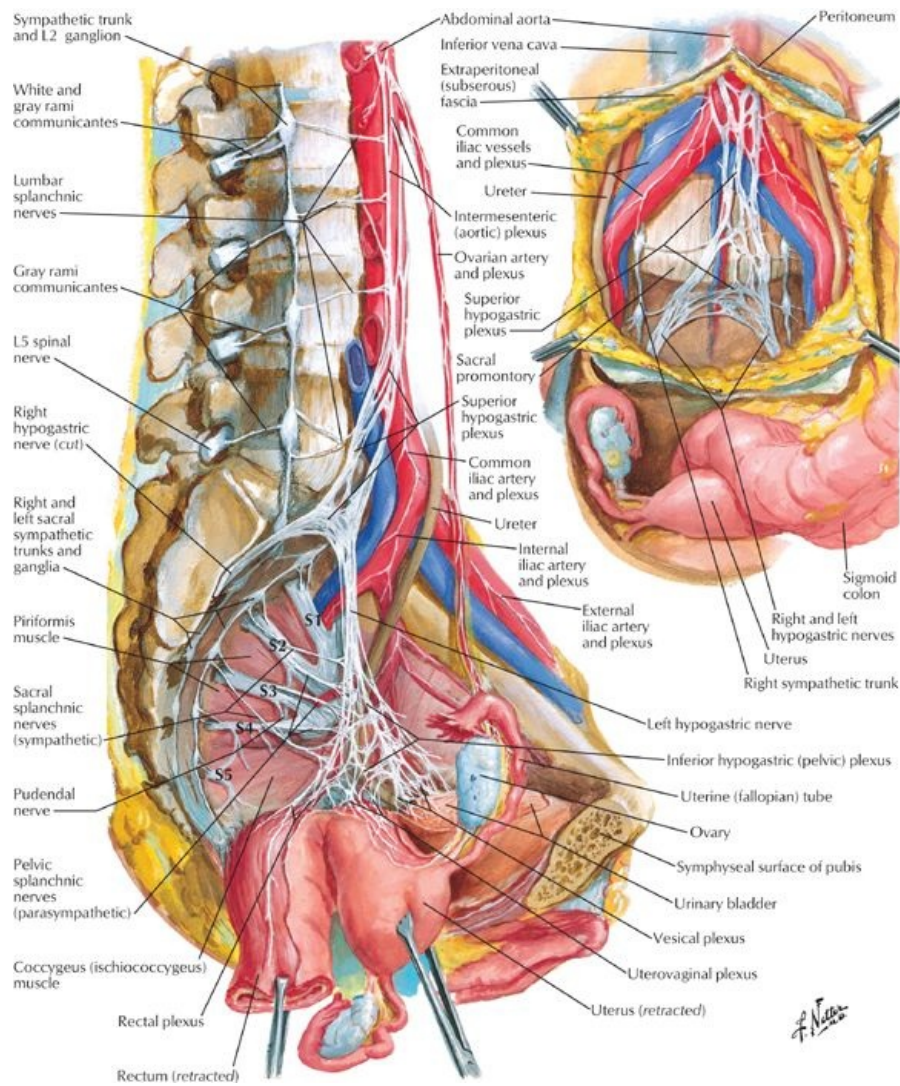
- Describe the formation of the sacral plexus
- Know the main branches of this plexus and what they supply
- Describe the parasympathetic innervation of the pelvis
- Describe the sympathetic innervation of the pelvis
- Describe the innervation of the perineum

GUIDE

Pelvis and Perineum: Innervation



[Plate 390, Nerves of Pelvic Viscera: Male]



[Plate 392, Nerves of Pelvic Viscera: Female]

Innervation of the Pelvis

- Pelvic innervation is both somatic and autonomic
- Many nerves pass through the pelvis without innervating any structures

Sacral plexus (somatic contribution)

- Located on posterior wall of true pelvis on anterior surface of piriformis muscle
- Formed by ventral rami of S1-S4 spinal nerves and the lumbosacral trunk, formed from fibers from the ventral rami of L4-L5 spinal nerves
- Branches supply: lower limb; pelvic floor and wall and perineum; most branches leave the pelvis through greater sciatic foramina
- Two major branches are the sciatic nerve and pudendal nerve

Branches of the Sacral Plexus

Nerve	Structures Supplied	Spinal nerve origin
Major branches		
Sciatic	Hip joint Flexor muscles of knee Muscles of leg and foot	L4-L5, S1-S3
Pudendal	Sensory and motor to all structures in the perineum	S2-S4
Superior gluteal	Gluteus medius and minimus muscles	L4-L5, S1
Inferior gluteal	Gluteus maximus muscle	L5, S1-S2
Posterior femoral cutaneous	Sensory to buttock, superior medial, and posterior thigh	S2-S3
Minor branches		
Nerve to piriformis	Piriformis muscle	S1-S1
Nerve to obturator internus and superior gemellus mm	Obturator internus and superior gemellus muscles	L5, S1-S2
Nerve to quadratus femoris and inferior gemellus mm	Quadratus femoris and inferior gemellus muscles	L4-L5, S1
Nerve to levator ani and coccygeus	Pelvic diaphragm	S3-S4

Autonomic nerves

- Sympathetic innervation
 - Sympathetic trunks
 - Contain fibers from lower thoracic and upper lumbar spinal segments
 - Descend on posterior abdominal wall on either side of the vertebral bodies
 - Descend behind common iliac artery, in front of sacrum and piriformis muscle
 - Fuse on anterior surface of coccyx as ganglion impar
 - Are source of sacral splanchnic nerves that join inferior hypogastric (pelvic) plexus in pelvis
 - Contain either postsynaptic fibers from synapses in ganglia superiorly or pre-synaptic fibers that will synapse in one of four sympathetic ganglia in pelvis
 - Primary function is to send postsynaptic fibers to sacral spinal nerves via grey rami communicantes
 - No white rami communicantes associated with sacral sympathetic trunks because sympathetic outflow is thoracolumbar
 - Lumbar splanchnics join superior hypogastric plexus
 - Superior hypogastric plexus
 - Is located just below the bifurcation of the aorta
 - Is a continuation of the intermesenteric/aortic plexus
 - Contains no parasympathetic fibers
 - Contains visceral afferents ascending from the pelvis
 - Continues into the pelvis as loose collections of fibers in either side of the anterior sacrum = right and left hypogastric nerves
 - Spreads out in pelvis as inferior hypogastric (pelvic) plexus
 - Functions
 - Vasomotor, pilomotor, secretory to sweat glands to skin of perineum and lower limb
 - Controls ejaculation (in males)
 - Innervates smooth muscle of blood vessels in pelvis and smooth muscle of some organs
- Parasympathetic innervation
 - From pelvic splanchnic nerves
 - Outflow from 2nd to 4th sacral spinal cord segment
 - Contain visceral afferents
 - Controls micturition, erection, and defecation
 - Innervates descending and sigmoid colon via fibers ascending in the sigmoid mesentery and the parietal peritoneum of the left side of the posterior abdominal wall

Inferior Hypogastric (Pelvic) Plexus

General structure

- Formed from fibers of hypogastric nerves, sacral splanchnic nerves, and pelvic splanchnic nerves
- Lies on posterolateral pelvic wall internal to internal iliac arteries and their branches
- Gives off
 - Middle rectal plexus
 - Uterovaginal plexus (females)
 - Vesical plexus
 - Deferential plexus
 - Prostatic plexus (males)
 - Cavemous nerves (nervi erigentes) to erectile tissue of penis and clitoris
- Except for cavemous nerves, nerves in the various plexuses reach the viscera in company with relevant branches of the internal iliac artery
- Branches transmit efferents from both sympathetic and parasympathetic nervous systems and visceral afferents

Contents

- Pre- and postsynaptic sympathetic fibers from superior hypogastric plexus via hypogastric nerves
- Postsynaptic sympathetic fibers from sacral splanchnic nerves
- Sympathetic ganglia
- Visceral afferent fibers that either ascend along the hypogastric nerves or return to the CNS via the pelvic splanchnic nerves, depending on the information carried.
- Presynaptic parasympathetic fibers from the pelvic splanchnic nerves
- Enteric parasympathetic ganglia where the plexus lies on or near a pelvic viscus
- Postsynaptic parasympathetic fibers from the enteric ganglia to the viscus innervated

FACTS & HINTS

High-Yield Facts

Clinical Points

- The obturator nerve and vessels cross the floor of the ovarian fossa; therefore, ovarian disease such as malignancy can present with referred pain to the medial aspect of the thigh.
- After a radical prostatectomy (removal of the prostate gland, seminal vesicles, and periprostatic tissue) for localized prostate cancer, erectile dysfunction can occur, because of inadvertent damage of the cavernous nerves (nervi erigentes), the parasympathetic fibers from the pelvic plexus that govern erection.

Clinical Points

Pudendal Nerve Block

- Performed to relieve perineal pain during childbirth
- Anesthetic agent is injected into tissues around pudendal nerve
- Injection is normally done transvaginally
- Physician palpates the ischial spine and uses his or her fingers to direct the needle so that the anesthetic is injected in the region of the ischial spine, where the pudendal nerve wraps around it to enter the lesser sciatic foramen
- Pudendal blocks do not relieve the pain of contractions

Mnemonics

Memory Aids

S 2, 3, 4 keeps the poo off the floor	Defecation is controlled by parasympathetic fibers to the rectum and anal canal from the pelvic splanchnic nerves via the pelvic plexus. These nerves arise from S2, S3, and S4 spinal cord levels.
--	---

43 Topographic Anatomy

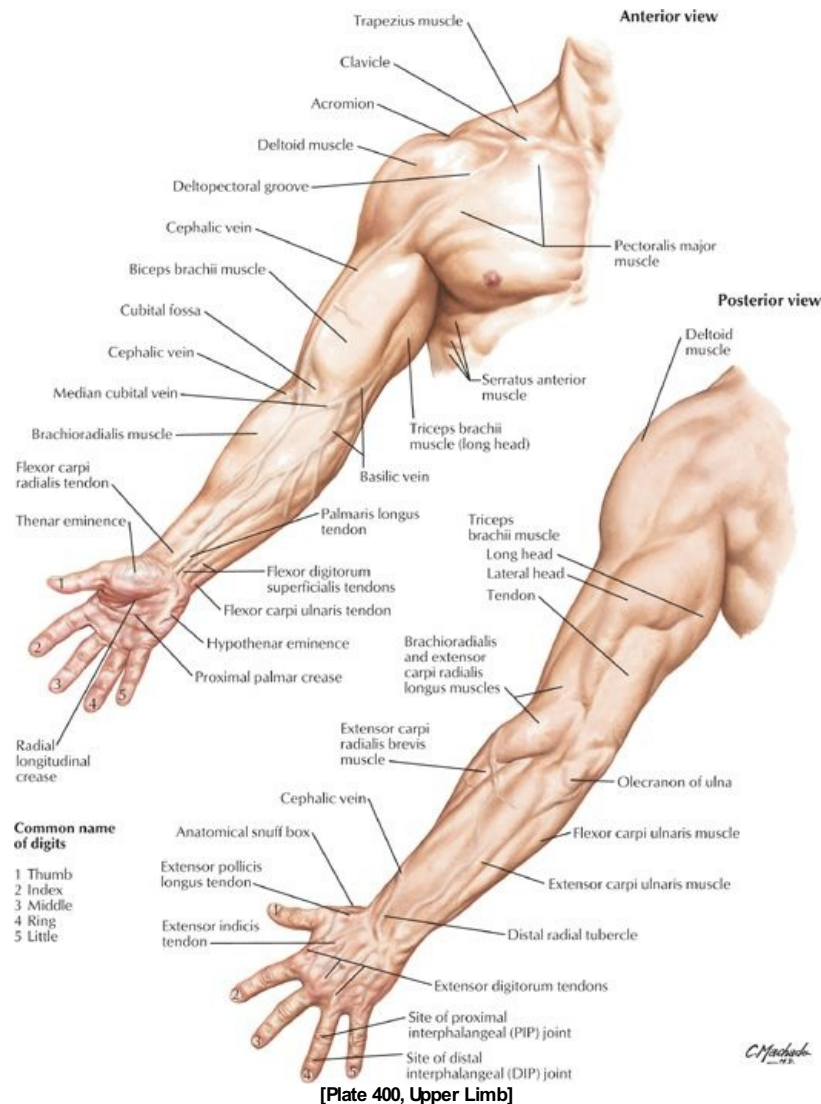
STUDY AIMS

At the end of your study, you should be able to:

- Identify the bony landmarks: acromion, coracoid process of scapula, olecranon and head of ulna, medial, and lateral epicondyles, radial styloid process
- Identify the muscle masses of the deltoid, biceps, triceps, brachioradialis, and thenar and hypothenar eminences
- Identify the deltopectoral triangle and cubital fossa
- Identify the course of the cephalic, basilic, and median cubital veins

GUIDE

Upper Limb: Topographic Anatomy



Bones

- Clavicle: Subcutaneous; palpable throughout its length
- Acromion: Easily palpable, traced medially to acromioclavicular joint (see Section 6-2: Upper Limb: Shoulder and Axilla)
- Coracoid process of scapula: Palpable deep and lateral to the deltopectoral triangle
- Head of humerus: Palpable deep to deltoid inferior to lateral edge of acromion when arm is rotated
- Elbow: Palpable medial and lateral epicondyles of humerus and visible olecranon process of ulna (see Section 6-4: Upper Limb: Elbow and Forearm)
- Head of radius: Palpable as it rotates during pronation and supination on posterolateral aspect of extended elbow, just distal to lateral epicondyle
- Ulnar head: Visible on the medial side of the dorsal aspect of the wrist (see Section 6-5: Upper Limb: Wrist and Hand)
- Radial styloid: Palpable in the anatomical snuff box on the lateral side of the wrist
- Ulnar styloid: just distal to ulnar head with hand supinated
- Pisiform: hard, round structure on anteromedial aspect of wrist
- Tubercles of scaphoid and trapezium: Palpable at proximal end of thenar eminence

Muscles and Tendons

- Deltoid muscle: Overlies the shoulder giving it a rounded appearance
- Biceps: Bulge on anterior aspect of arm
- Biceps brachii tendon: Palpable in cubital fossa, lateral to midline with arm flexed
- Flexor tendons: Wrist and finger flexors visible distally on ventral aspect of forearm
- Extensor tendons: Wrist and finger flexors visible on the dorsum of the hand
- Thenar eminence: Muscles at the base of the thumb (see Section 6-5: Upper Limb: Wrist and Hand)
- Hypothenar eminence: Muscles at the base of the little finger (see Section 6-5: Upper Limb: Wrist and Hand)

- Brachial artery
 - Pulsations can be palpated deep to medial border of biceps muscle
 - Used to determine heart rate in children
- Radial artery: Pulse can be felt by compressing artery against distal end of radius
- Median cubital vein (see Section 6-4: Upper Limb: Elbow and Forearm)
 - Traverses the cubital fossa connecting cephalic to basilic veins
 - Often used for venipuncture
- Cephalic vein ascends along lateral forearm and arm (see Section 6-6: Upper Limb: Neurovasculature)
- Basilic vein ascends along medial forearm and distal arm (see Section 6-6: Upper Limb: Neurovasculature)
- Dorsal venous network seen on the dorsum of the hand

Nerves

- Ulnar nerve can be felt under the medial epicondyle

FACTS & HINTS

HIGH-YIELD FACTS

Anatomic Points

Functional Overview

The upper limb is highly mobile and characterized by its ability to perform a wide range of controlled movements to manipulate the surrounding environment. It is suspended from the trunk at the shoulder, and its stability has been sacrificed to gain mobility. Clinically the limb is divided into four regions: pectoral girdle, arm, forearm and hand.

Upper Limb Development

The upper limb buds from the embryonic trunk and rotates 90 degrees laterally, such that in the anatomic position, the ventral structures face anteriorly and the dorsal structures posteriorly. This contrasts with the medial rotation of the lower limb. Thus, the upper and lower limbs are 180 degrees out of phase. Flexors of all joints in the upper limb are anterior, and extensors are posterior.

Clinical Points

Winged Scapula

- Normally the scapula is held closely against the posterior thoracic wall. Damage to the long thoracic nerve to serratus anterior (which courses superficially over the muscle) causes "winging" of the scapula as its medial border lifts away from the thorax when the arm is raised. This is accentuated when the individual leans on the hand or pushes the upper limb against a wall. Most importantly, the arm cannot be abducted above the horizontal plane because glenoid cavity cannot be rotated upward without the action of the serratus anterior.

44 Shoulder and Axilla

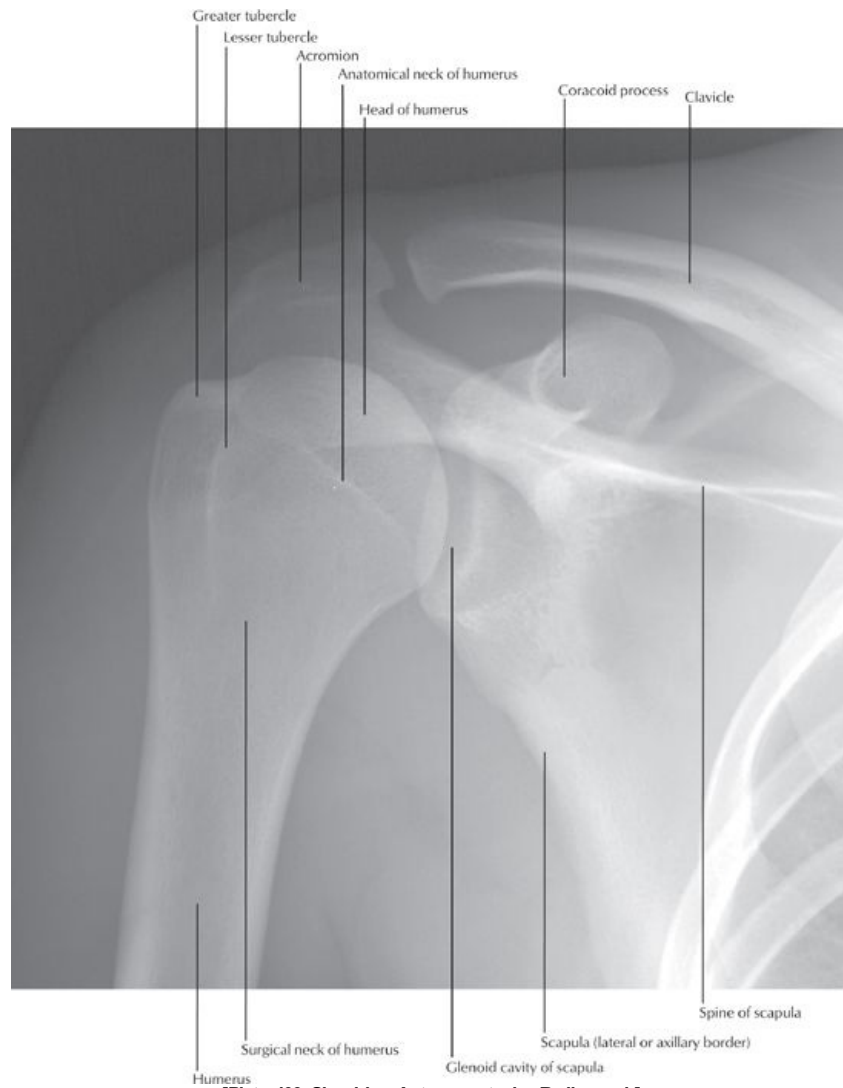STUDY AIMS

At the end of your study, you should be able to:

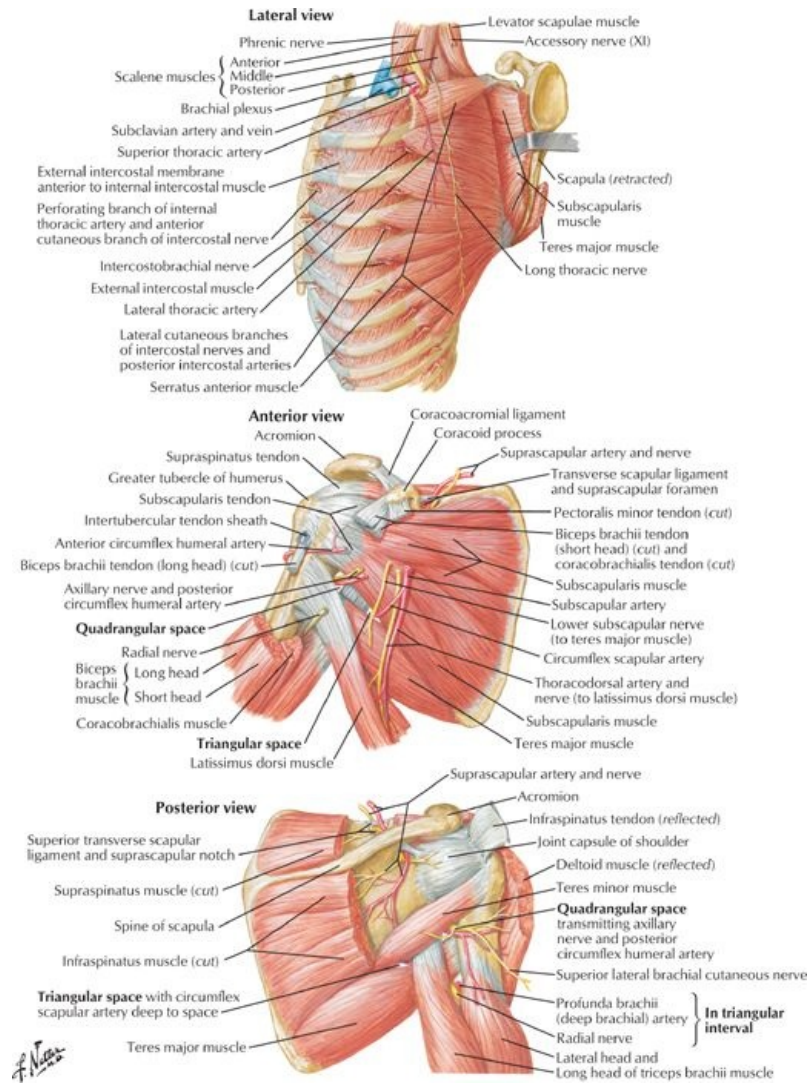
- Identify the different parts and surface markings of the clavicle and scapula
- Describe the sternoclavicular, acromioclavicular, and glenohumeral joints, their movements, and supporting ligaments
- Understand the organization of the scapular muscles
- Know the origins, insertions, and actions of the intrinsic scapular muscles
- Identify the boundaries of the axilla and describe its contents
- Describe the organization of the deep fascia

GUIDE

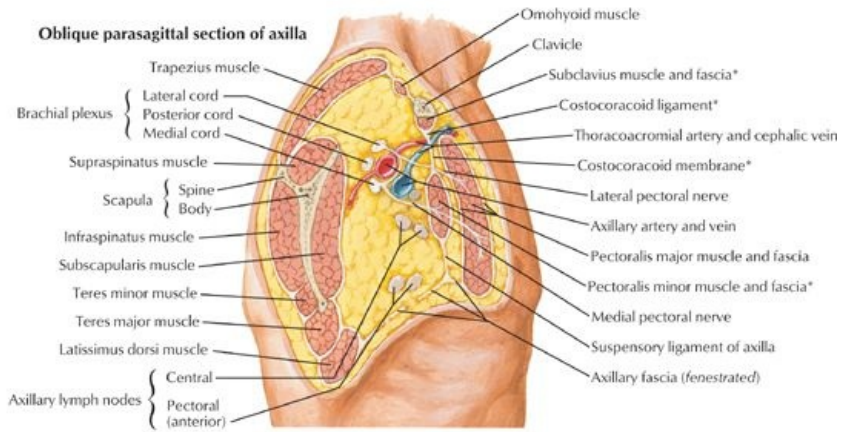
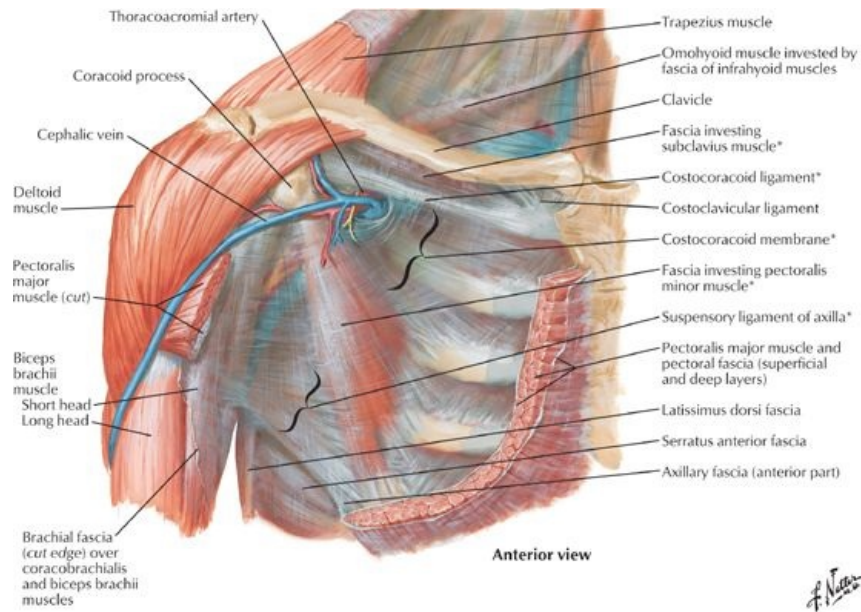
Upper Limb: Shoulder and Axilla



[Plate 409, Shoulder: Anteroposterior Radiograph]

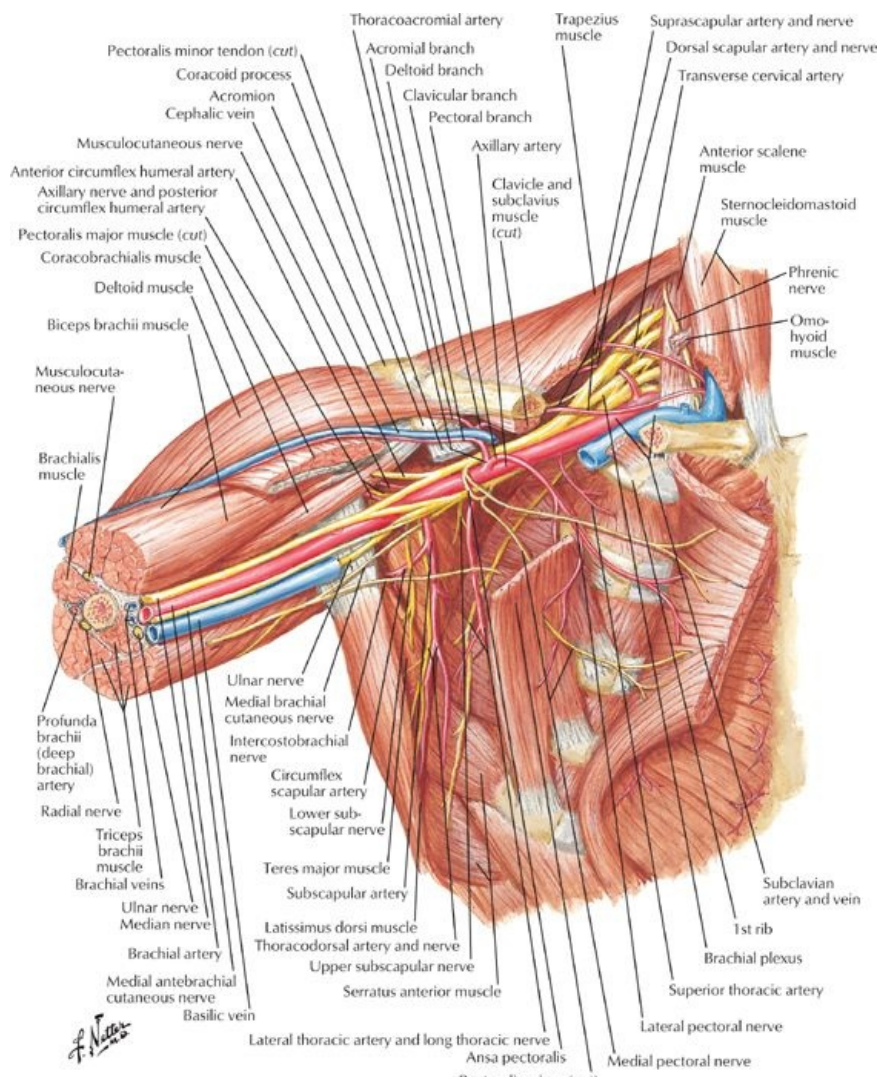


[Plate 414, Scapulothoracic and Scapulohumeral Dissection]



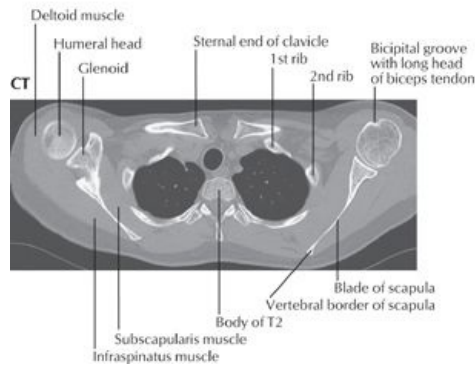
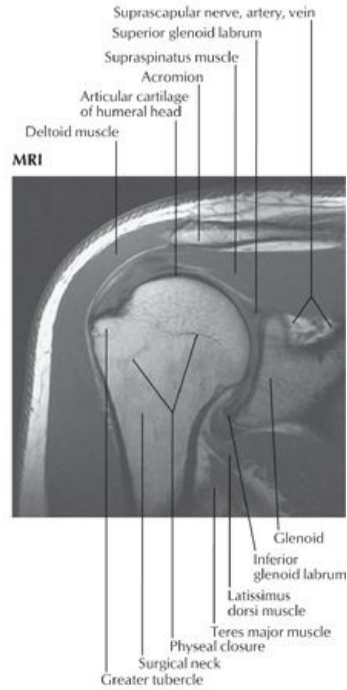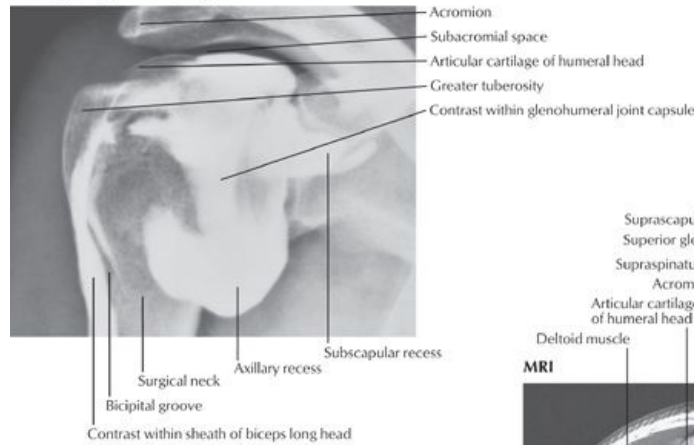
*Components of clavipectoral fascia

[Plate 416, Pectoral, Clavipectoral, and Axillary Fasciae]



[Plate 417, Axilla (Dissection): Anterior View]

Arthrogram: glenohumeral joint

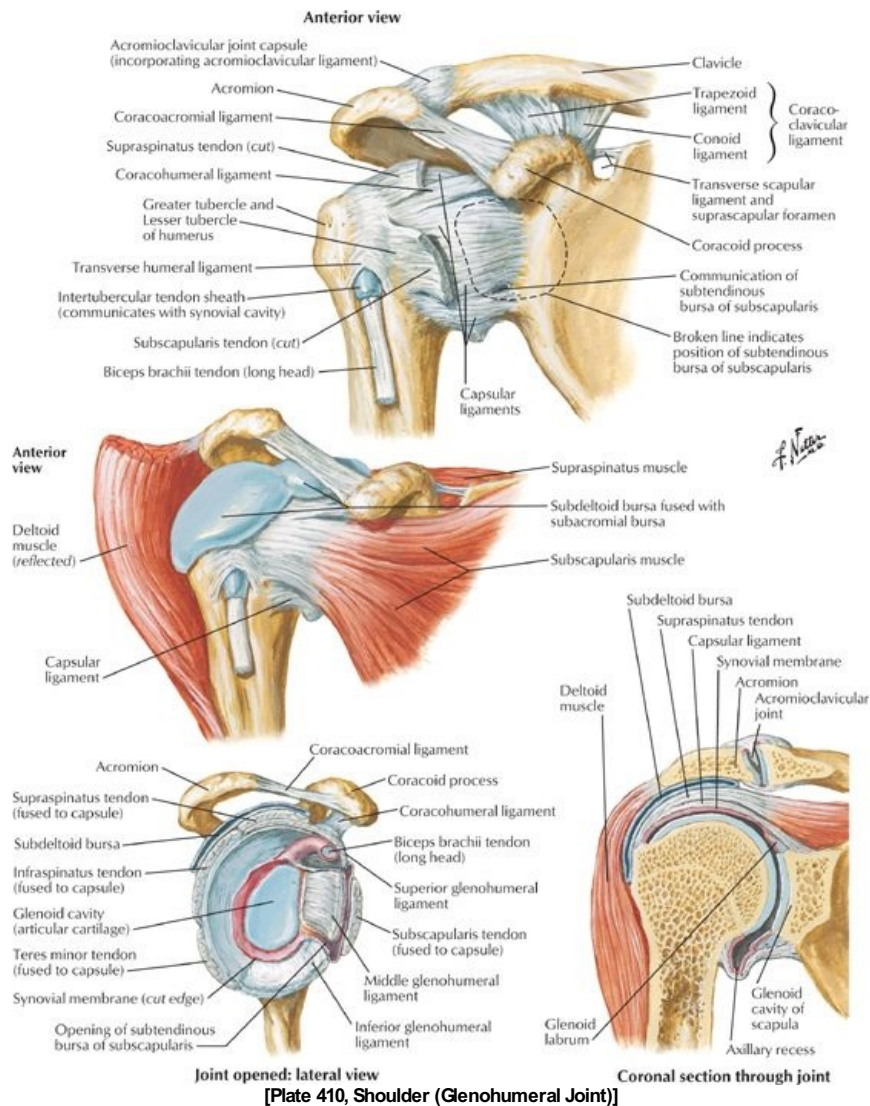


[Plate 468, Shoulder Arthrogram, MRI, and CT]

Bones

- Clavicle: with sternal and acromial ends
 - Double-curved long bone
 - Sternal end articulates with manubrium of sternum
 - Acromial end articulates with acromion
 - Osteological features
 - Deltoid tubercle for attachment of the deltoid muscle
 - Conoid tubercle for attachment of conoid ligament
 - Subclavian groove for attachment of subclavius muscle
 - Trapezoid line where trapezoid ligament attaches
 - Serves as a strut suspending the scapula and limb with maximum freedom
- Scapula: lying against posterolateral thorax
 - Triangular flat bone
 - Lies posterolateral on second through seventh ribs
 - Osteological features
 - Concave costal surface = subscapular fossa
 - Posterior surface divided by spine = transverse ridge of bone
 - Supraspinous fossa
 - Infraspinous fossa
 - Acromion = flattened lateral end of spine
 - Coracoid process = anterior projection above glenoid cavity
 - Glenoid cavity = socket for head of humerus
 - Suprascapular notch (scapular notch) = notch found on superior border, two thirds of the way along laterally
 - Capable of considerable movement over thoracic wall

Joints



[Plate 410, Shoulder (Glenohumeral Joint)]

- **Sternoclavicular Joint**
 - Saddle-type, synovial joint
 - Divided into two compartments by an articular disc
 - Movements
 - Elevation with posterior rotation
 - Protraction
 - Depression
 - Articulation between concave facet of manubrium and concave facet of clavicle
 - Strengthened by anterior and posterior sternoclavicular, costoclavicular, and interclavicular ligaments
 - Blood supply: Branches of suprascapular and internal thoracic arteries
 - Nerve supply: Branches of the supraclavicular nerve, and nerve to subclavius
- **Acromioclavicular Joint**
 - Plane-type, synovial joint
 - No demonstrable movement; muscles moving the scapula cause the acromion to move on the clavicle
 - Articulation between concave facet of acromion and convex facet of clavicle
 - Strengthened by acromioclavicular and coracoclavicular (conoid and trapezoid) ligaments
 - Coracoclavicular
 - Unites coracoid process and clavicle
 - Has two component ligaments
 - Conoid: vertical, in shape of inverted pyramid
 - Trapezoid: horizontal, extends laterally to inferior surface of clavicle
 - Blood supply: Branches of suprascapular and thoracoacromial arteries
 - Nerve supply: Branches of the supraclavicular, lateral pectoral and axillary nerves
- **Shoulder (Glenohumeral) Joint**
 - Multiaxial, synovial ball-and-socket joint
 - Movements
 - Flexion/extension
 - Abduction/adduction
 - Internal/external (medial/lateral) rotation
 - Circumduction
 - Articulation of head of humerus with the shallow glenoid cavity of the scapula
 - Joint socket deepened by glenoid labrum (fibrocartilaginous ring) and supported by the rotator cuff muscles (see below)

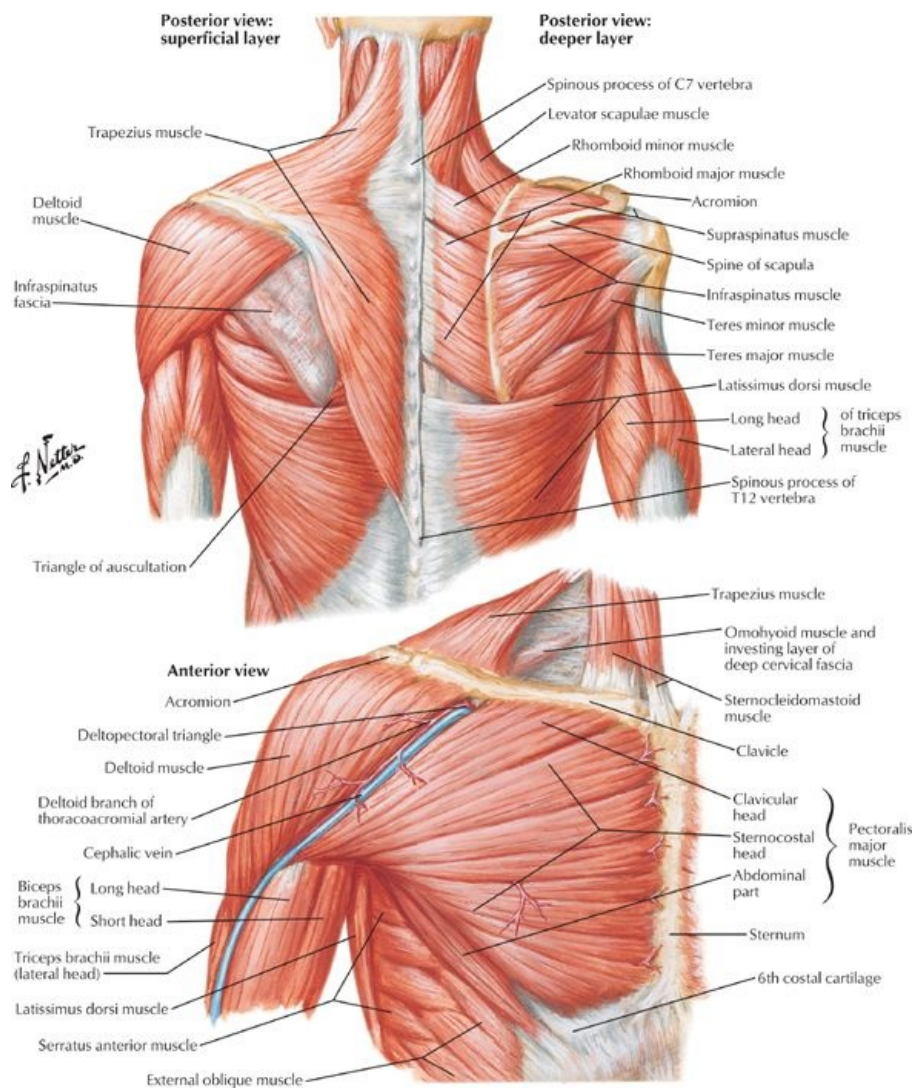
- Loose fibrous capsule encloses and contains two apertures
 - Between the tubercles of the humerus for passage of long head of biceps brachii, which attaches to supraglenoid tubercle within the joint
 - Anterior opening, inferior to coracoid process, for communication between subscapular bursa and synovial cavity of joint
- Blood supply: Branches of anterior and posterior circumflex humeral arteries from the axillary and suprascapular artery from the subclavian
- Nerve supply: Branches of suprascapular, axillary, and lateral pectoral nerves
- Ligaments of glenohumeral joint
 - Glenohumeral ligaments-strengthen capsule anteriorly
 - Coracohumeral ligament-strengthens joint superiorly
 - Transverse humeral ligament-bridges gap between greater and lesser tubercle and holds tendon of biceps brachii in place
 - Coracoacromial ligament-from acromion to coracoid process, prevents displacement of humeral head superiorly

LIGAMENT	ATTACHMENTS	COMMENT
Joint capsule	Margin of glenoid cavity → anatomical neck of humerus	Loose fibrous capsule Weakest inferiorly
Glenohumeral	Supraglenoid tubercle → blend with fibrous capsule (superior, middle and inferior bands)	Reinforce anterior capsule
Coracohumeral	Coracoid process → greater tubercle of humerus	Strong
Transverse humeral	Bridges intertubercular groove between greater and lesser tubercles	Holds tendon of biceps brachii in intertubercular groove
Coracoacromial	Coracoid process → acromion	Completes coracoacromial arch protecting humeral head

Bursae (Important ones)

- Contain thin layer of synovial fluid
- Located where tendons rub against bone, ligaments, or tendons and when skin moves over bone directly beneath
- Subscapular bursa
 - Between tendon of subscapularis muscle and neck of scapula
 - Communicates with cavity of the shoulder joint
- Subacromial (subdeltoid) bursa
 - Between deltoid, supraspinatus tendon and glenohumeral capsule
 - Does not communicate with cavity of shoulder
 - Facilitates movement of deltoid over joint capsule and supraspinatus tendon under coracoacromial arch

Muscles of the Scapula



[Plate 411, Muscles of Shoulder]

Muscle	Origin	Insertion	Innervation	Blood Supply	Action
Trapezius	Medial third of superior nuchal line, external occipital protuberance, ligamentum nuchae, spinous processes of C7-T12	Lateral third of posterior clavicle, medial acromion, superior edge of spine of scapula	Spinal root of accessory nerve (CN XI) and C3 and C4	Transverse cervical artery, dorsal scapular artery	Elevates scapula (descending part), retracts scapula (transverse part), depresses scapula (ascending part); rotates scapula (descending and ascending parts acting together)
Latissimus dorsi	Spinous processes of T7-T12, thoracolumbar fascia, iliac crest, lower three to four ribs	Floor of intertubercular sulcus of humerus	Thoracodorsal nerve (C6-C7)	Thoracodorsal artery	Extends, adducts and medially rotates arm, draws shoulder downwards and backward

page 215
page 216

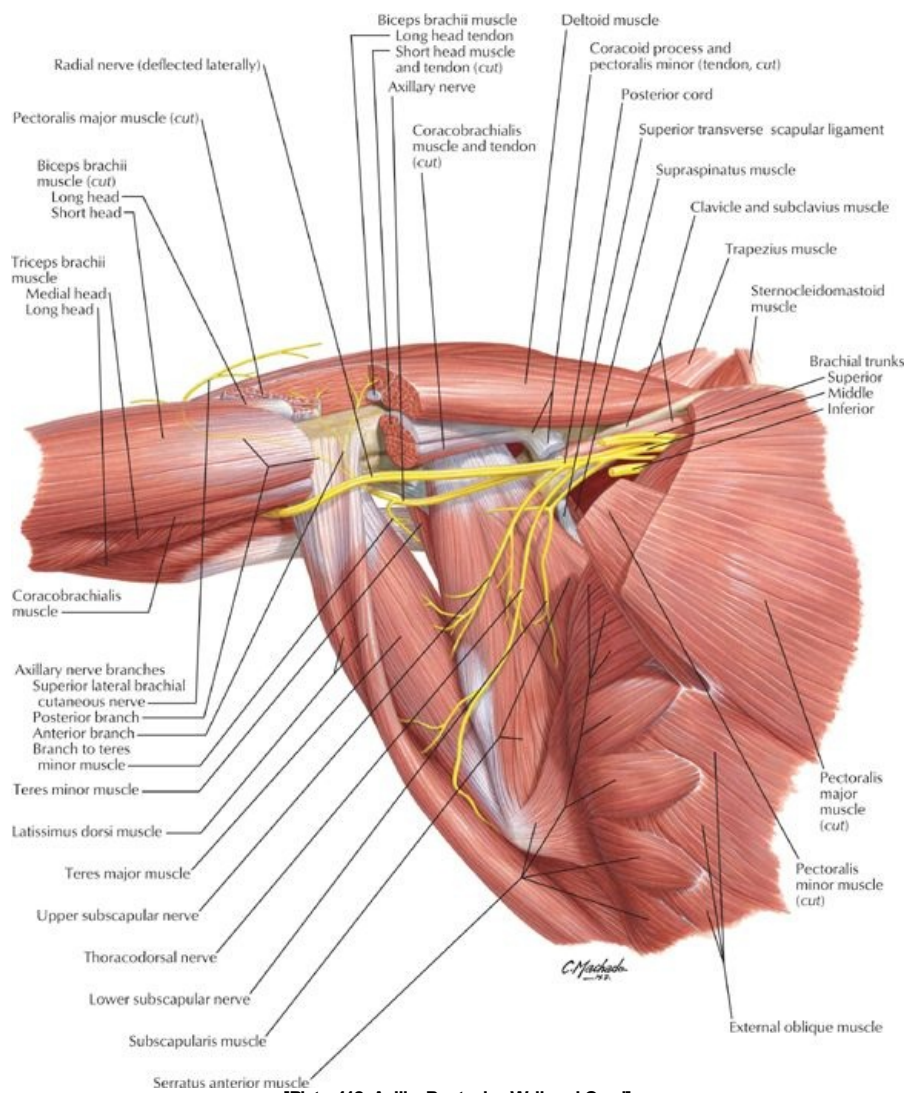
Muscle	Origin	Insertion	Innervation	Blood Supply	Action
Levator scapulae	Posterior tubercles of transverse processes C1-C4	Medial border of scapula above base of spine of scapula	Dorsal scapular and cervical (C3-C4) nerves	Dorsal scapular artery, transverse cervical artery	Elevates scapula medially, inferiorly rotates glenoid cavity
Rhomboid minor	Ligamentum nuchae, spinous processes of C7 and T1	Medial border of scapula above base of spine of scapula	Dorsal scapular nerve (C4-C5)	Dorsal scapular artery	Retracts and stabilizes the scapula
Rhomboid major	Spinous processes of T2-T5	Medial border of scapula below base of spine of scapula	Dorsal scapular nerve (C4-C5)	Dorsal scapular artery	Retracts and rotates scapula to depress the glenoid cavity

Muscle	Origin	Insertion	Innervation	Blood Supply	Action
Deltoid	Lateral third of anterior clavicle, lateral acromion, inferior edge of spine of scapula	Deltoid tuberosity of humerus	Anterior and posterior branches of axillary nerve (C5,C6)	Posterior circumflex humeral artery, deltoid branch of thoracoacromial artery	Clavicular part-flexes and medially rotates arm; acromial part-abducts arm; spinal part-extends and laterally rotates arm
Supraspinatus	Supraspinous fossa of scapula	Superior facet of greater	Suprascapular nerve (C5,C6)	Suprascapular artery	Initiates arm abduction, acts with rotator cuff muscles

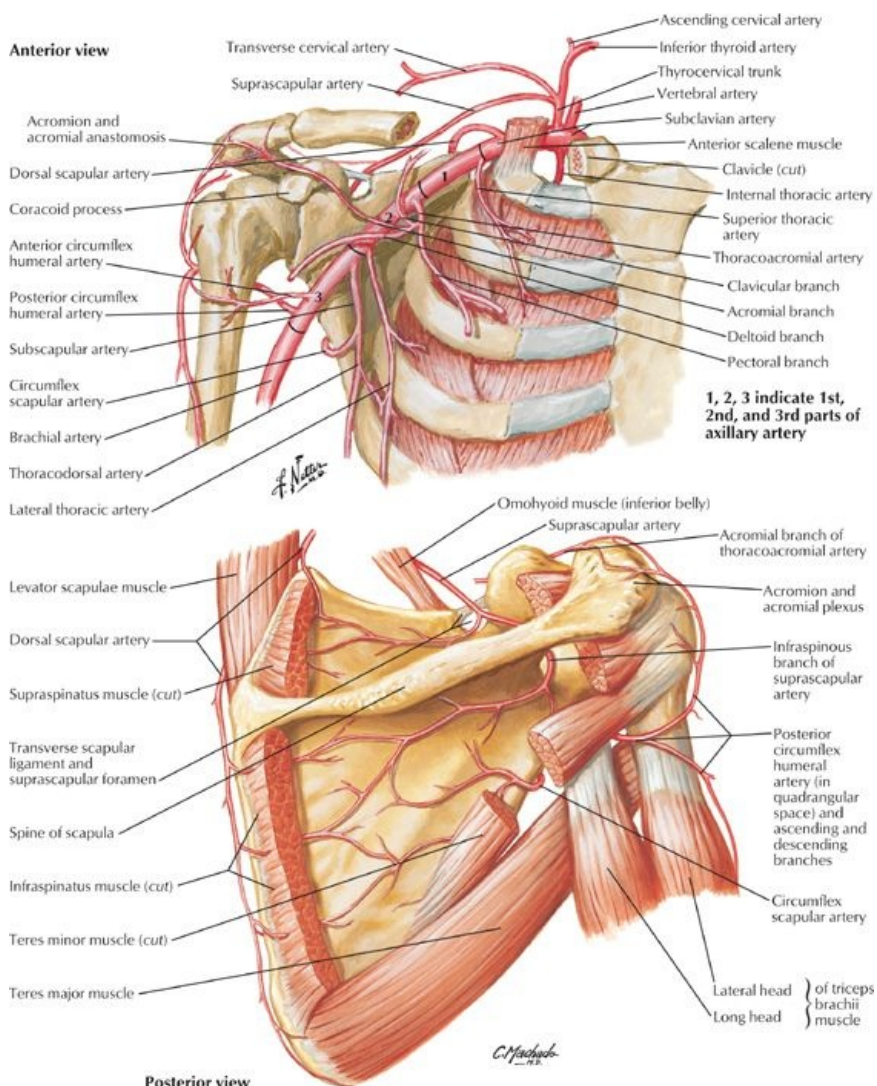
		tubercle of humerus			
Infraspinatus	Infraspinous fossa of scapula	Middle facet of greater tubercle of humerus	Suprascapular nerve (C5,C6)	Suprascapular artery	Lateral rotation of arm (with teres minor)
Teres minor	Upper two thirds of posterior surface of lateral border of scapula	Inferior facet of greater tubercle of humerus	Posterior branch of axillary nerve (C5,C6)	Circumflex scapular artery	Lateral rotation of arm, adduction
Teres major	Posterior surface of inferior angle of scapula	Medial lip of intertubercular sulcus	Inferior subscapular nerve (C5,C6)	Circumflex scapular artery	Adducts and medially rotates arm
Subscapularis	Subscapular fossa	Lesser tubercle of humerus	Superior and inferior subscapular nerves (C5-C6)	Subscapular artery, lateral thoracic artery	Medially rotates arm and adducts it; helps hold humeral head in glenoid cavity

- Superficial extrinsic (Join axial skeleton to the appendicular skeleton)
 - Trapezius
 - Latissimus dorsi
- Deep extrinsic
 - Levator scapulae
 - Rhomboid major and minor
- Intrinsic
 - Deltoid: Gives shoulder its rounded appearance, abducts arm past 15 degrees
 - Teres major: Adducts and medially rotates arm
 - Teres minor: Hidden by deltoid, assists lateral rotation of arm and adduction
 - Supraspinatus: Initiates arm abduction
 - Infraspinatus: Laterally rotates arm
 - Subscapularis: Primary medial rotator of the arm, also adducts
- Rotator cuff
 - Four of scapulohumeral muscles
 - Supraspinatus
 - Infraspinatus
 - Teres minor
 - Teres major
 - Form musculotendinous cuff around glenohumeral joint
 - Blend with articular capsule to reinforce it
 - Hold head of humerus in glenoid cavity

Axilla

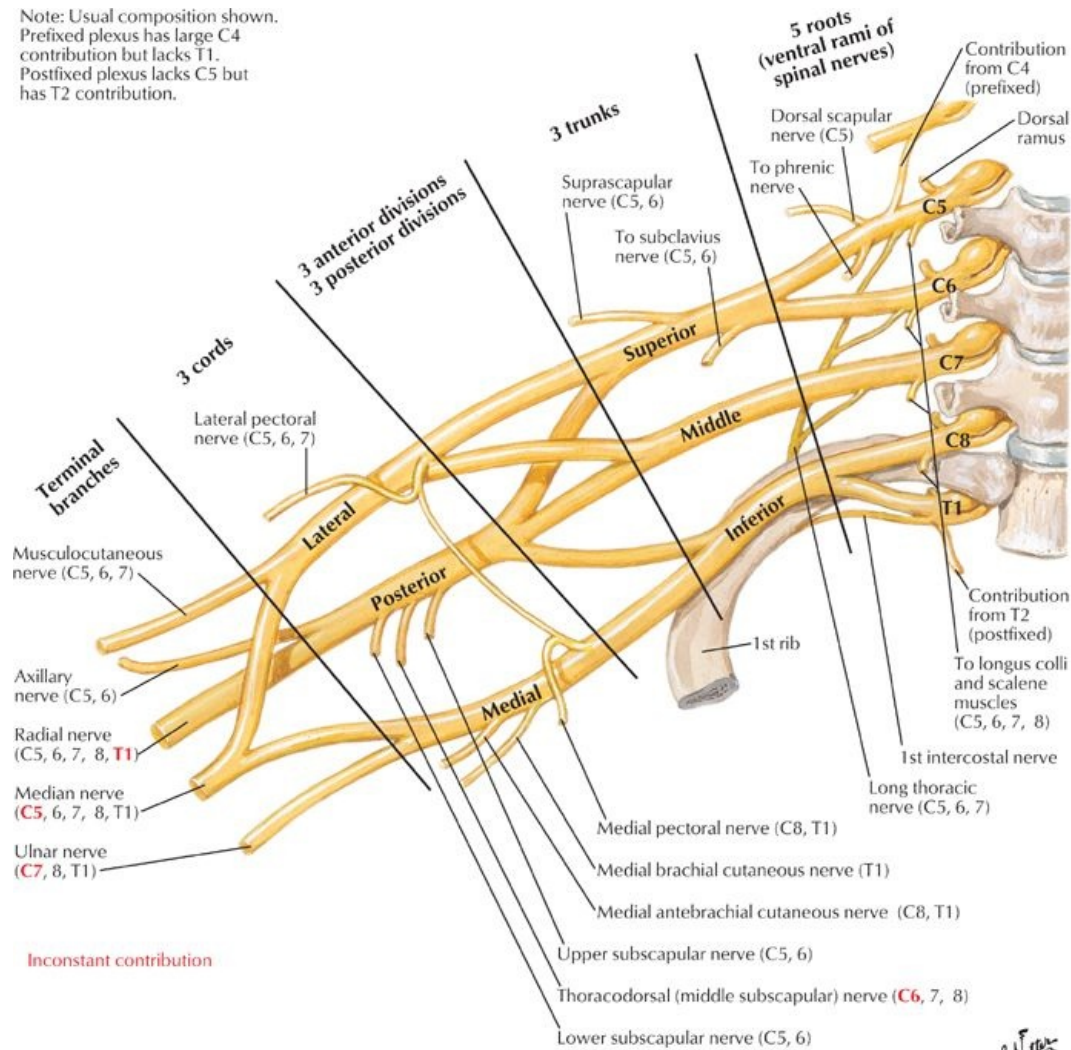


[Plate 412, Axilla: Posterior Wall and Cord]



[Plate 415, Axillary Artery and Anastomoses around Scapula]

Note: Usual composition shown.
 Prefixed plexus has large C4 contribution but lacks T1.
 Postfixed plexus lacks C5 but has T2 contribution.



[Plate 418, Brachial Plexus: Schema]

page 217
 page 218

- Pyramid-shaped area inferior to glenohumeral joint containing important neurovascular structures to the upper limb
- Boundaries
 - Base: skin of armpit and axillary fascia from arm to thoracic wall
 - Apex: bounded by the first rib, clavicle, and superior border of the scapula
 - Anterior wall (anterior axillary fold): pectoralis major and minor
 - Posterior wall (posterior fold): subscapularis, teres major, latissimus dorsi
 - Medial wall: ribs 1 through 4, serratus anterior, and intercostal muscles
 - Lateral wall: intertubercular groove of humerus
- Contents (see Section 6-6: Upper Limb: Neurovasculature for details)
 - Axillary artery and branches
 - Axillary vein and tributaries
 - Axillary lymph nodes (five major collections)
 - Brachial plexus
- Fascia
 - Pectoral fascia
 - Attaches to clavicle and sternum
 - Invests the pectoralis major
 - Extends laterally as the axillary fascia
 - Continues inferiorly with fascia of abdominal wall
 - Clavipectoral fascia
 - Invests subclavius and pectoralis minor
 - Continues superiorly as the costocoracoid membrane (pierced by the lateral pectoral nerve)
 - Axillary sheath: invests axillary artery and brachial plexus
- Axillary Lymph Nodes
 - Arranged in five main groups
 - Apical group
 - Along medial side of axillary vein and first part of axillary artery
 - Receives lymph from all other groups
 - Efferent lymphatic vessels from these nodes form subclavian lymphatic trunk
 - Pectoral (anterior) group

-
- Medial wall of axilla
 - Receives lymph from breast, anterior thoracic wall
 - Subscapular group
 - Along posterior axillary fold
 - Receives lymph from posterior thoracic wall and scapula
 - Humeral (lateral) group
 - Along lateral wall of axilla
 - Receives lymph from upper limb
 - Central group
 - Deep to pectoralis minor
 - Receives lymph from pectoral, subscapular, and humeral groups

FACTS & HINTS

HIGH-YIELD FACTS

Clinical Points

page 218
page 219

Fracture of the Clavicle

- Common, especially in children
- Usually results from a fall on outstretched hand or direct trauma to the shoulder
- Fractures of middle third are most frequently seen
- Sternocleidomastoid muscle pulls the proximal fragment superiorly and the shoulder pulls the distal fragment inferiorly
- Small lump may remain after the clavicle has healed

Calcific Supraspinatus Tendonitis

- Inflammation and calcification of the subacromial bursa resulting in pain, tenderness and limitation of movement of the shoulder joint
- Calcium deposits frequently also seen in the supraspinatus tendon
- Pain is especially severe with the arm abducted between 50 to 130 degrees (*the painful arc*) as the supraspinatus tendon is in contact with the inferior surface of the acromion here

Shoulder Dislocation

- High mobility and instability of the glenohumeral joint leads to frequent dislocation
- 95% of dislocations are in anteroinferior direction, caused by excessive extension and lateral rotation of humerus (e.g., in the throwing motion)
- Humeral head places stress on joint capsule, which may be torn anteriorly, with elements of the rotator cuff
- Axillary and musculocutaneous nerves may also be injured
- Posterior dislocation is uncommon, but may occur during epileptic seizure or electrocution

Rotator Cuff Injury

- Musculotendinous rotator cuff may be damaged by trauma or degenerative disease
- One or more of tendons may be torn when the arm is forcefully abducted, leading to pain in the anterosuperior aspect of the shoulder
- Supraspinatus tendon is most commonly involved in degenerative tendonitis
- Leads patient's arm to drop suddenly at approximately 90-degree abduction, when instructed to lower it slowly from a fully abducted position

MNEMONICS

Memory Aids

Rotator cuff muscles:	SITS = Supraspinatus, Infraspinatus, Teres minor, Subscapularis
-----------------------	---

45 Arm

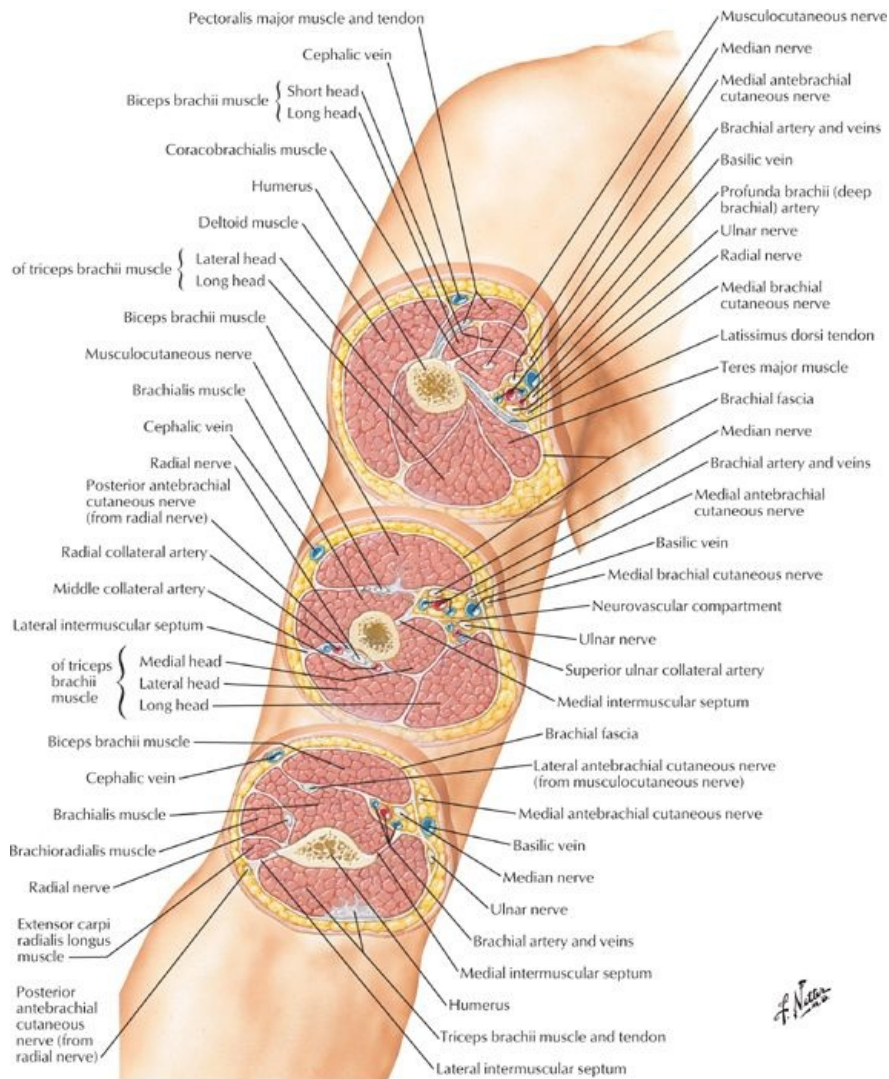
STUDY AIMS

At the end of your study, you should be able to:

- Identify the different parts and surface markings of the humerus
- Describe the organization of the deep fascia and compartments of the arm
- Know the origins, insertions, and actions of the muscles of the arm
- Know the cutaneous nerves of the arm
- Describe the boundaries and contents of the cubital fossa

GUIDE

Upper Limb: Arm



[Plate 423, Arm: Serial Cross Sections]

Humerus

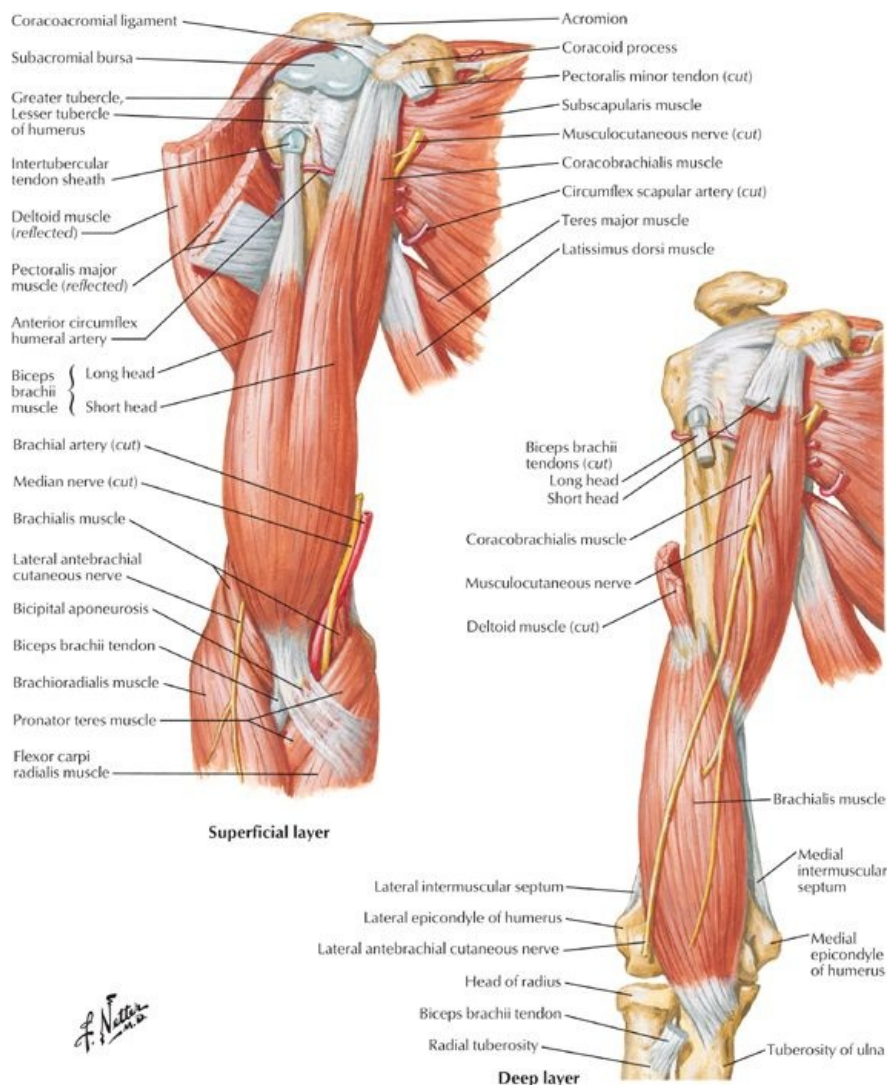
- Largest bone of the upper limb
- Osteological features
 - Head
 - Anatomical neck-circumscribes head above tubercles
 - Surgical neck: below tubercles-common site of fracture
 - Greater and lesser tubercles
 - Intertubercular groove
 - Body with
 - Deltoid tuberosity for attachment of deltoid muscle
 - Radial groove on posterior surface where radial nerve and deep brachial artery traverse
 - Medial and lateral supracondylar ridges-widening of humerus distally as sharp ridges on either side
 - Medial epicondyle
 - Prominent medial extension at distal end
 - Common origin of forearm flexors; ulnar nerve posterior
 - Lateral epicondyle
 - Prominent lateral extension at distal end
 - Common origin of forearm extensors; radial nerve posterior
 - Condyle-distal end of humerus
 - Trochlea
 - Medial articular surface of condyle
 - For articulation with trochlear notch of ulna
 - Capitulum
 - Lateral articular surface of condyle
 - For articulation with head of radius
 - Coronoid fossa (see also Section 6-4: Upper Limb: Elbow and Forearm)

- Superior to trochlea
- Receives coronoid process of ulna
- Olecranon fossae
 - Posterior distal end of humerus
 - Receives olecranon of ulna during full extension of forearm at elbow

Fascia of the Arm

- Brachial fascia
 - Sleeve of deep fascia around the arm
 - Continuous with the antebrachial fascia of the forearm
- Medial and lateral intermuscular septa
 - Extend from deep surface of brachial fascia to humerus
 - Divide arm into anterior (flexor) and posterior (extensor) compartments
- Medial septum: medial lip of intertubercular sulcus (superiorly) → medial epicondyle
- Lateral septum: lateral lip of intertubercular sulcus (superiorly) → lateral epicondyle

Muscles of the Arm



[Plate 419, Muscles of Arm: Anterior Views]

- Anterior (flexor) compartment
 - Biceps brachii
 - Flexes and supinates
 - Continues distally as bicipital aponeurosis: triangular membrane from the biceps tendon across cubital fossa and blends with antebrachial fascia over the flexor muscles of the forearm
 - Brachialis: main flexor of forearm
 - Coracobrachialis
 - Flexes and adducts arm
 - Pierced by the musculocutaneous nerve
- Posterior (extensor) compartment

- Triceps brachii
 - Main extensor of arm
 - Stabilizes head of humerus in glenohumeral joint
- Anconeus: extends arm, and resists adduction of the ulna during pronation

Muscles	Origin	Insertion	Innervation	Blood supply	Action
Biceps brachii	Long head-supraglenoid tubercle of humerus; Short head-tip of coracoid process of scapula	Radial tuberosity, fascia of forearm via bicipital aponeurosis	Musculocutaneous nerve (C5,C6)	Muscular branches of brachial artery	Supinates forearm Flexes forearm when it is supinated
Coracobrachialis	Tip of coracoid process of scapula	Middle third of medial surface of humerus	Musculocutaneous nerve (C5,C6,C7)	Muscular branches of brachial artery	Flexes and adducts arm
Brachialis	Distal half of anterior surface of humerus	Coronoid process and tuberosity of ulna	Musculocutaneous nerve (C5,C6)	Radial recurrent artery, muscular branches of brachial artery	Flexes forearm
Triceps brachii	Long head-infraglenoid tubercle of scapula; Lateral head -upper half of posterior humerus; Medial head -distal two thirds of medial and posterior humerus	Posterior surface of olecranon process of ulna	Radial nerve (C6,C7,C8)	Branch of profunda brachii artery	Extends forearm, long head stabilizes head of abducted humerus

page 221
page 222

Cutaneous Nerves of Arm

- Supraclavicular nerves (C4,C5) supply skin over shoulder
- Superior lateral cutaneous nerve (C5,C6)
 - Branch of axillary
 - Supplies skin over upper lateral arm
- Inferior lateral cutaneous nerve (C5,C6)
 - Cutaneous branch of radial nerve
 - Supplies skin over lower lateral arm
- Intercostobrachial nerve (T2)
 - Lateral cutaneous branch of second intercostal nerve
 - Supplies upper medial arm anteriorly and posteriorly
- Medial brachial cutaneous (C8-T1)
 - Branch of brachial plexus
 - Supplies lower anterior medial arm
- Posterior brachial cutaneous nerve (C5-C8)
 - Branch of radial nerve
 - Supplies lower posterior medial arm

Cubital Fossa

- Boundaries
 - Superiorly: (imaginary) line connecting the medial and lateral epicondyles
 - Medially: pronator teres muscle
 - Laterally: brachioradialis
 - Floor: brachialis and supinator muscles of arm and forearm
 - Roof: deep fascia, bicipital aponeurosis, subcutaneous tissue, and skin
- Contents
 - Brachial artery (terminal part)
 - Biceps brachii tendon
 - Nerves: median
In subcutaneous connective tissue
 - Medial and lateral antebrachial cutaneous nerves
 - Basilic and cephalic veins
 - Median cubital vein
In floor of fossa
 - Deep and superficial branches of radial nerve

FACTS & HINTS

HIGH-YIELD FACTS

Clinical Points

page 222
page 223

Fracture of the Humerus

- Fractures of the humerus most common at the surgical neck
- Especially common in elderly individuals with osteoporotic bone, falling on an outstretched arm
- The axillary nerve vulnerable to damage here
- Direct blow to the arm may
 - Fracture humerus through its midshaft, with risk of injury to the radial nerve
 - Fracture humerus at distal end, risking damage to the median nerve

Biceps Tendonitis

- Is inflammation of the tendon of the long head of the biceps
- Tendon is susceptible to wear and tear as it moves back and forth within the intertubercular groove
- Degenerative wear a common cause of shoulder pain
- Inflammation also caused by repetitive microtrauma, seen in certain sports such as tennis

Rupture of the Biceps Brachii

- This produces "Popeye deformity" with muscle forming a ball in distal part of the anterior arm
- Tendon of long head has the highest rate of spontaneous rupture of any tendon in the body
- Rupture of the tendon on background of chronic tendonitis usually affects those older than 40
- Traumatic rupture may occur in younger individuals, but is rare

MNEMONICS

Memory Aids

Cubital fossa (from medial to lateral):	M adeline	M edian Nerve
	B rown's	B rachial Artery
	B ig	B iceps tendon
	R ed	R adial Nerve
	P urse	P osterior interosseous nerve

46 Elbow and Forearm

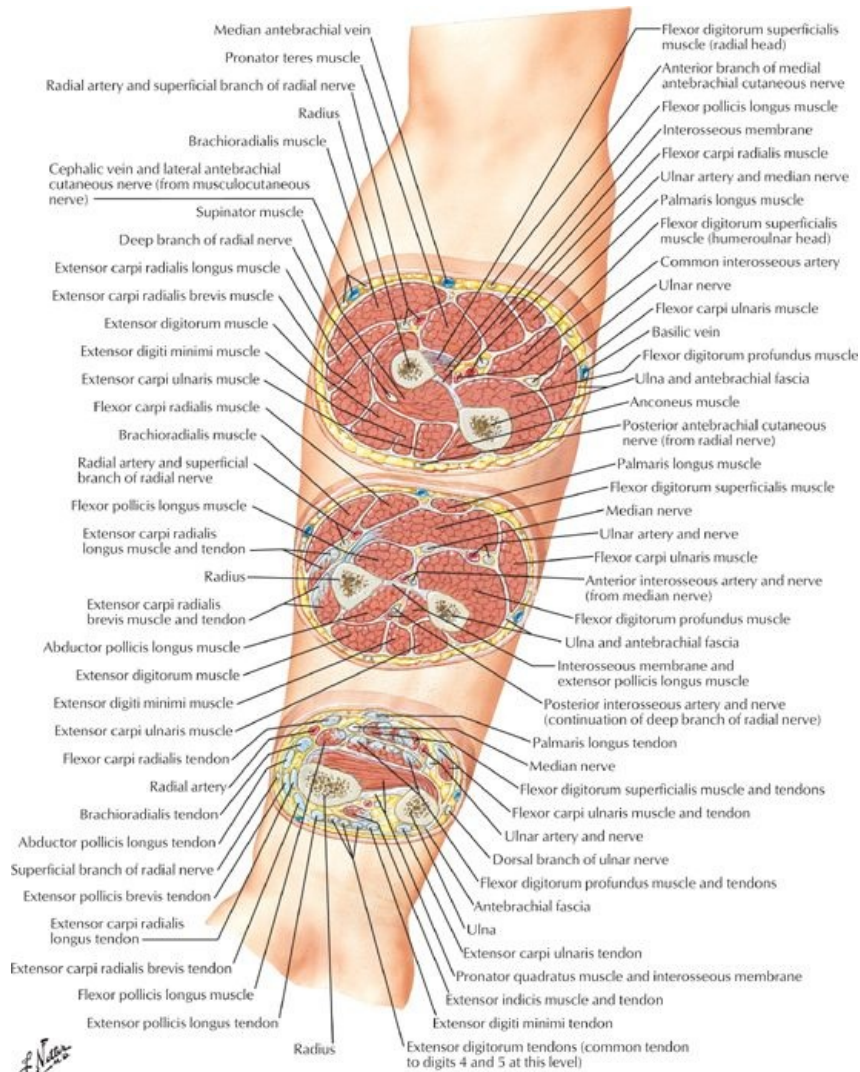
STUDY AIMS

At the end of your study, you should be able to:

- Identify the different parts and surface markings of the radius and ulna
- Describe the articulations of the elbow joint, its movements, and supporting ligaments
- Describe the distal radioulnar joint, its movements, and supporting ligaments
- Describe the organization of the deep fascia and compartments of the arm
- Know the origins, insertions, and actions of the major muscles of the forearm

GUIDE

Upper Limb: Elbow and Forearm



[Plate 437, Forearm: Serial Cross Sections]

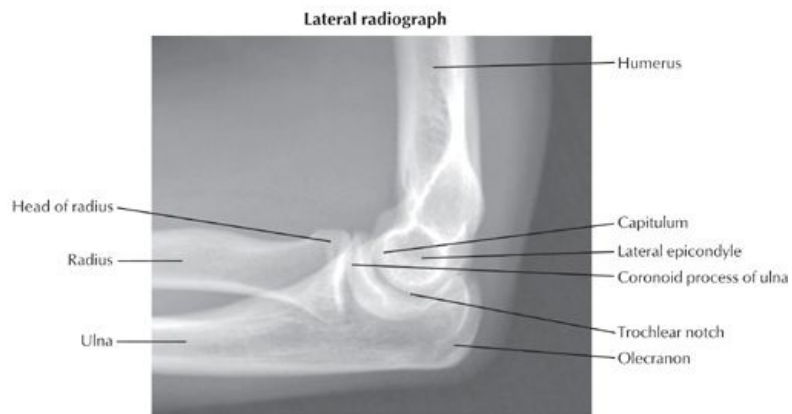
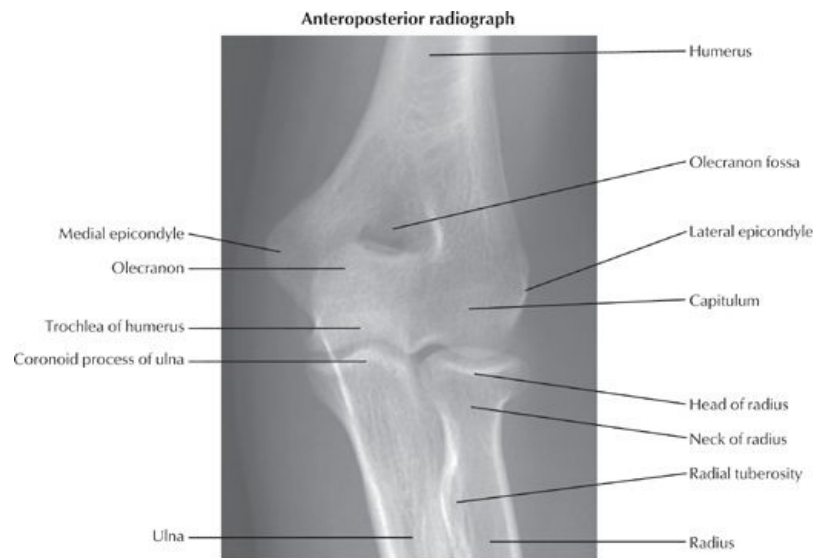Bones

page 224
page 225

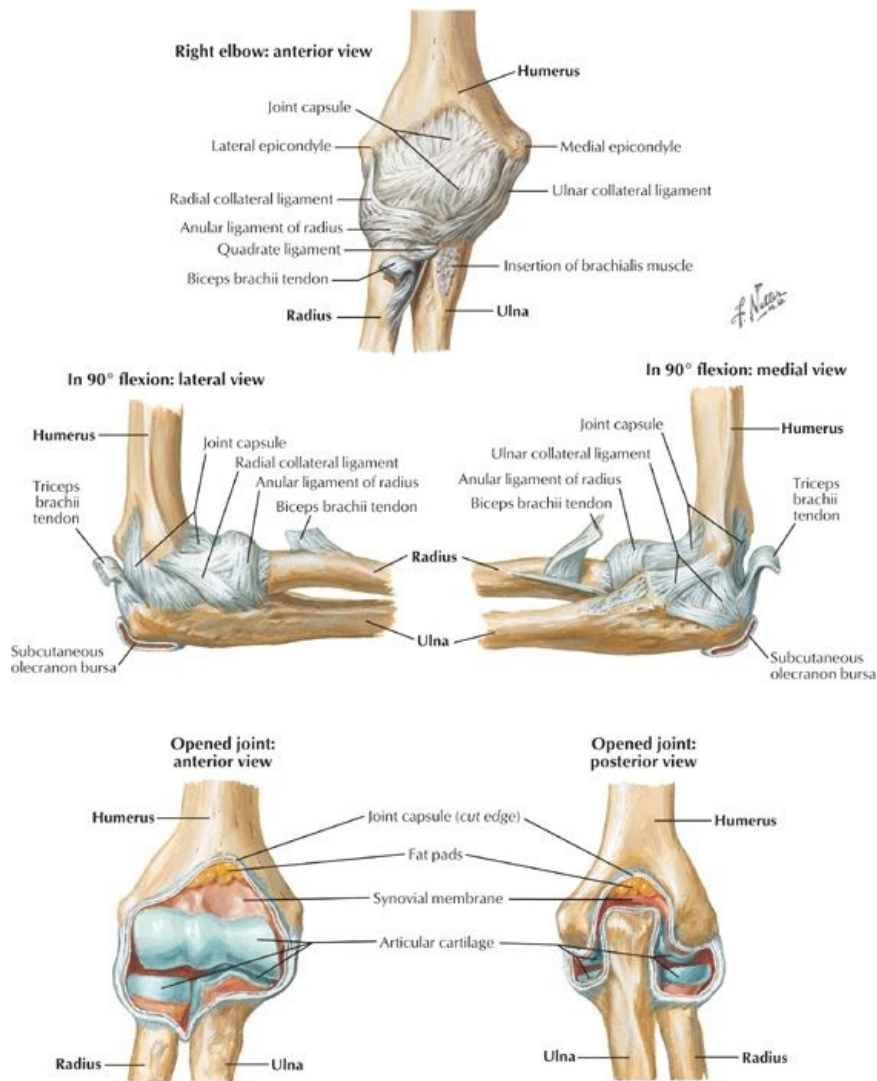
- Ulna
 - Stabilizing bone of the forearm
 - Medial to and longer than radius
 - Osteological features
 - Olecranon-projection of proximal posterior end
 - Coronoid process-projection from proximal anterior end
 - Trochlear notch-anterior surface of olecranon, articulates with trochlea of humerus
 - Radial notch-rounded concavity on lateral side of coronoid process for radial head
 - Ulnar tuberosity-inferior to coronoid process for attachment of brachialis muscle
 - Supinator crest-crest inferior to radial notch for attachment of supinator muscle
 - Supinator fossa-concavity between supinator crest and coronoid process, for attachment of supinator muscle
 - Body-thicker proximally, tapering distally
 - Head-at distal end
 - Styloid process-conical process from the head
- Radius
 - Lateral and shorter bone of the forearm
 - Osteologic features
 - Head-at proximal end, concave for articulation with capitulum of humerus
 - Neck-constricted region between head and tuberosity
 - Radial tuberosity-oval protuberance below head and neck for attachment of biceps brachii
 - Body-convex laterally and enlarging distally
 - Styloid process-projection from lateral aspect of distal end of radius
 - Dorsal tubercle-dorsal projection at distal end between grooves for tendon of extensor carpi radialis longus and brevis and tendon of extensor pollicis longus

- Ulnar notch-concavity on medial side of distal end for head of ulna
- Radius and ulna connected by
 - Interosseous membrane
 - Separates forearm into anterior and posterior compartments
 - Provides attachment for deep muscles of forearm
 - Fibers slope downward from radius to ulna
 - Is most tense when hand is in mid-prone position
 - Has a gap distal to neck of radius for posterior interosseus vessels
 - Oblique cord
 - Crosses gap in interosseus membrane
 - Attaches neck of radius to ulnar tuberosity
 - Radioulnar joints-proximal and distal (*see below*)

Elbow Joint



[Plate 425, Elbow: Radiographs]



[Plate 426, Ligaments of Elbow]

page 225
page 226

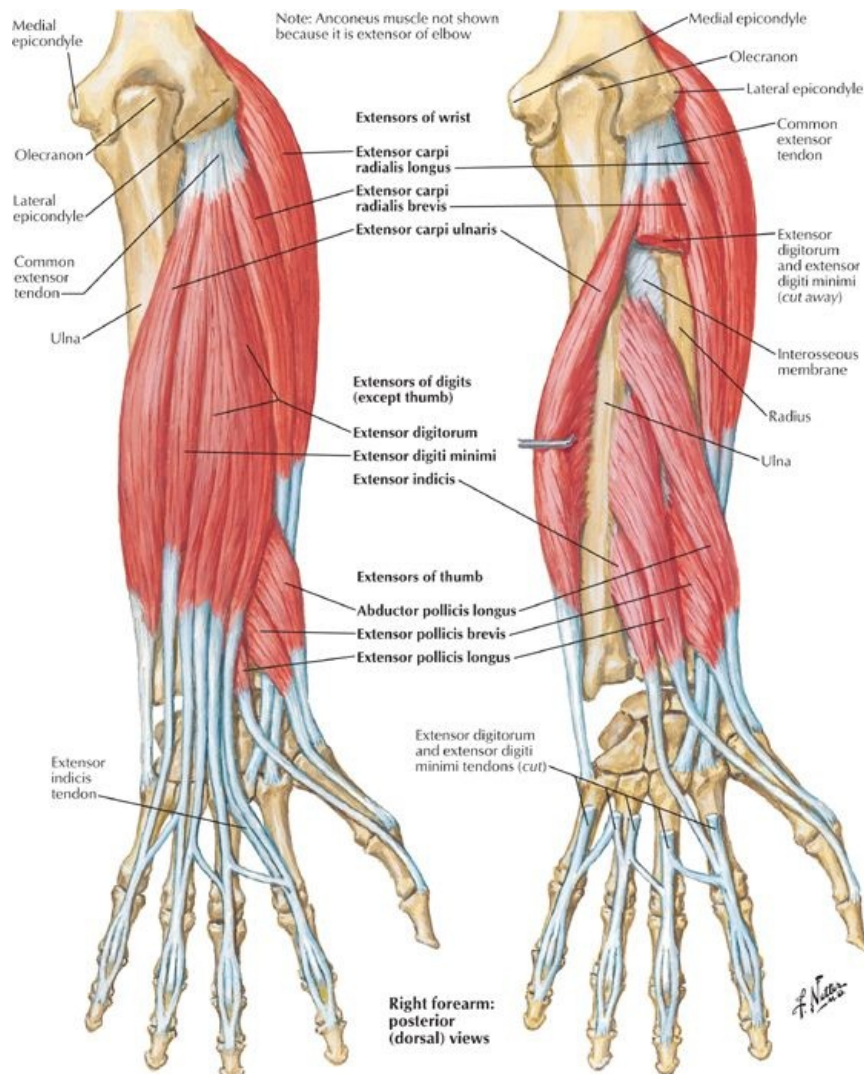
- Compound synovial joint in which radius and ulna articulate with humerus
- Joint cavity continuous with radioulnar joint
- Fibrous capsule encloses all three articulations
- Humeroulnar joint
 - Uniaxial, synovial hinge joint
 - Between trochlea of humerus and trochlear notch of ulna
- Humeroradial joint
 - Uniaxial, synovial hinge joint
 - Between capitulum of humerus and head of radius
- Blood supply to humeroulnar and humeroradial joints: anastomoses around elbow from brachial, radial, and ulnar arteries
- Nerve supply to these joints: musculocutaneous, radial, and ulnar nerves
- Proximal radioulnar joint
 - Uniaxial, synovial pivot joint
 - Between head of the radius and radial notch of the ulna
 - Blood supply: anterior and posterior interosseous arteries
 - Nerve supply: musculocutaneous, median and ulnar nerves
- Ligaments reinforcing elbow joint
 - Ulnar collateral ligament: medial epicondyle to coronoid process and olecranon
 - Radial collateral ligament: lateral epicondyle to annular ligament
 - Annular ligament
 - Strong fibrous circle
 - From margins of radial notch of ulna
 - Encircles head of radius
 - Maintains position of the radial head during pronation and supination
- Movements at the elbow joint
 - Flexion (~180 degrees) and extension at humeroulnar and humeroradial joints
 - Pronation and supination with rotation of the head of the radius within annular ligament at proximal radioulnar joint
- Distal radioulnar joint
 - Synovial pivot joint
 - Articulation between ulnar notch and articular facet of radius at its distal end

- Fibrocartilaginous articular disc binds the ends of the radius and ulna and is strengthened by anterior and posterior ligaments
- Disc separates cavity of joint from cavity of wrist joint
- Pronation and supination: distal end of radius moves anteriorly and medially across the ulna
- Blood supply: anterior and posterior interosseous arteries
- Nerve supply: posterior interosseous nerve
- Carrying angle
 - The angle between the long axis of the humerus and the long axis of the ulna with forearm fully extended and supinated in the anatomical position
 - Ten to 15 degrees in males, more than 15 degrees in females (*figures are for deviations from 180 degrees*)
- Bursae (*important ones*)
 - Subcutaneous olecranon bursa: Overlies olecranon in subcutaneous tissue
 - Subtendinous olecranon bursa: Between the olecranon and triceps tendon
 - Bicipitoradial bursa: Between biceps tendon and anterior part of radial tuberosity

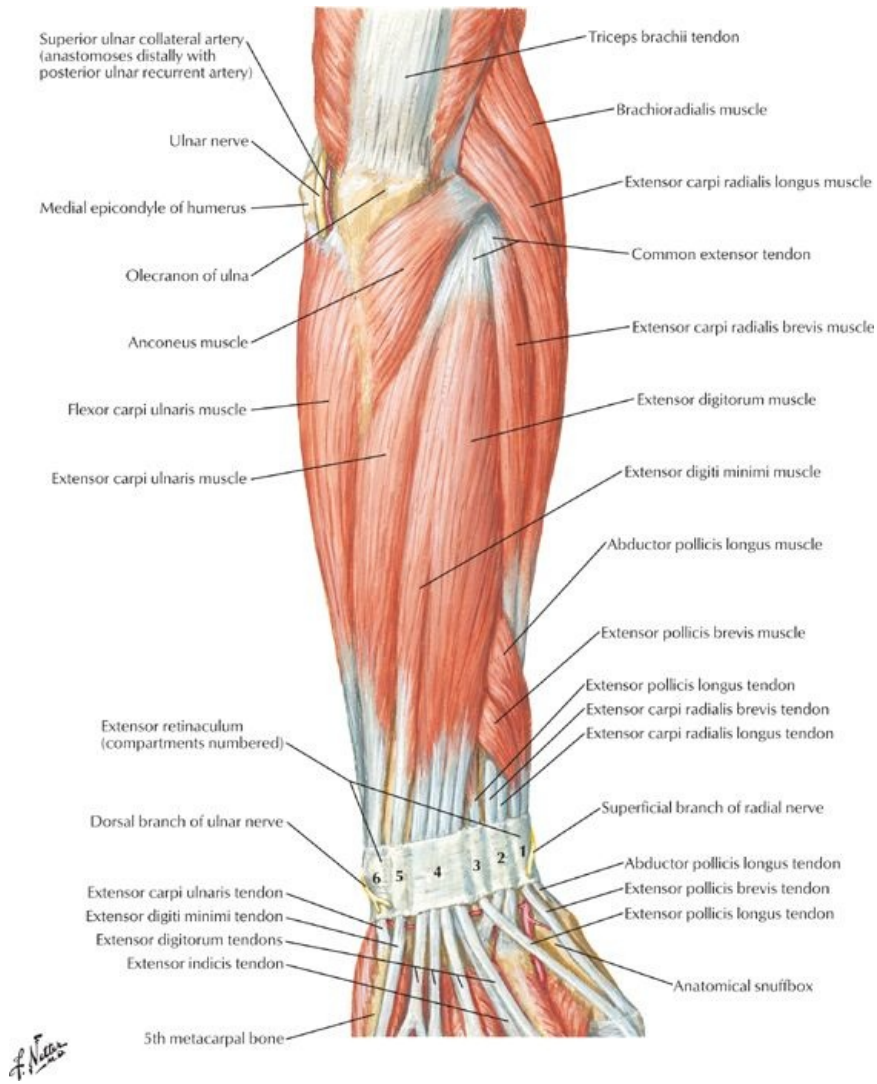
Fascial Compartments of Forearm

- Forearm divided into anterior and posterior compartments by interosseous membrane
- Antebrachial fascia is thickened at distal end of radius
 - Posteriorly forms extensor retinaculum
 - Anteriorly forms palmar carpal ligament
 - Also forms flexor retinaculum (transverse carpal ligament) distal and deeper to palmar carpal ligament
- Carpal tunnel formed between flexor retinaculum, running between tubercles of scaphion and trapezium radially to pisiform and hook of hamate on ulnar side, and anterior concavity of the carpus

Muscles of the Forearm (*listed from lateral to medial*)

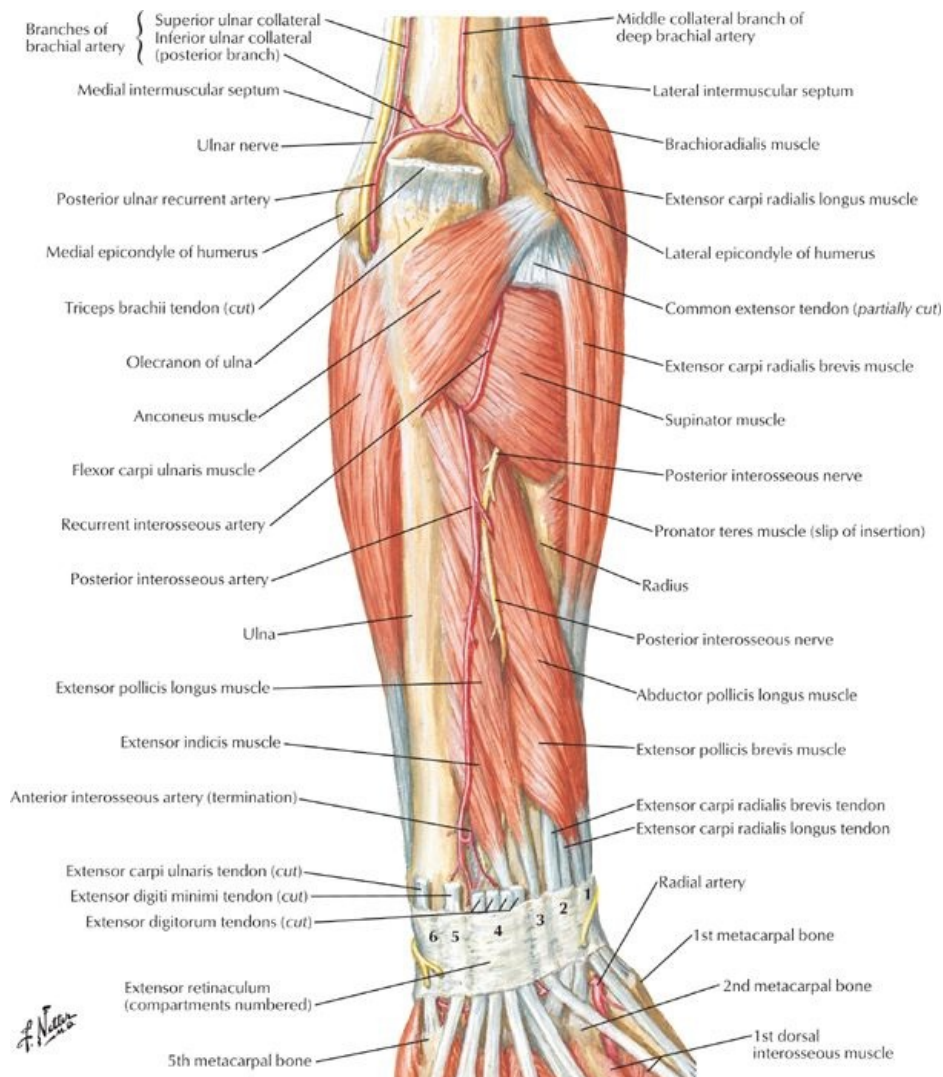


[Plate 429, Individual Muscles of Forearm: Extensors of Wrist and Digits]



[Plate 432, Muscles of Forearm (Superficial Layer): Posterior View]

F. Netter



[Plate 433, Muscles of Forearm (Deep Layer): Posterior View]

Muscle	Origin	Insertion	Innervation	Blood supply	Action
Pronator Teres	Two heads: medial epicondyle of humerus and coronoid process of ulna	Midway along lateral surface of radius	Median nerve (C6,C7)	Anterior ulnar recurrent artery	Pronates forearm, assists in flexion
Flexor carpi radialis	Medial epicondyle of humerus	Base of second metacarpal	Median nerve (C6,C7)	Radial artery	Flexes and abducts hand at wrist
Palmaris longus	Medial epicondyle of humerus	Distal half of flexor retinaculum and palmar aponeurosis	Median nerve (C7,C8)	Posterior ulnar recurrent artery	Flexes hand and tenses palmar aponeurosis
Flexor carpi ulnaris	Humeral head: medial epicondyle of humerus; Ulnar head: olecranon and posterior border of ulna	Pisiform bone, hook of hamate, base of fifth metacarpal	Ulnar nerve (C7,C8 and T1)	Posterior ulnar recurrent artery	Flexes and adducts hand at wrist
Flexor digitorum superficialis	Humeral head: medial epicondyle and coronoid process of ulna Radial head: anterior border of radius	Bodies of middle phalanges of medial four digits	Median nerve (C8-T1)	Ulnar and radial arteries	Flexes middle and proximal phalanges of medial four digits; also flexes hand at wrist

page 226
page 227

Muscle	Origin	Insertion	Innervation	Blood supply	Action
Deep					
Flexor digitorum profundus	Medial and anterior surface of proximal three-quarters of ulna, and interosseous membrane	Anterior base of distal phalanges of medial four digits	Medial part: ulnar nerve (C8-T1); Lateral part: median nerve (C8-T1)	Anterior interosseous artery and muscular branches of ulnar artery	Flexes distal phalanges of medial four digits; assists in flexion of hand at wrist

Flexor pollicis longus	Anterior surface of radius and interosseous membrane	Palmar base of distal phalanx of thumb	Anterior interosseous branch of median nerve (C7-8)	Anterior interosseous artery	Flexes phalanges of thumb
Pronator quadratus	Distal fourth of anterior ulna	Distal fourth of anterior radius	Anterior interosseous branch of median nerve (C7-8)	Anterior interosseous artery	Pronates forearm
Muscle	Origin	Insertion	Innervation	Blood supply	Action
Brachioradialis	Proximal two thirds of lateral supracondylar ridge of humerus	Lateral side of distal end of radius	Radial nerve (C5-C6)	Radial recurrent artery	Flexes forearm
Extensor carpi radialis longus	Distal one-third of lateral supracondylar ridge of humerus	Dorsal base of second metacarpal	Radial nerve (C6-C7)	Radial artery and radial recurrent artery	Extends and abducts hand at wrist
Extensor carpi radialis brevis	Lateral epicondyle of humerus (common extensor tendon)	Dorsal base of third metacarpal	Deep branch of radial nerve (C7-C8)	Radial artery and radial recurrent artery	Extends and abducts hand at wrist
Extensor digitorum	Lateral epicondyle of humerus (common extensor tendon)	Extensor expansions of medial four digits	Posterior interosseous nerve (C7-C8)	Posterior interosseous artery	Extends medial four digits; assists in wrist extension
Extensor digiti minimi	Lateral epicondyle of humerus (common extensor tendon)	Extensor expansion of fifth digit	Posterior interosseous nerve (C7-C8)	Posterior interosseous artery	Extends fifth digit
Extensor carpi ulnaris	Lateral epicondyle of humerus and posterior border of ulna (common extensor tendon)	Dorsal base of fifth metacarpal	Posterior interosseous nerve (C7-C8)	Posterior interosseous artery	Extends and abducts hand at wrist
Anconeus	Posterior surface of lateral epicondyle of humerus	Lateral surface of olecranon and posterior proximal ulna	Radial nerve (C5-7)	Deep brachial artery	Assists triceps in extending elbow; abducts ulna during pronation
Muscle	Origin	Insertion	Innervation	Blood supply	Action
Supinator	Lateral epicondyle of humerus, supinator crest	Lateral, posterior and anterior surfaces of proximal third of radius	Deep branch of radial nerve (C6-C7)	Radial recurrent and posterior interosseous arteries	Supinates forearm
Abductor pollicis longus	Posterior surface of ulna, radius, and interosseous membrane	Base of first metacarpal	Posterior interosseous nerve (C7-C8)	Posterior interosseous artery	Abducts and extends thumb
Extensor pollicis brevis	Posterior surface of radius and interosseous membrane	Base of proximal phalanx of thumb	Posterior interosseous nerve (C7-C8)	Posterior interosseous artery	Extends proximal phalanx of thumb
Extensor pollicis longus	Posterior surface of middle third of ulna and interosseous membrane	Base of distal phalanx of thumb	Posterior interosseous nerve (C7-C8)	Posterior interosseous artery	Extends distal phalanx of thumb
Extensor indicis	Posterior surface of ulna and interosseous membrane	Extensor expansion of second digit	Posterior interosseous nerve (C7-C8)	Posterior interosseous artery	Extends second digit

- Anterior (flexor) compartment
 - Superficial group (origin at medial epicondyle)
 - Pronator teres (pronates forearm)
 - Flexor carpi radialis (flexes and abducts wrist)
 - Palmaris longus (absent in some individuals; tenses palmar aponeurosis)
 - Flexor carpi ulnaris (flexes and adducts wrist)
 - Flexor digitorum superficialis (flexes PIP joints via four tendons)
 - Deep group
 - Flexor digitorum profundus (flexes at DIP joint)
 - Flexor pollicis longus (flexes thumb)
 - Pronator quadratus (pronates forearm)
- Posterior (extensor) compartment
 - Superficial group (origin at lateral epicondyle)
 - Brachioradialis (flexes elbow)
 - Extensor carpi radialis longus and brevis (extend and abduct wrist)
 - Extensor digitorum (extends fingers)
 - Extensor digiti minimi (extends fifth digit)
 - Extensor carpi ulnaris (extends and adducts wrist)
 - Anconeus (extends elbow)
 - Deep group (originate from shaft of radius, ulna, and interosseous membrane)
 - Supinator (supinates forearm)
 - Abductor pollicis longus (abduct thumb)

-
- Extensor pollicis brevis and longus (extend thumb)
 - Extensor indicis (extend index finger)

FACTS & HINTS

HIGH-YIELD FACTS

Clinical Points

Subluxation of the Radial Head (*Nursemaid Elbow*)

- Caused by sudden pulling on the upper limb with the forearm pronated
- Distal attachment of the annular ligament is torn and radial head slips out, trapping the ligament between it and the capitulum
- Preschool children, especially girls, most vulnerable
- Head of radius is repositioned by supinating forearm fully and then flexing elbow

Bursitis of the Elbow

- Repeated pressure or friction on a bursa may cause it to become inflamed and tender
- Subcutaneous olecranon bursitis ("*student's elbow*") most common, often occurring in students (from resting elbows on desk), darts players and from falls and abrasions to the elbow
- Subtendinous olecranon bursitis less common, as is bicipitoradial bursitis

Epicondylitis

- Activities involving repetitive movements of wrist may lead to localized elbow pain
- Repeated extension of wrist causes lateral epicondylitis ("*tennis elbow*")-microtrauma of common extensor muscle origin, with pain felt over the lateral aspect of the elbow
- Medial epicondylitis ("*golfer's elbow*") from repeated wrist flexion, with pain felt over the medial epicondyle, especially on resisted wrist flexion
- Bursitis or synovitis may coexist with epicondylitis

MNEMONICS

Memory Aids

Radial nerve innervates the BEST!	B rachioradialis
	E xtensors
	S upinator
	T riceps
Muscles that flex the elbow:	Three B's Bend the el B ow
	B rachialis B iceps
	B rachioradialis

47 Wrist and Hand

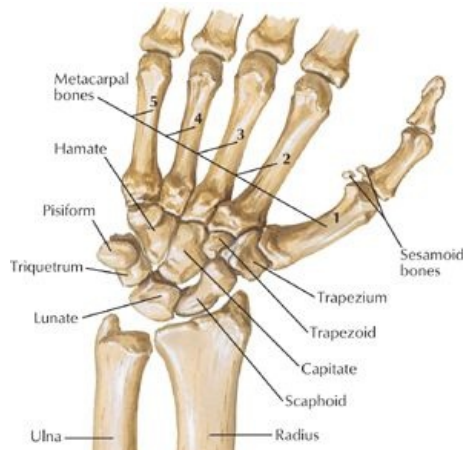STUDY AIMS

At the end of your study, you should be able to:

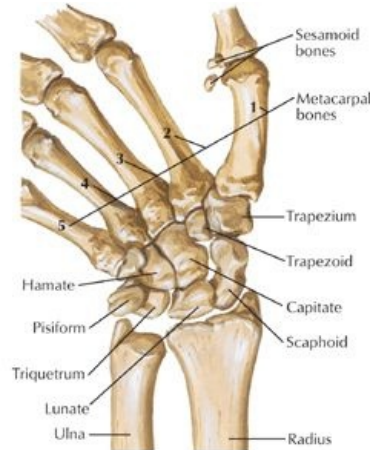- Describe the radiocarpal joint, its movements, and supporting ligaments
- Know the bones of the hand and their organization
- Describe the movements at the carpometacarpal, metacarpophalangeal, and interphalangeal joints
- Describe the organization of the deep fascia of the hand
- Understand the arrangement of the intrinsic muscles of the hand

GUIDE

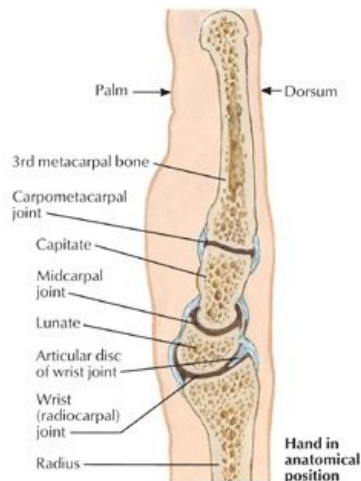
Upper Limb: Wrist and Hand



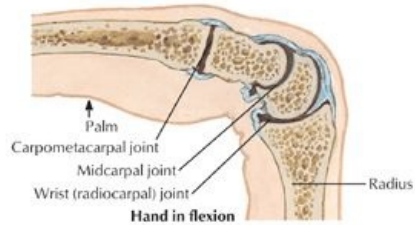
Position of carpal bones with hand in abduction: anterior (palmar) view



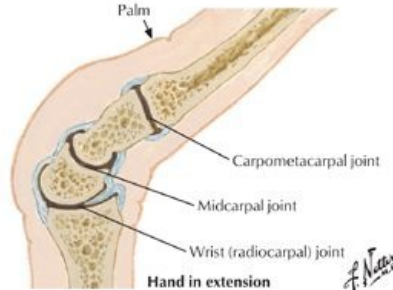Position of carpal bones with hand in adduction: anterior (palmar) view



Sagittal sections through wrist and middle finger



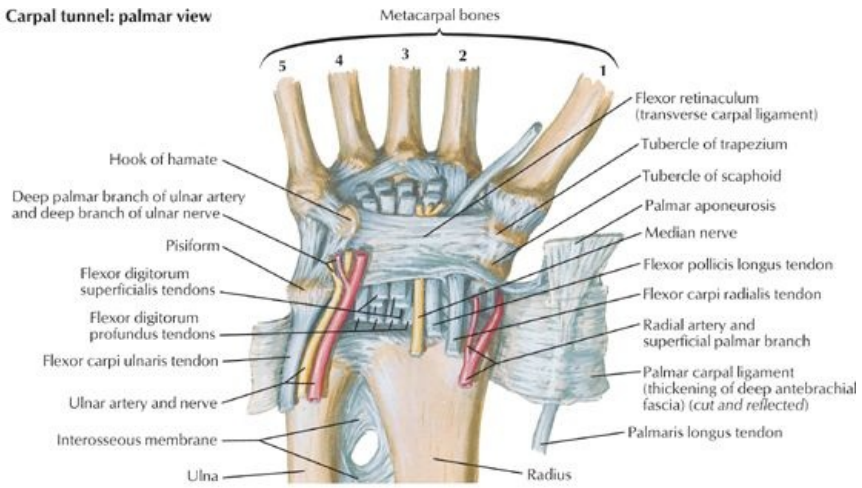
Hand in flexion



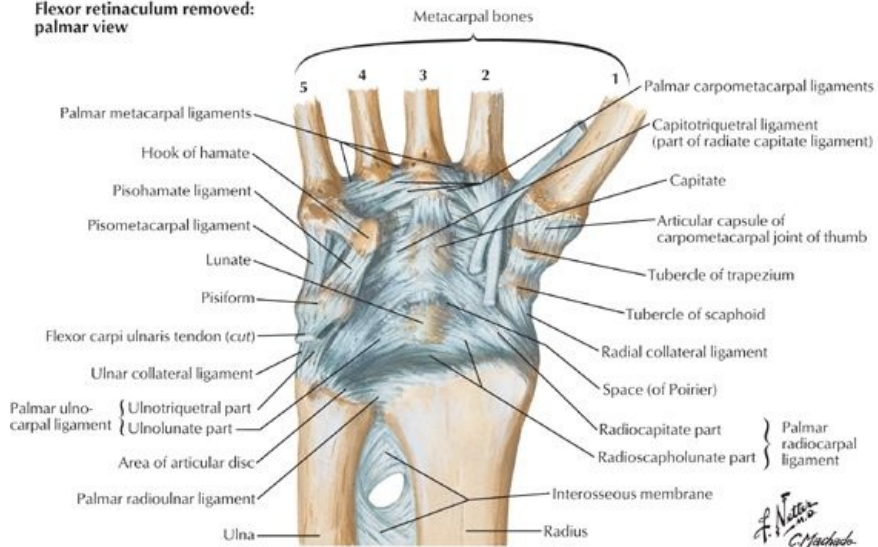
Hand in extension

[Plate 441, Movement of Wrist]

Carpal tunnel: palmar view



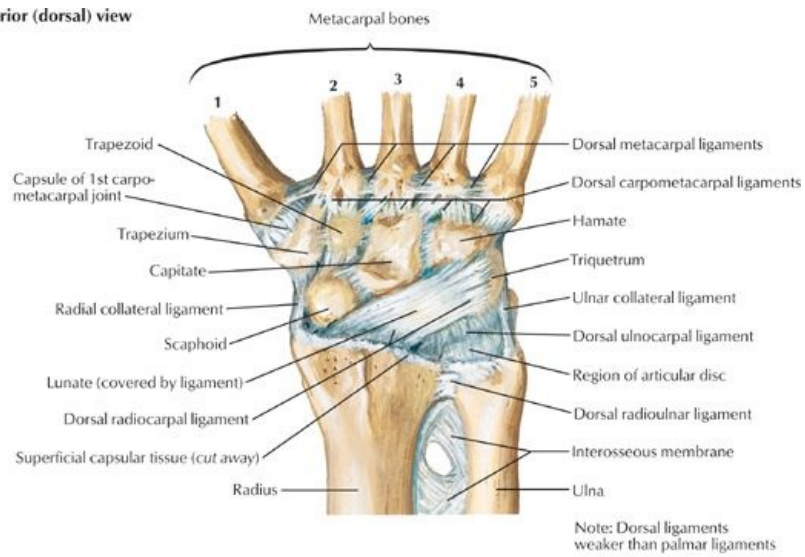
Flexor retinaculum removed: palmar view



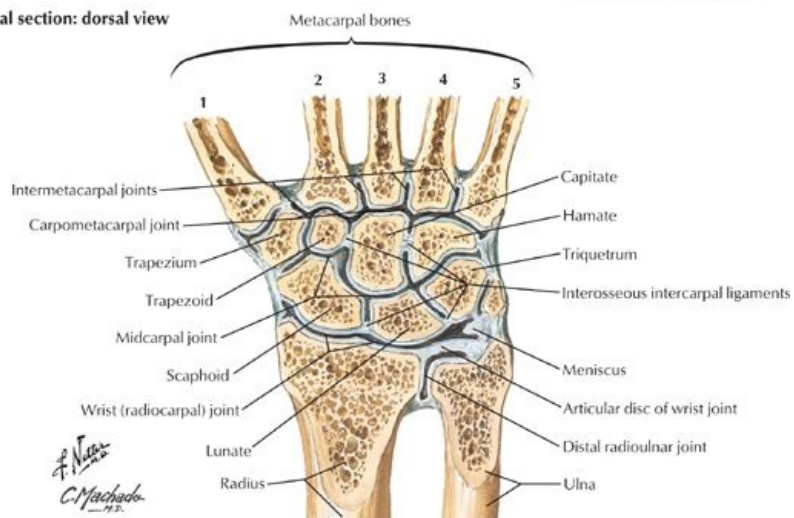
[Plate 442, Ligaments of Wrist]

A. N. N. S.
C. Machado

Posterior (dorsal) view

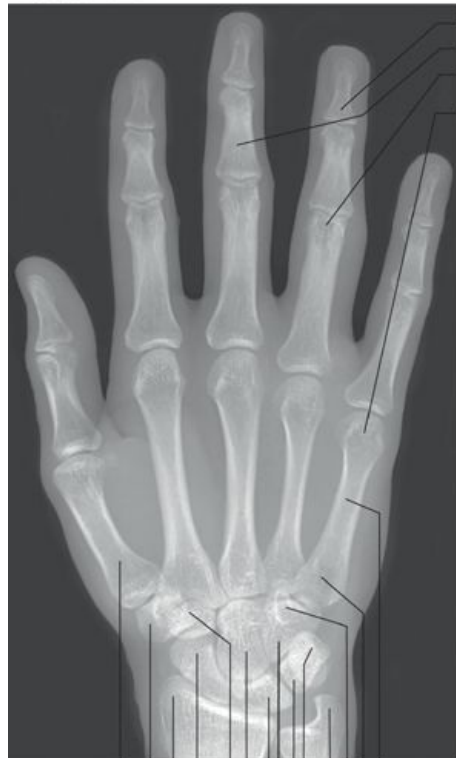

Coronal section: dorsal view



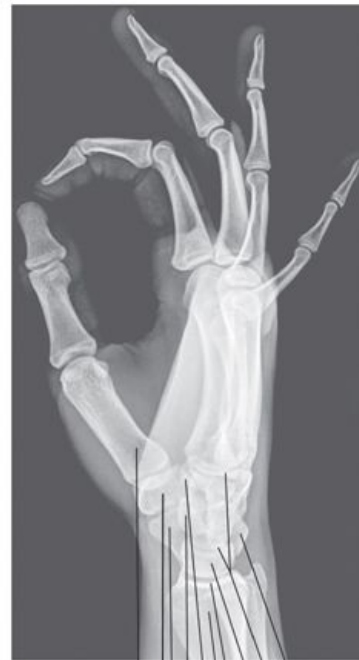[Plate 443, Ligaments of Wrist (Continued)]

Anteroposterior view



- Distal phalanx of ring finger
- Middle phalanx of middle finger
- Head of proximal phalanx
- Head of 5th metacarpal

Lateral view

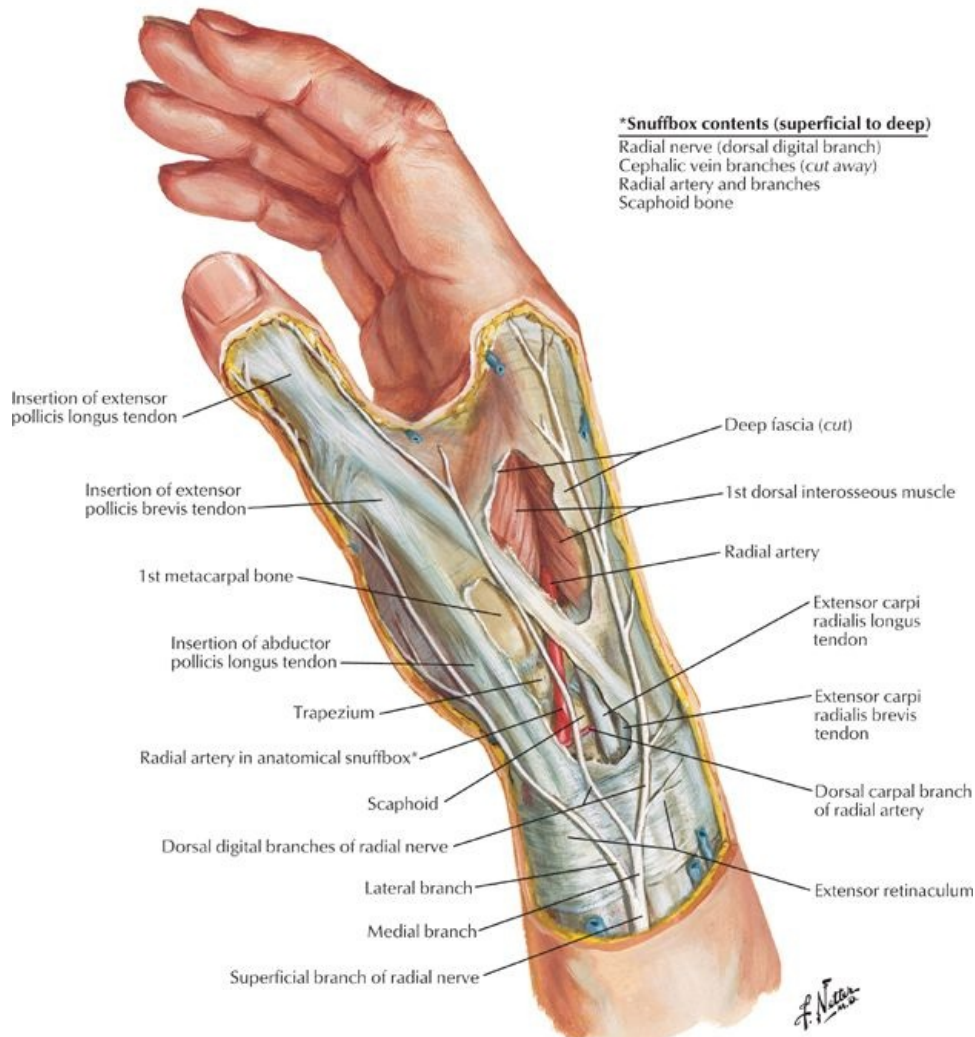


- Shaft of 5th metacarpal
- Base of 5th metacarpal
- Hook of hamate
- Styloid process of ulna
- Pisiform
- Triquetrum
- Hamate
- Lunate
- Capitate
- Trapezoid
- Scaphoid
- Styloid process of radius
- Trapezium
- Base of thumb metacarpal

- Triquetrum
- Capitate
- Lunate
- Articular surface of radius
- Radius (distal end)
- Hook of hamate
- Pisiform
- Scaphoid
- Trapezium
- First metatarsal

[Plate 445, Wrist and Hand Radiographs]

Lateral (radial) view



[Plate 455, Wrist and Hand: Superficial Radial Dissection]

Wrist (Radiocarpal) Joint

- Biaxial synovial joint
 - Located at a line joining the styloid processes of the radius and ulna
 - Articulation of distal end of radius and articular disc of radioulnar joint with the proximal row of carpal bones (except the pisiform)
 - Fibrous capsule surrounds the wrist
 - From distal ends of radius and ulna to proximal row of carpal bones
 - Lined by a synovial membrane with numerous folds
 - Movements
 - Flexion/extension
 - Abduction/adduction (radial/ulnar abduction)
 - Circumduction
 - Adduction greater than abduction
 - Ligaments
 - Dorsal and palmar radiocarpal ligaments from the radius to the two rows of carpals on the palmar and dorsal sides
 - Ulnar collateral ligament from the ulnar styloid process to the triquetrum
 - Radial styloid ligament from the radial styloid process to the scaphoid
 - Blood supply: Branches of the dorsal and palmar carpal arches
 - Nerve supply
 - Anterior interosseous branch of median nerve
 - Posterior interosseous branch of radial nerve
 - Dorsal and deep branches of ulnar nerve

Hand

- Bones (27)
 - Carpal bones (bones of the wrist or carpus)
 - Proximal row: Scaphoid, lunate, triquetrum, pisiform,
 - Distal row: Trapezium, trapezoid, capitate, hamate
 - Metacarpals (5) consist of

- Base (proximal)-articulate with distal row of carpal bones
- Body
- Head (distal)-articulate with proximal phalanges and form knuckles
- Phalanges (14)
 - Each digit has three phalanges: proximal, middle, and distal, except for
 - Thumb (has two)
 - Each phalanx has a base (proximal), body, and head (distal)
 - Decrease in size from proximal to distal

Major Joints of the Hand

- Carpometacarpal, metacarpophalangeal, and interphalangeal are all synovial joints supplied by branches of adjacent vessels and nerves
- Intercarpal joints
 - Joints between carpal bones of first row and joints between carpal bones of second row
 - Midcarpal joint between first and second rows
 - Supported by anterior, posterior, and interosseous ligaments
 - Function as a single unit
 - Small gliding movements between carpal bones
- Carpometacarpal joints
 - Plane type synovial joints, except for carpometacarpal of thumb (saddle type)
 - Medial four carpometacarpal joints in one fibrous joint capsule
 - Separate capsule for thumb
 - Joint for thumb between the trapezium and first metacarpal
 - Allows flexion, extension, abduction, adduction, circumduction, and opposition
 - Loose joint capsule allows for free movement
- Metacarpophalangeal joints (MCP)
 - Heads of metacarpals articulate with base of proximal phalanx
 - Deep transverse metacarpal ligaments hold heads of metacarpals 2 through 5 together
 - Separate joint capsule for each joint
 - Movements: flexion, extension, abduction, and adduction
 - Because the collateral ligaments tighten during flexion, abduction, and adduction are only possible in the extended position
- Interphalangeal joints
 - Proximal interphalangeal joint = PIP
 - Distal interphalangeal joint = DIP
 - Allow flexion and extension

Fascia of the Hand

- Extensor and flexor retinaculum continuous with antebrachial fascia
- Palmar fascia thickened centrally as the palmar aponeurosis
 - Four distinct extensions to the bases of the fingers
 - Continuous with the fibrous tendon sheaths
 - Anchored tightly to skin of palm by numerous ligamentous bands (retinacula cutis)
- Fibrous digital sheaths surround synovial sheaths that enclose superficial and deep flexor tendons
- Medial fibrous septum extends from medial border of palmar aponeurosis to fifth metacarpal
- Lateral fibrous septum extends from lateral border of palmar aponeurosis to third metacarpal
- Septa create compartments within the palm

Muscles of the Hand

page 231
page 232

- Adductor pollicis
- Thenar (lateral) compartment
 - Abductor pollicis brevis
 - Flexor pollicis brevis
 - Opponens pollicis
- Hypothenar (medial) compartment
 - Abductor digiti minimi
 - Flexor digiti minimi brevis
 - Opponens digiti minimi
- Short muscles of the hand
 - Lumbricals-unusual in that they flex MCP joints and extend IP joints
 - Palmar interossei-adduct digits
 - Dorsal interossei-abduct digits
- Palmaris brevis
 - Winkles skin of hypothenar eminence
 - Improves palmar grip

Muscle	Origin	Insertion	Innervation	Action	Blood Supply
Abductor pollicis brevis	Flexor retinaculum, tubercles of scaphoid and trapezium	Lateral side of base of proximal phalanx of thumb (1st digit)	Recurrent branch of median nerve (C8-T1)	Abducts and assists in opposition of thumb	Superficial palmar branch of radial artery

Flexor pollicis brevis	Flexor retinaculum and trapezium	Lateral side of base of proximal phalanx of thumb	Recurrent branch of median nerve (C8-T1)	Flexes proximal phalanx of thumb	Superficial palmar branch of radial artery
Opponens pollicis	Flexor retinaculum and trapezium	Lateral side of 1st metacarpal	Recurrent branch of median nerve (C8-T1)	Draws 1st metacarpal forward and rotates it medially	Superficial palmar branch of radial artery
Adductor pollicis	Oblique head-bases of second and third metacarpals capitate and adjacent bones; Transverse head-anterior surface of third metacarpal	Medial side of base of proximal phalanx of thumb	Deep branch of ulnar nerve (C8-T1)	Adducts thumb	Deep palmar arch
Palmaris brevis	Palmar aponeurosis	Skin of ulnar border of palm	Superficial palmar branch of ulnar nerve (C8)	Deepens the hollow of the hand	Superficial palmar arch
Abductor digiti minimi (hand)	Pisiform bone, tendon of flexor carpi ulnaris	Medial side of base of proximal phalanx of little finger	Deep branch of ulnar nerve (C8-T1)	Abducts the little finger (fifth digit)	Deep palmar branch of ulnar artery
Flexor digiti minimi brevis (hand)	Flexor retinaculum and hook of hamate bone	Medial side of base of proximal phalanx of little finger	Deep branch of ulnar nerve (C8-T1)	Flexes proximal phalanx of the little finger	Deep palmar branch of ulnar artery
Opponens digiti minimi	Flexor retinaculum and hook of hamate bone	Medial side of fifth metacarpal	Deep branch of ulnar nerve (C8-T1)	Draws fifth metacarpal anteriorly and rotates it to face thumb	Deep palmar branch of ulnar artery
Lumbricals 1 and 2	Lateral two tendons of flexor digitorum profundus	Lateral sides of extensor expansion of digits 2 and 3	Median nerve (C8-T1)	Extends digits at interphalangeal joints and flexes metacarpophalangeal joints	Superficial and deep palmar arches
Lumbricals 3 and 4	Medial three tendons of flexor digitorum profundus	Lateral sides of extensor expansion of digits 4 and 5	Deep branch of ulnar nerve (C8-T1)	Extends digits at interphalangeal joints and flexes metacarpophalangeal joints	Superficial and deep palmar arches
Dorsal interossei	Adjacent sides of two metacarpal bones	Base of proximal phalanx and extensor expansion of digits 2-4	Deep branch of ulnar nerve (C8-T1)	Abducts digits from axial line of hand-third digit	Deep palmar arch
Palmar interossei	Palmar surfaces of metacarpals 2, 4, and 5	Bases of proximal phalanx and extensor expansion of digits 2, 4, and 5	Deep branch of ulnar nerve (C8-T1)	Adducts digits toward axial line of hand-third digit	Deep palmar arch

FACTS & HINTS

HIGH-YIELD FACTS

Anatomic Points

Arterial Arches of the Hand

- Superficial palmar arch
 - Formed from main terminal branch of ulnar artery
 - Enters hand between hook of hamate and pisiform bone
 - Superficial to flexor retinaculum
 - Divides into superficial palmar arch and deep branch of ulnar artery
 - Gives rise to three common palmar digital arteries
 - Anatomose with palmar metacarpal arteries
 - Gives rise to two proper palmar digital arteries to sides of digits 2 through 4
- Deep palmar arch
 - Formed from terminal branch of radial artery
 - Passes from anatomical snuff box on dorsum of hand
 - Runs between heads of first dorsal interosseus muscle to reach palm
 - Anastomoses with deep branch of ulnar artery
 - Gives off three palmar metacarpal arteries (anastomose with common palmar digital arteries from superficial arch)
 - Gives off princeps pollicis artery to supply palmar surface and lateral sides of thumb

Anatomical Snuff Box

page 233
page 234

- Depression on posterolateral wrist
- Visible when thumb is fully extended
- Bounded anteriorly by tendons of the abductor pollicis longus and extensor pollicis brevis
- Bounded posteriorly by tendon of the extensor pollicis longus
- Structures in floor of snuff box
 - Radial artery
 - Radial styloid process proximally
 - Base of first metacarpal distally
 - Scaphoid and trapezium between radial styloid and first metacarpal

Clinical Points

Colles' Fracture

- Complete transverse fracture within the distal 2 cm of the radius
- Distal fragment displaced dorsally, giving the classic "dinner fork deformity"
- Ulnar styloid may also be avulsed
- Results from forced dorsiflexion of the hand, such as in breaking a fall with an outstretched, pronated hand
- Most common fracture in adults older than 50 years old
- Seen most frequently in elderly women
- Healing usually good as the bone has a rich blood supply

Scaphoid Fracture

- Scaphoid is the most commonly fractured bone of the carpus
- Proximal pole of the bone has a poor blood supply and as a result, fracture may take several months to heal
- This increases risk of avascular necrosis and subsequent degenerative joint disease at the wrist
- Fracture often difficult to spot on initial radiographs, which should be repeated at 2 to 3 weeks in any patient presenting with a severely sprained wrist

Dupuytren's Contracture

- Progressive fibronodular thickening of the palmar fascia
- Leads to fixed flexion deformity of the fingers (most commonly the fourth and fifth digits)
- Condition often bilateral and usually affects middle-aged males of Northern European decent, suggesting hereditary predisposition
- Risk factors include alcohol, liver disease, and antiepileptic medication
- Treatment is surgical

MNEMONICS

Memory Aids

Carpal bones (lateral to medial):	Some Lovers Try Positions That They Can't Handle
-----------------------------------	---

Table I04-3. PROXIMAL ROW

Some	Scaphoid
Lovers	Lunate
Try	Triquetral
Positions	Pisiform

Table I04-4. DISTAL ROW

That	Trapezium ("Trapezium over the thumb")
They	Trapezoid
Can't	Capitate
Handle	Hamate

Note: If you forget if you're starting at the lateral or medial side of each row, remember that the Scaphoid is in the anatomical snuffbox and the trapezium is at the base of the thumb.

Memory Aids

Flexor carpi superficialis and profundus insertions: **Superficialis splits the two, to permit profundus to pass through**

Interossei muscles: Palmar interossei **AD**duct the digits (**PAD**)

Dorsal interossei **AB**duct the digits (**DAB**)

48 Neurovasculature

STUDY AIMS

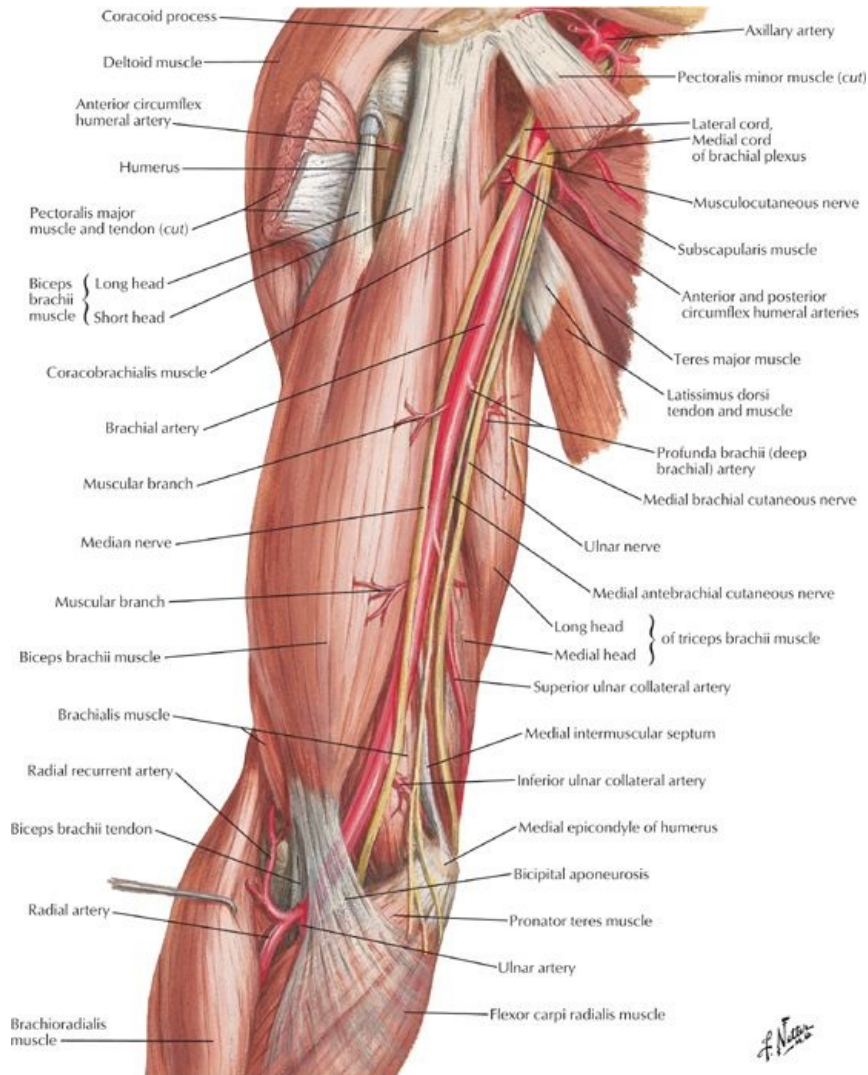
At the end of your study, you should be able to:

- Describe the arterial supply of the arm, forearm, and hand, distinguishing the arteries supplying each of the compartments
- Know the locations of the brachial, radial, and ulnar pulses
- Describe the venous drainage of the hand, forearm, and arm
- Describe the lymphatic drainage of the upper limb
- Understand the organization of the brachial plexus
- Know the innervation to the compartments of the arm and forearm
- Recognize the course of the major nerves of the upper limb
- Understand the dermatome map of the upper limb and its cutaneous innervation

GUIDE

Upper Limb: Neurovasculature

Vascular Supply to the Upper Limb



[Plate 421, Brachial Artery in Situ]

Arterial Supply to the Arm

page 236
page 237

- **Axillary artery**
 - Begins at lateral border of first rib and ends at inferior border of teres major
 - Divided into three descriptive parts by pectoralis minor muscle
 - First part
 - First rib to medial border of pectoralis minor
 - Is enclosed in axillary sheath
 - One branch—superior thoracic artery supplying serratus anterior
 - Second part
 - Posterior to pectoralis minor
 - Two branches
 - Thoracoacromial artery
 - Lateral thoracic artery
 - Both supply the pectoral muscles and breast
 - Third part
 - Lateral border of pectoralis minor to inferior border of teres major
 - Three branches
 - Subscapular artery
 - Largest branch
 - Divides into circumflex scapular and thoracodorsal arteries
 - Supplies serratus anterior, teres major, subscapularis, and latissimus dorsi muscles
 - Anterior and posterior circumflex humeral arteries
- **Brachial artery**

- Continuation of the axillary artery, ends in cubital fossa
- Lies anterior to triceps and brachialis throughout its course
- Accompanied by median nerve, which crosses anterior to artery and lies medially in cubital fossa
- Divides into ulnar and radial arteries under bicipital aponeurosis
- Branches
 - Many muscular branches
 - Profunda brachii artery from medial aspect
 - Superior and inferior ulnar collateral branches
- Profunda brachii (deep artery of the arm)
 - Accompanies radial artery in radial groove
 - Divides into anterior and posterior descending branches to elbow

Arterial Supply to the Forearm

- Ulnar artery
 - Larger of two terminal branches of brachial artery
 - Begins medial to biceps tendon and descends through anterior compartment deep to pronator teres
 - Branches
 - Anterior ulnar recurrent
 - Posterior ulnar recurrent
 - Common interosseus, which branches into
 - Anterior interosseus artery
 - Posterior interosseus artery
 - Muscular branches to muscles of medial side of forearm
 - Branches to the hand
- Radial artery
 - Begins in cubital fossa at neck of radius
 - Passes distally deep to brachioradialis muscle
 - Palpable throughout lateral forearm (best felt at the wrist)
 - Branches
 - Supplies flexor and extensor muscles on lateral side of forearm
 - Radial recurrent artery
 - Branches to the hand

Arterial Supply to the Hand

- Branches from the ulnar artery
 - Palmar carpal branch
 - Runs across anterior wrist deep to tendons of flexor digitorum profundus (FDP)
 - Anastomoses with palmar carpal branch of radial artery to form palmar carpal arch
 - Dorsal carpal branch
 - Arises proximal to pisiform
 - Crosses dorsal to wrist
 - Anastomoses with dorsal carpal branch of radial artery to form dorsal carpal arch
 - Superficial branch of ulnar artery in hand-continues into palm as superficial palmar arch
 - Deep (palmar) branch of ulnar artery in the hand
 - Anastomoses with radial artery
 - Forms deep palmar arch

Venous Drainage of Hand and Forearm

page 237
page 238

- Veins of hand
 - Superficial and deep palmar venous arches
 - Dorsal venous network (arch)
 - Both drain to cephalic and basilic veins
- Superficial veins of forearm
 - Basilic vein ascends posteromedially on forearm
 - Cephalic vein ascends on lateral border of forearm
 - Median cubital vein connects cephalic and basilic over cubital fossa
- Deep veins of forearm
 - Paired radial and ulnar veins and interosseus veins accompany arteries of same name
 - All communicate with superficial veins and median cubital vein

Venous Drainage of Arm

- Superficial veins (drain into axillary vein)
 - Cephalic vein
 - On anterolateral surface
 - Enters groove between deltoid and pectoralis major (deltopectoral groove)
 - Then deltopectoral triangle
 - Empties into termination of axillary vein
 - Basilic vein
 - Medial side, inferior arm
 - Pierces deep fascia at junction of inferior and middle third of arm
 - Runs superiorly to axillary vein

- Deep veins
 - Paired, accompany brachial artery (venae comitantes)
 - Form at elbow from radial and ulnar veins
 - Have valves
 - Merge with basilic vein to form axillary vein

Lymphatics

- All lymph from the arm drains to the axillary nodes
- Lymph from breasts and thorax also drains to the nodes

Nerve Supply to Upper Limb

Brachial Plexus [C5-T1]

page 238

page 239

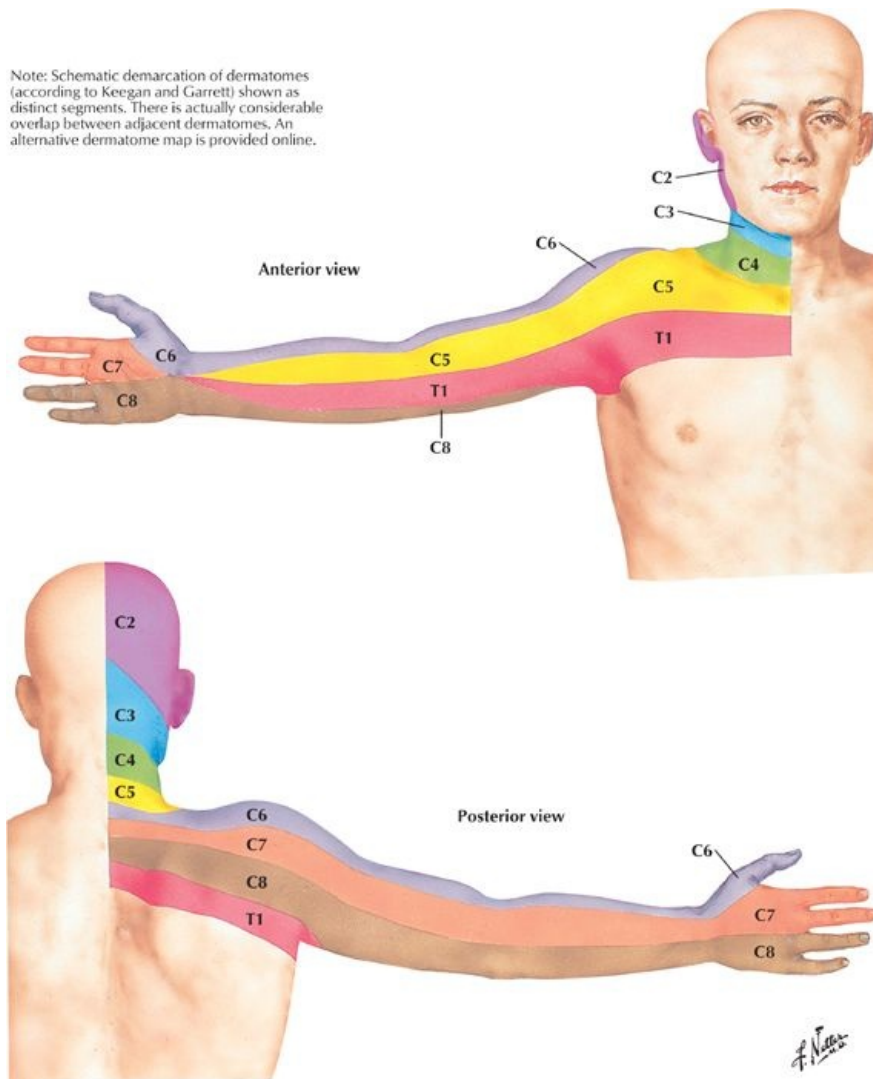
page 239

page 240

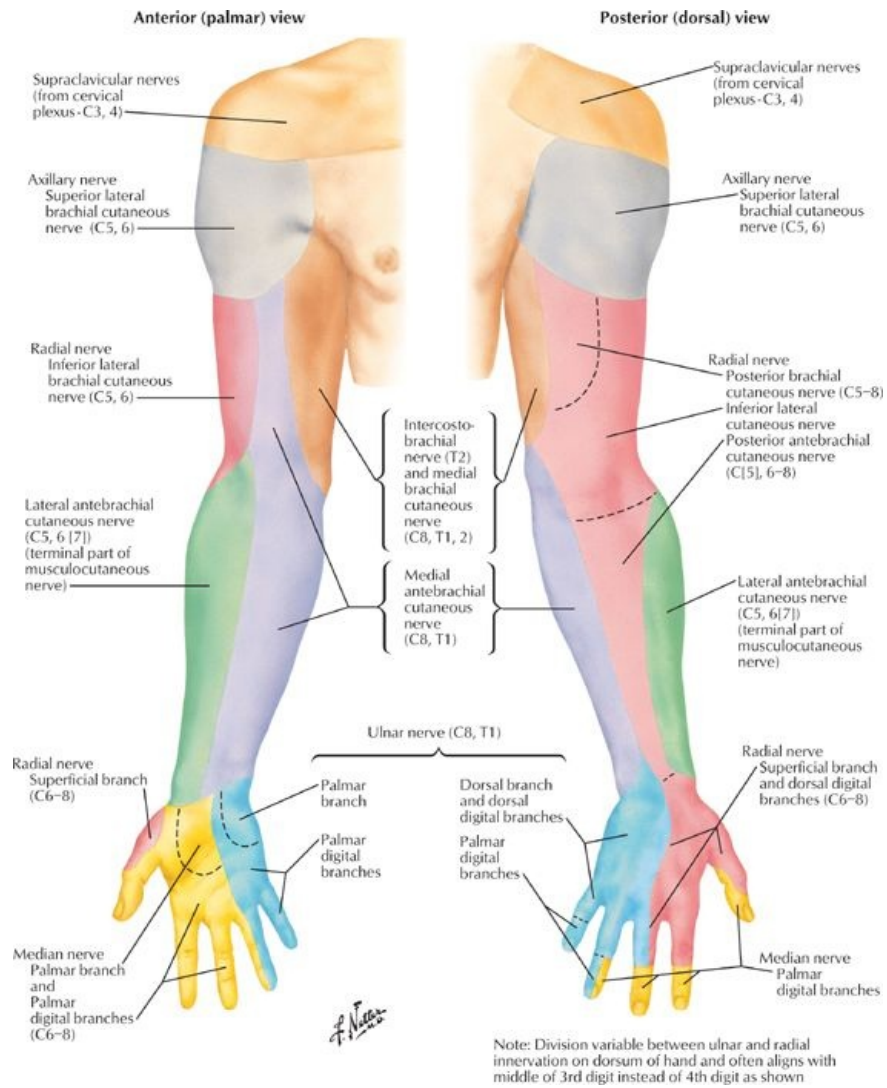
- Composed of
 - Roots (5)
 - Trunks (3)
 - Divisions (6)
 - Cords (3)
 - Branches (13+4 from roots)
- Roots
 - Ventral rami of spinal nerves C5-T1
 - Give rise to
 - Dorsal scapular nerve (C5, possible contribution from C4)
 - Long thoracic nerve (C5-C7) to serratus anterior muscle
- Trunks
 - Superior from ventral rami of C5 and 6
 - Branches
 - a. Nerve to subclavius muscle
 - b. Suprascapular nerve to supra- and infraspinatus, shoulder joint
 - Middle from ventral ramus of C7
 - Inferior from ventral rami of C8 and T1
- Divisions
 - Anterior divisions of superior and middle trunks form lateral cord
 - Anterior division of inferior trunk continues as medial cord
 - Posterior divisions of all three trunks form posterior cord
- Cords
 - Named by relationship to axillary artery, which they surround
 - Lateral
 - Medial
 - Posterior
- Branches
 - Branches from lateral cord
 - Lateral pectoral nerve (C5-C7) to pectoralis major and minor muscles
 - Musculocutaneous (C5-C7)
 - Lateral root of median nerve (C6-C7)
 - Branches from medial cord
 - Medial pectoral nerve (C8-T1) to pectoralis minor and major
 - Ulnar nerve (C8-T1)
 - Medial brachial cutaneous nerve (C8-T1) supplies skin over medial surface of arm and proximal surface of forearm
 - Medial antebrachial cutaneous nerve (C8-T1) to skin over medial forearm
 - Median root of median nerve (C8-T1)
 - Branches from the posterior cord
 - Upper subscapular nerve (C5-C6) to subscapularis
 - Lower subscapular nerve (C5-C6) to teres major and subscapularis
 - Thoracodorsal nerve (C6-C8) to latissimus dorsi
 - Axillary nerve (C5-C6) to teres minor and deltoid (ends as the upper lateral brachial cutaneous nerve)
 - Radial nerve (C5-T1) supplies all extensors of the upper limb and sensation to skin overlying extensor region, including hand
- Other facts
 - Anterior divisions supply the flexor parts of the upper limb
 - Posterior divisions supply the extensor parts of the upper limb
 - Each cord divides into two main terminal branches
 - Posterior→axillary and radial
 - Lateral→musculocutaneous and median
 - Medial→Median and ulnar
 - Supraclavicular part of plexus
 - Arises from roots and trunks
 - Approachable through posterior triangle of the neck
 - Dorsal scapular nerve
 - Nerve to subclavius
 - Suprascapular nerve
 - Long thoracic nerve
 - Infraclavicular part (cords and their branches) is in the axilla
 - Arise from cords

- Approachable through axilla
 - All the rest of the nerve branches from brachial plexus
- Ulnar nerve supplies
 - Flexor carpi ulnaris
 - Medial half of FDP
 - Hypothenar muscles
 - Third and fourth lumbricals
 - All interossei muscles
 - Skin over the medial hand and 1½ digits
- Median nerve supplies
 - Forearm flexors (except flexor carpi ulnaris and the lateral half of flexor digitorum profundus)
 - Thenar muscles and first and second lumbricals
 - Skin over the lateral hand and 3½ digits
- Musculocutaneous nerve supplies
 - Flexor muscles of arm (anterior compartment)
 - Skin over lateral aspect of forearm (lateral antebrachial cutaneous)
- Radial nerve supplies
 - Triceps
 - Anconeus
 - Extensor muscles of forearm
 - Skin over posterior arm and forearm
- Axillary nerve supplies
 - Teres minor
 - Deltoid
 - Shoulder joint
 - Skin over inferior deltoid

Dermatomes and Cutaneous Innervation of the Upper Limb



[Plate 401, Dermatomes of Upper Limb]



[Plate 402, Cutaneous Innervation of Upper Limb]

- Dermatomes
 - Band-like areas of skin
 - Each supplied by a single spinal nerve through dorsal and ventral rami
 - Arranged in segmental fashion
- Cutaneous innervation of the upper limb
 - Follows segmental arrangement of spinal nerve contributions to the brachial plexus
 - No representation of C7 on anterior aspect of arm and forearm
 - No representation of T1 on palmar or dorsal surface of hand

FACTS & HINTS

HIGH-YIELD FACTS

Clinical Points

page 240
page 241

Brachial Plexus Injury

- Disease, trauma or excessive stretching (because of birth trauma) of the posterior triangle of the neck or axilla may damage brachial plexus
- Results in paralysis and anaesthesia in the distribution of the affected nerves
- Various terms used to describe the different lesions
- *Erb's palsy* affects areas supplied by nerves from superior part of the plexus
- *Klumpke's palsy* affects areas supplied by nerves from the inferior part

Carpal Tunnel Syndrome

- A result of compression of the median nerve as it passes under flexor retinaculum
- Compression caused by any process that significantly reduces the size of the carpal tunnel: inflammation of the synovial sheaths, fluid retention, and infection
- Pain or paraesthesia felt in the lateral 3½ digits, may radiate toward the elbow and is often worse at night
- Also loss of sensation and diminished control of the median nerve-innervated muscles
- Surgical division of the flexor retinaculum may be necessary to relieve symptoms

Ulnar Nerve Injury

- Ulnar nerve may be compressed as it passes behind medial epicondyle of the humerus or through the Guyon canal at the wrist
- Pain and/or paraesthesia felt at medial aspect of the elbow radiating to the medial forearm and medial 1½ digits
- Also may be weakness of the intrinsic muscles of the hand

Radial Nerve Injury

- Palsy of the radial nerve common after prolonged pressure on the back of the arm by resting it against a hard surface (such as back of movie theater seat-the "*Saturday night palsy*")
- Nerve may also be injured in fractures of humerus as it winds along spiral groove
- Extensors of the wrist are paralyzed, resulting in a wrist drop
- Triceps not affected unless the nerve is injured proximally in the axilla

MNEMONICS

Memory Aids

Parts of the brachial plexus:	Really Thirsty? Drink Cold Beer
	R oots, T runks, D ivisions, C ords, B ranches
Terminal nerves of plexus:	MARMU
	M usculocutaneous, A xillary, R adial, M edian, U lnar
Muscles supplied by median nerve supply in hand:	LOAF
	L umbricals (lateral), O pponens pollicis, A bductor pollicis brevis, F lexor pollicis brevis

Memory Aids

Branches of brachial plexus medial cord:	Money Makes Many Men Unhappy
	M edial pectoral nerve
	M edial branch of median nerve
	M edial cutaneous nerve of arm
	M edial cutaneous nerve of forearm
	U lnar nerve

49 Topographic Anatomy

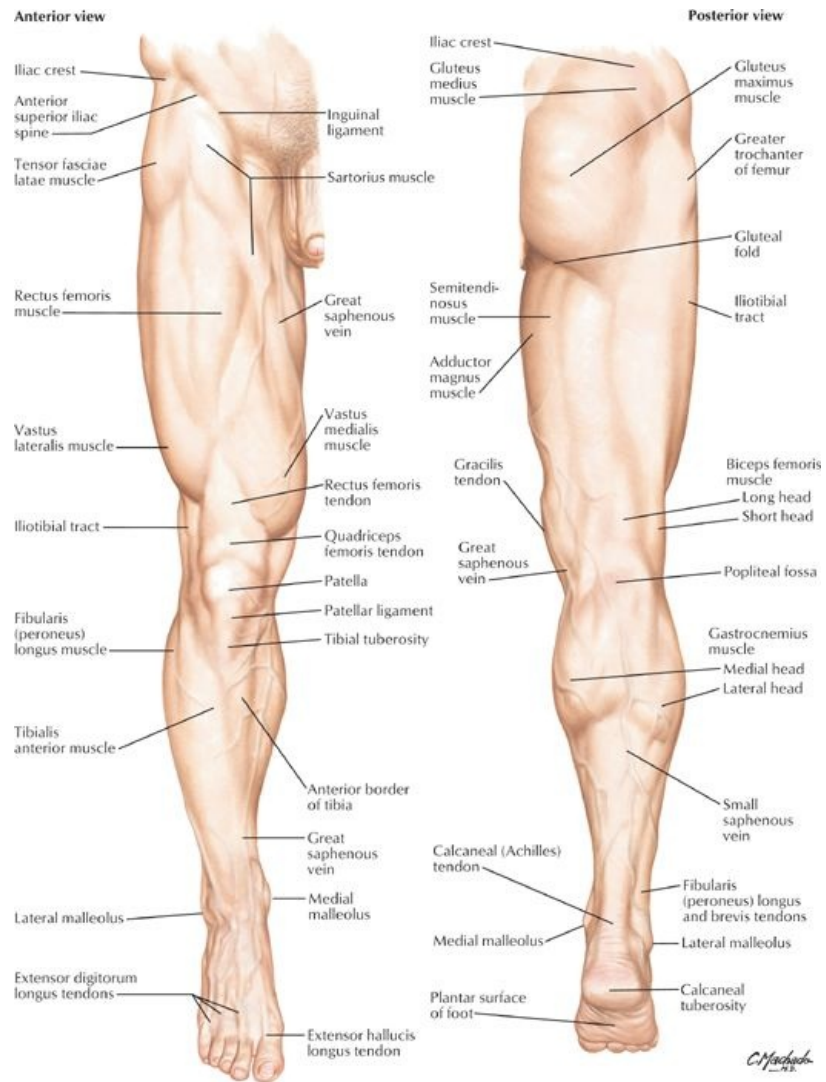
STUDY AIMS

At the end of your study, you should be able to:

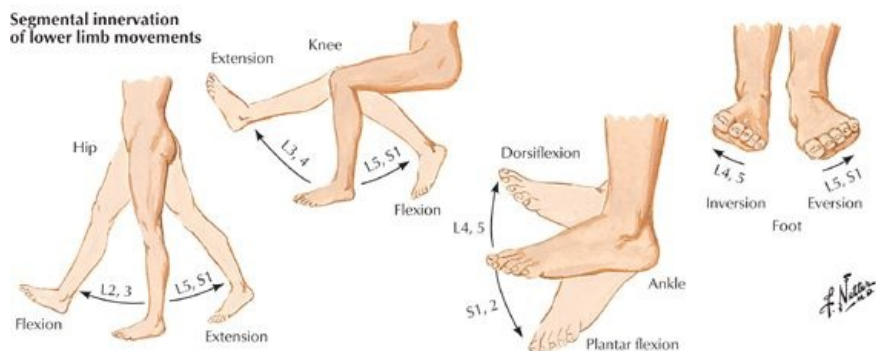
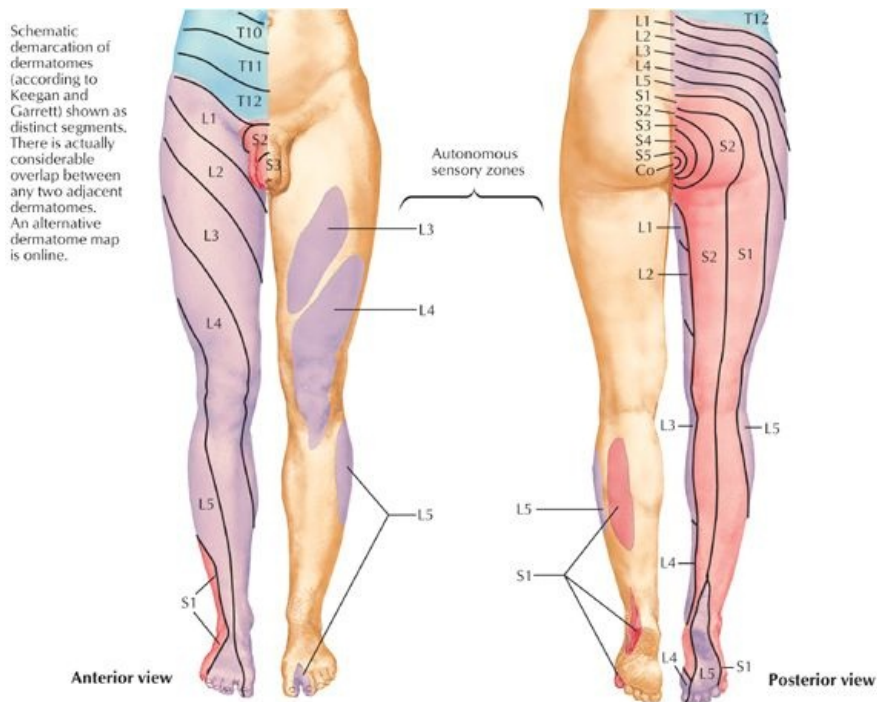
- Identify the bony landmarks of the lower limb
- Identify the main muscle masses and palpable tendons of the lower limb
- Identify the course of the great saphenous vein
- Identify the inguinal ligament and know its attachments
- Identify the popliteal fossa

GUIDE

Lower Limb: Topographic Anatomy



[Plate 469, Lower Limb]



[Plate 470, Dermatomes of Lower Limb]

Bony Landmarks

- Greater trochanter of femur
 - Posterior edge palpable on lateral side of thigh
 - 10 cm below iliac crest
 - Site of attachment of several gluteal muscles
- Lateral and medial femoral condyles palpable on lateral and medial aspects of knee
- Patella (kneecap)
 - Sesamoid bone
 - Within tendon of the quadriceps femoris
 - Tendon continues as patellar ligament inferiorly
 - Lateral and medial margins palpable when knee is flexed
- Tibial condyles-medial and lateral rounded projections at its proximal end
- Tibial tuberosity
 - Elevation on anterior surface of tibia
 - Located between the two condyles
- Anterior border of tibia
 - Sharp and subcutaneous
 - Can be palpated from tibial tuberosity to medial malleolus
- Head of fibula
 - Subcutaneous
 - Can be palpated on posterolateral knee at level of tibial tuberosity
- Medial malleolus-medial projection of the tibia at its distal end
- Lateral malleolus-expanded distal end of the fibula
- Tuberosity of the fifth metatarsal
 - Bony protuberance halfway along the lateral side of the foot
 - Site of attachment for fibularis brevis muscle

Muscles and Tendons

- Quadriceps femoris-muscle mass of anterior thigh (see Section 7-2: Lower Limb: Hip and Thigh)
- Gastrocnemius muscle-muscle mass of posterior leg (see Section 7-4: Lower Limb: Leg)
- Hamstring muscles
 - Palpable as a mass arising from the ischial tuberosity
 - Palpable as the medial and lateral superior borders of the popliteal fossa
- Calcaneal tendon (Achilles' tendon)
 - Tendon of gastrocnemius
 - Descends to calcaneus (heel) on posteroinferior leg, between medial and lateral malleoli
- Tendon of fibularis brevis-palpable at its attachment of the base of the fifth metatarsal
- Tendons of extensor hallucis longus and extensor digitorum longus-visible when toes are forcibly extended

Vessels



VIDEO TIP

For something as specific as the great saphenous vein, use Search to locate the structure. Use the Search Transparency feature to make all but the structure transmitted transparent: Video Tip 7.1 - saphenous

- Great saphenous vein (see Section 7-6: Lower Limb: Neurovasculature)
 - Descends along the medial thigh and leg, passing posterior to the knee
 - Is visible with its tributaries when dilated and varicose (because of incompetence of valves of vein to prevent backflow of blood)

Other Palpable Landmarks

- Inguinal ligament
 - Runs inferomedially from ASIS to pubic tubercle of pelvis
 - Folded inferior edge of external abdominal aponeurosis
 - Fold separates abdominal region from thigh
- Popliteal fossa (see Section 7-3: Lower Limb: Knee)
 - Diamond-shaped depression posterior to knee
 - Contains arteries, veins, and nerves of the leg

FACTS & HINTS

HIGH-YIELD FACTS

Anatomic Points

Functional Overview of the Lower Limb

The lower limb supports the bodyweight and permits locomotion. It is firmly attached through the rigid pelvis to the vertebral column. The joints are relatively stable and influenced by the line of gravity; this line passes posterior to the hip joint, anterior to the knee, and anterior to the ankle. Thus only the calf muscles need to contract to maintain an upright posture. Clinically the limb is divided into four compartments: gluteal, thigh, leg and foot.

page 243

page 244

Lower Limb Development

The general plan of the lower limb is similar to the upper limb; however, during development the lower limb undergoes medial rotation, bringing the extensors of the knee, ankle and toes anteriorly with the knee pointing forwards. The hip is unaffected, so hip flexors remain anterior and the extensors posterior.

Clinical Points

Varicose Veins

- Dilated superficial veins most commonly seen in the posteromedial parts of the lower limb
- Result from absent or faulty valves in the communicating veins between the deep and superficial venous systems of the limb
- Secondary failure of the saphenofemoral valve may occur
- Stagnation of blood in these vessels predisposes to thrombosis and subsequent inflammation = thrombophlebitis

50 Hip and Thigh

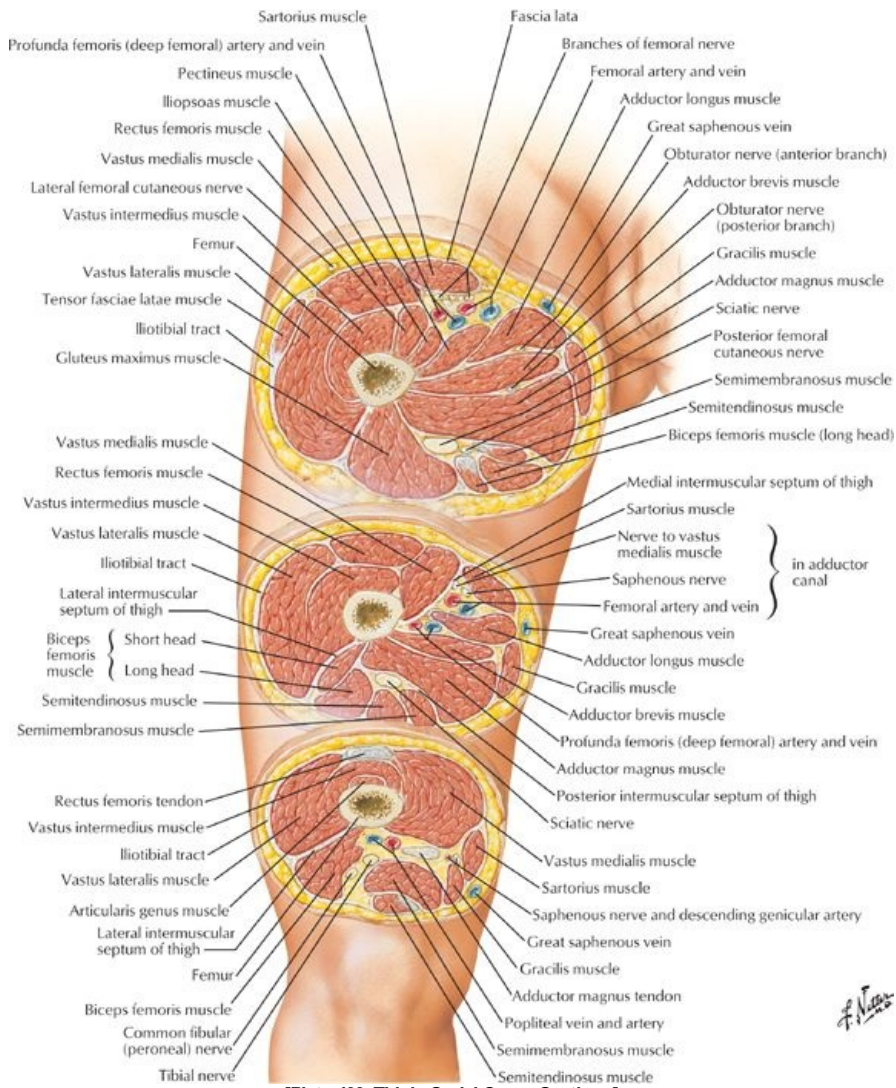
STUDY AIMS

At the end of your study, you should be able to:

- Describe the structure of the hip joint and its movements
- Identify the different parts and surface markings of the femur
- Know the origins, insertions and actions of the major muscles of the gluteal region
- Know the origins, insertions and actions of the major muscles of the anterior, medial, and posterior thigh
- Identify the margins of the femoral triangle and describe its contents
- Describe the course of the adductor canal

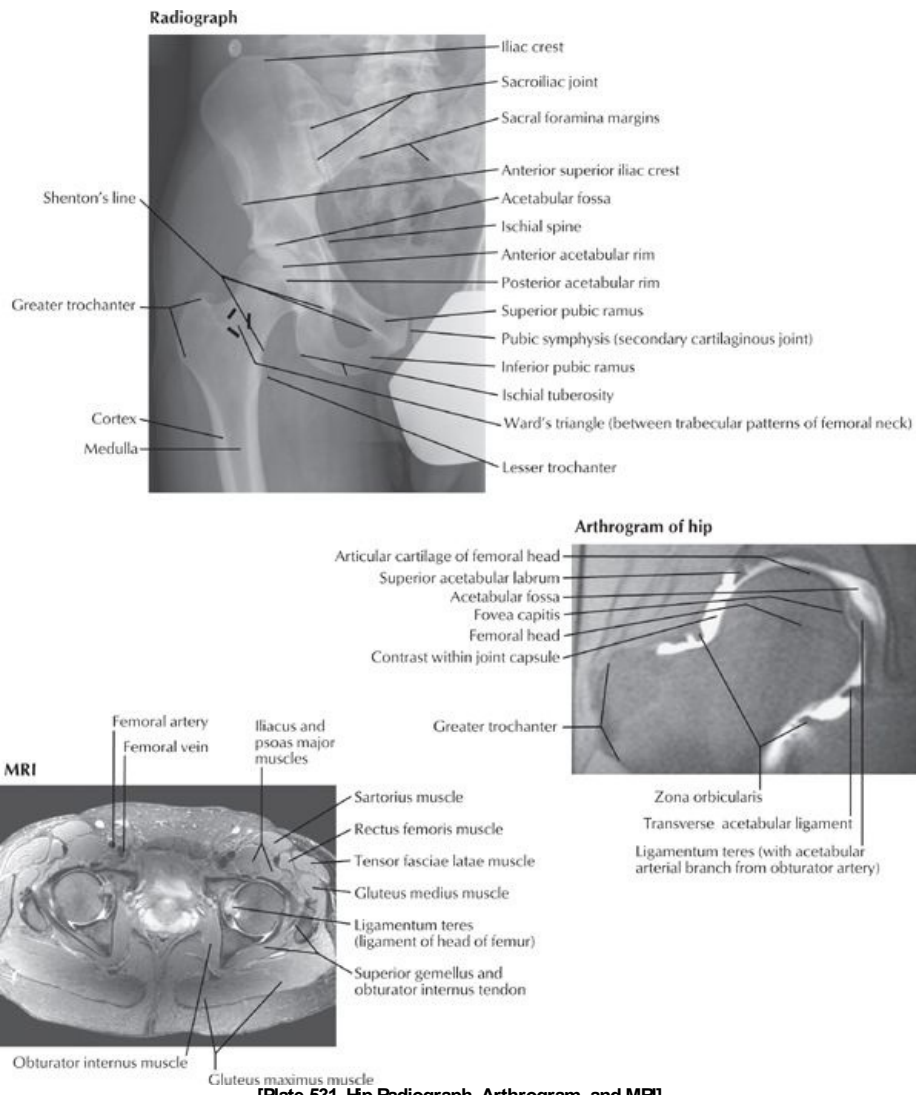
GUIDE

Lower Limb: Hip and Thigh



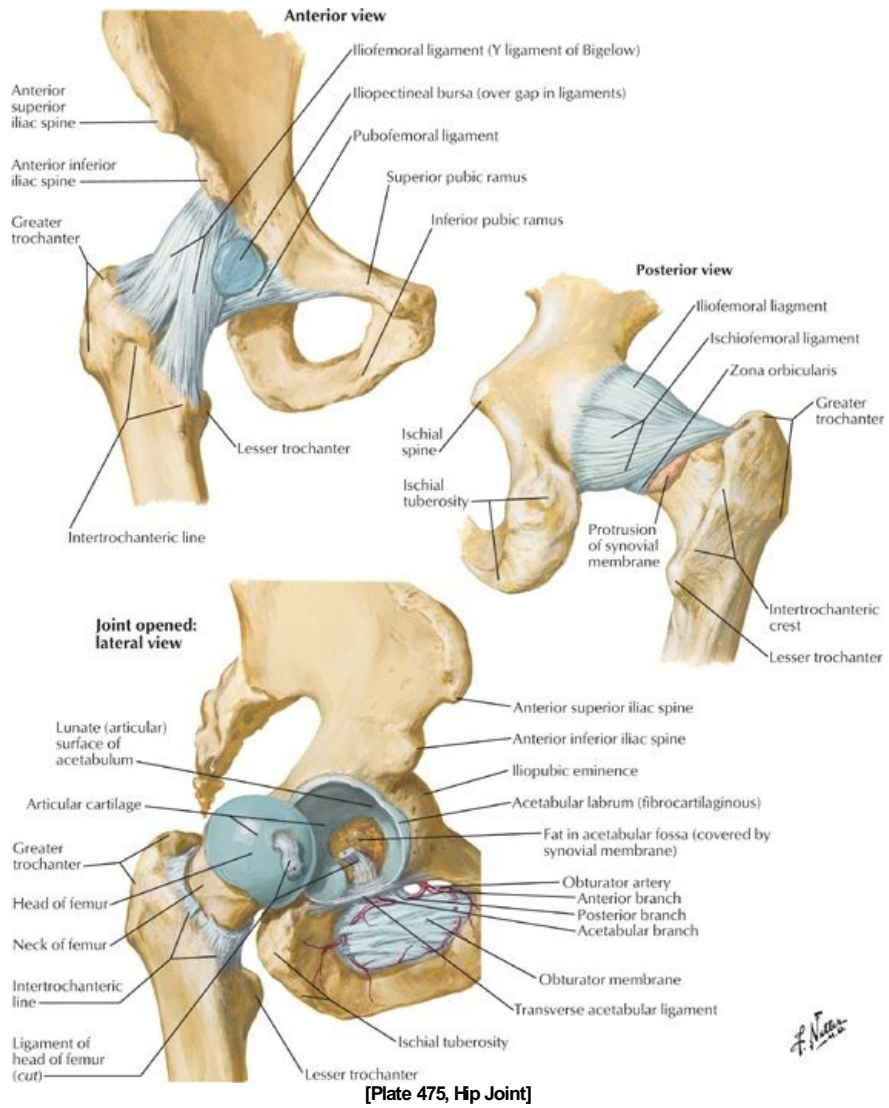
[Plate 493, Thigh: Serial Cross Sections]

Handwritten signature



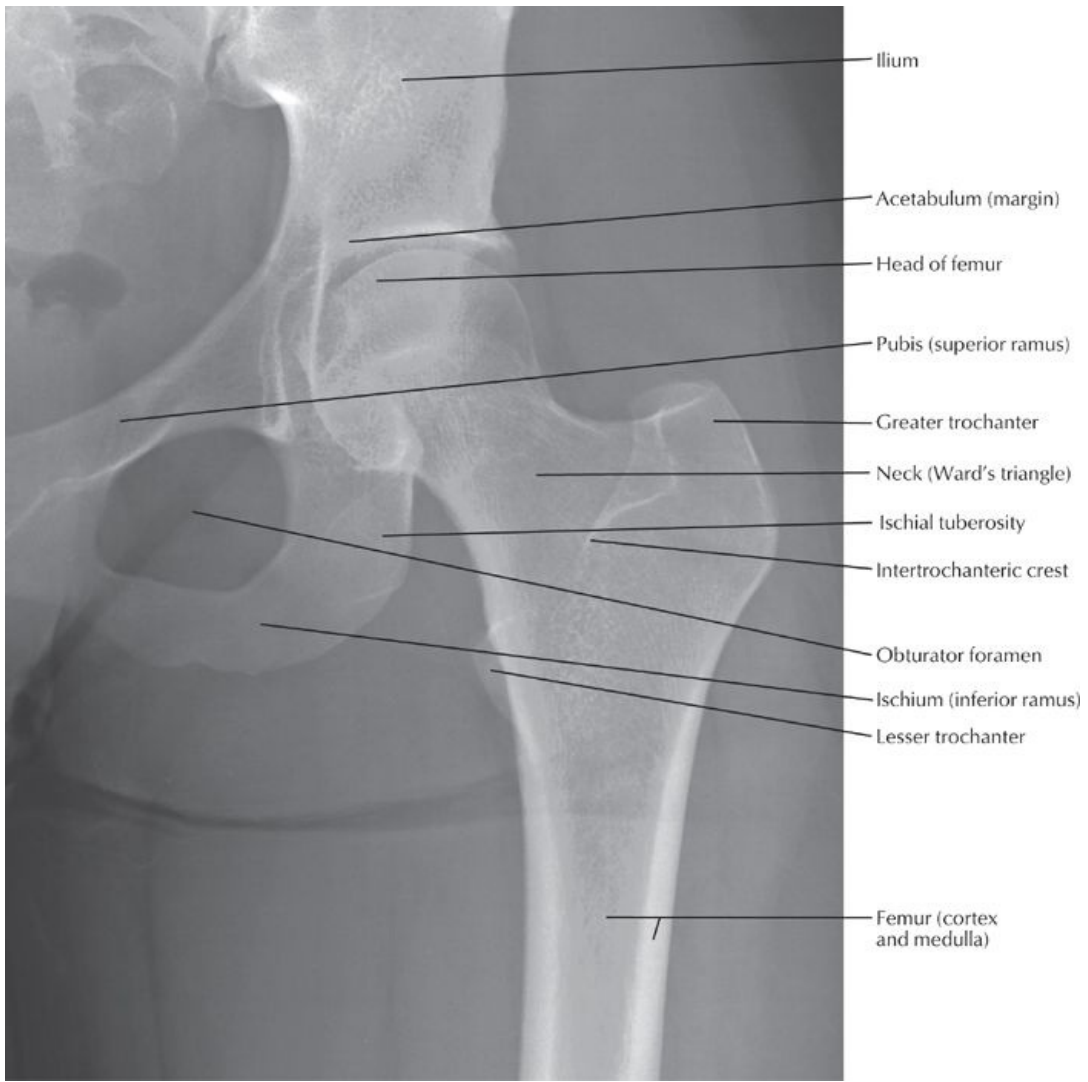[Plate 531, Hip Radiograph, Arthrogram, and MRI]

Hip Joint

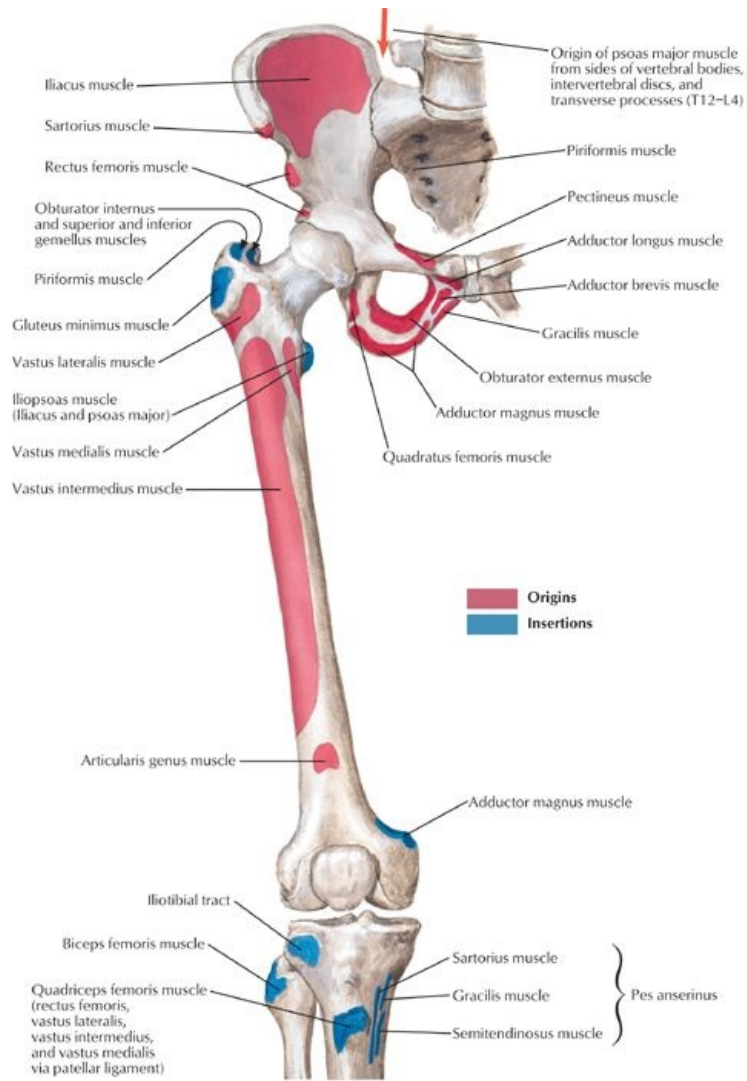


[Plate 475, Hip Joint]

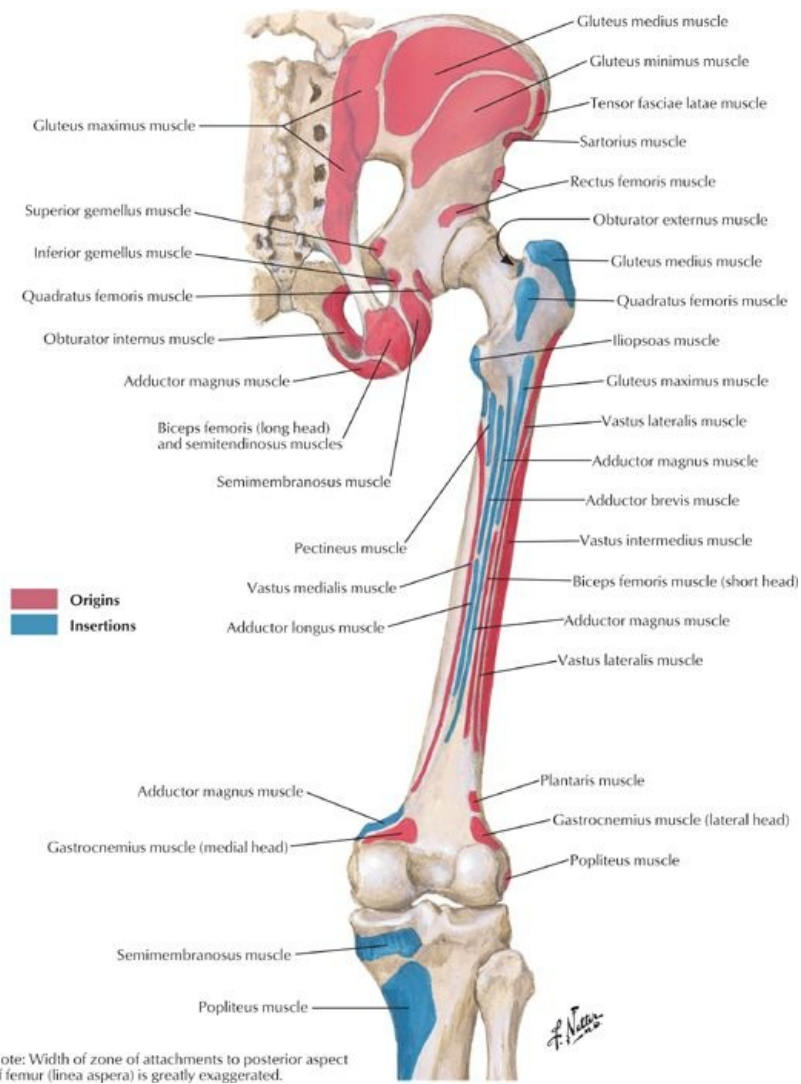
F. Netter



[Plate 476, Hip Joint: Anteroposterior Radiograph]



[Plate 478, Bony Attachments of Muscles of Hip and Thigh: Anterior View]



[Plate 479, Bony Attachments of Muscles of Hip and Thigh: Posterior View]

page 245
page 246

- Multiaxial, ball-and-socket synovial joint
- Movements
 - Flexion 140 degrees
 - Extension 10 degrees
 - Abduction 45 degrees
 - Adduction 30 degrees
 - Internal rotation 40 degrees
 - External rotation 50 degrees
- Acetabulum (see Section 5-2: Pelvis and Perineum: Bones and Ligaments)
 - Head of femur fits within
 - Composed of contributions from ilium, ischium, pubis
 - Deepened by incomplete ring of fibrocartilaginous labrum, which is attached to bony rim
 - Ring completed by transverse acetabular ligament, which spans acetabular notch
- Head of femur
 - Has a ligamentum teres (ligament of the head of the femur)
 - Attaches fovea (pit) in head of femur to transverse acetabular ligament
 - Contains branch from obturator artery
- Capsule
 - Strong, fibrous and loose
 - Attaches to acetabular labrum, transverse acetabular ligament, intertrochanteric line of femur
 - Lower third of neck of femur is extracapsular.
 - Strengthened by ligaments
 - Iliofemoral (Y-shaped)
 - Pubofemoral
 - Ischiofemoral ligaments
- Blood supply (see Section 7-6: Lower Limb: Neurovasculature)
 - Medial and lateral circumflex arteries from deep branch of femoral or femoral artery
 - Artery of head of femur (minor contribution)
- Nerve supply
 - Femoral nerve

- Nerve to quadratus femoris (posteriorly)
- Articular branch of sciatic nerve
- Anterior division of the obturator nerve (inferiorly)
- Superior gluteal nerve (posteriorly)

Femur

- Longest and heaviest bone in the body
 - Osteological features
 - Head with fovea (pit)
 - Neck-between head and shaft
 - Greater trochanter-large, lateral, posterosuperior projection from junction of neck and body
 - Lesser trochanter-rounded medial projection from junction of neck and body
 - Intertrochanteric line
 - Ridge running between greater and lesser trochanters
 - Indicates where neck joins body
 - Body (shaft)
 - Smooth and cylindrical
 - Wide, roughened line posteriorly: linea aspera
Runs vertically
Has medial and lateral lips (margins)
 - Medial and lateral condyles-medial and lateral rounded projections at its distal end
 - Medial and lateral epicondyles-central projection from each condyle
 - Neck is angled at 115 to 140 degrees (average 126 degrees) relative to the long axis of the shaft

Ligaments of the Hip Joint

Ligament	Attachments	Function
Iliofemoral	ASIS and acetabulum → intertrochanteric line. (Strong; Y-shaped ligament)	Prevents hyperextension
Ischiofemoral	Acetabular rim → circles superiorly and laterally to medial base of greater trochanter	Prevents hyperextension Screws femoral head into acetabulum
Pubofemoral	Pubic ramus → laterally and inferiorly to joint capsule	Tightens during extension and abduction Limits abduction
Transverse acetabular	Joins the inferior ends of the labrum, crosses acetabular notch	Completes the acetabular ring
Ligament of head of femur	Acetabular notch → fovea of femur (Intracapsular but extrasynovial)	Contains artery to head of femur (minute in adults)

page 246
page 247

Fascial Compartments of the Thigh

- Superficial fascia
 - Contains variable amounts of fat
 - Cutaneous nerves, such as the saphenous and sural
 - Superficial veins, such as the great and small saphenous
 - Lymphatics
- Deep fascia = fascia lata
 - Separates the subcutaneous tissue from the muscles
 - Dense strong layer
 - Prevents bulging of muscles during contraction, which improves efficiency of pumping blood through veins back to the heart
 - Attaches to the inguinal ligament, iliac crests, and sacrum superiorly, and is continuous with the crural fascia inferiorly (see Section 7-4: Lower Limb: Leg)
- Fascial septa from the fascia lata divide the thigh into three compartments: anterior, medial, and posterior
- Iliotibial tract
 - Lateral thickening of fascia lata
 - Conjoint aponeurosis of tensor fasciae lata and gluteus maximus muscles
 - Attaches to tubercle on lateral condyle of the tibia (Gerdy tubercle)
- Saphenous opening in fascia lata
 - Deficiency inferior to medial inguinal ligament
 - Spanned by cribriform fascia
 - Saphenous vein and efferent lymphatic vessels form superficial inguinal nodes pass through opening and cribriform fascia

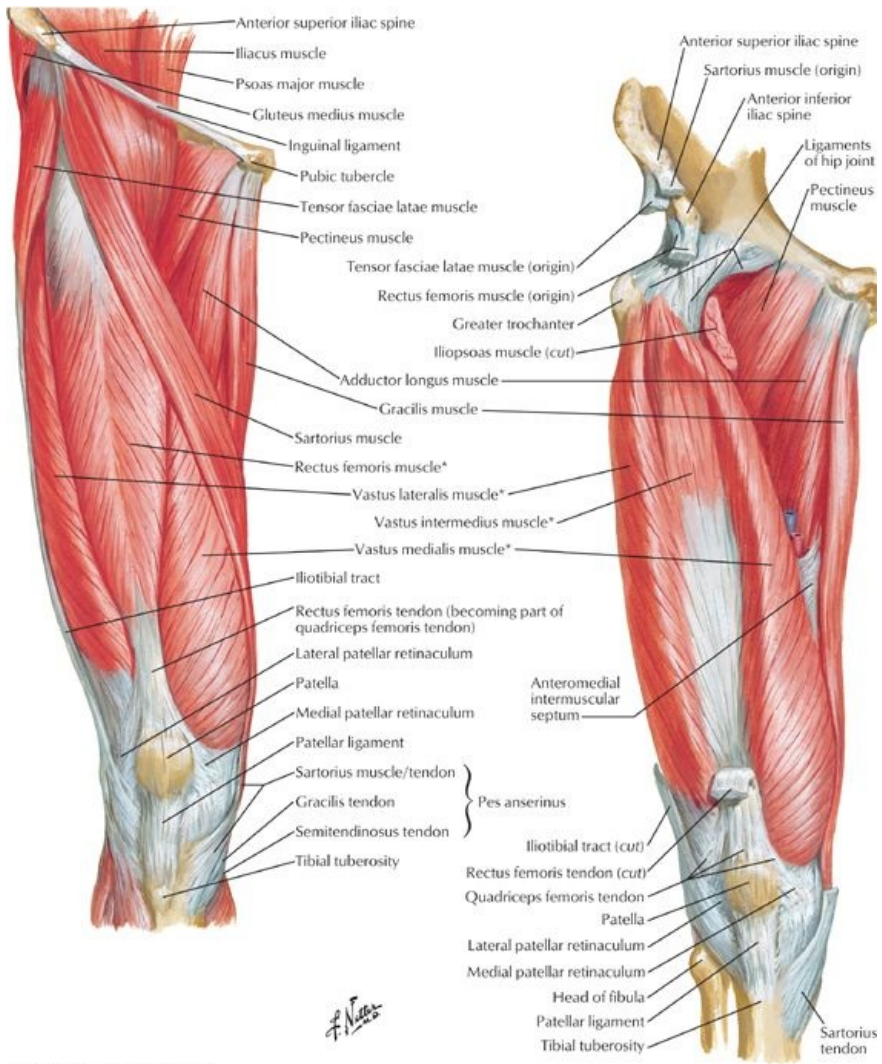
Muscles of the Gluteal Region

- Extensor of hip: gluteus maximus
 - Also laterally rotates hip
 - Through iliotibial tract, extends knee
- Abductors of hip
 - Gluteus medius
 - Gluteus minimus
 - Most important function of these muscles: contract to prevent sagging of unsupported side of hip during locomotion, enabling opposite foot to swing through (e.g., Trendelenburg test)
- Lateral rotators of hip
 - Gluteus maximus

- Piriformis
- Obturator internus
- Obturator externus
- Gemelli (superior and inferior)
- Quadratus femoris
- Extensors of knee
 - Gluteus maximus
 - Tensor fasciae latae

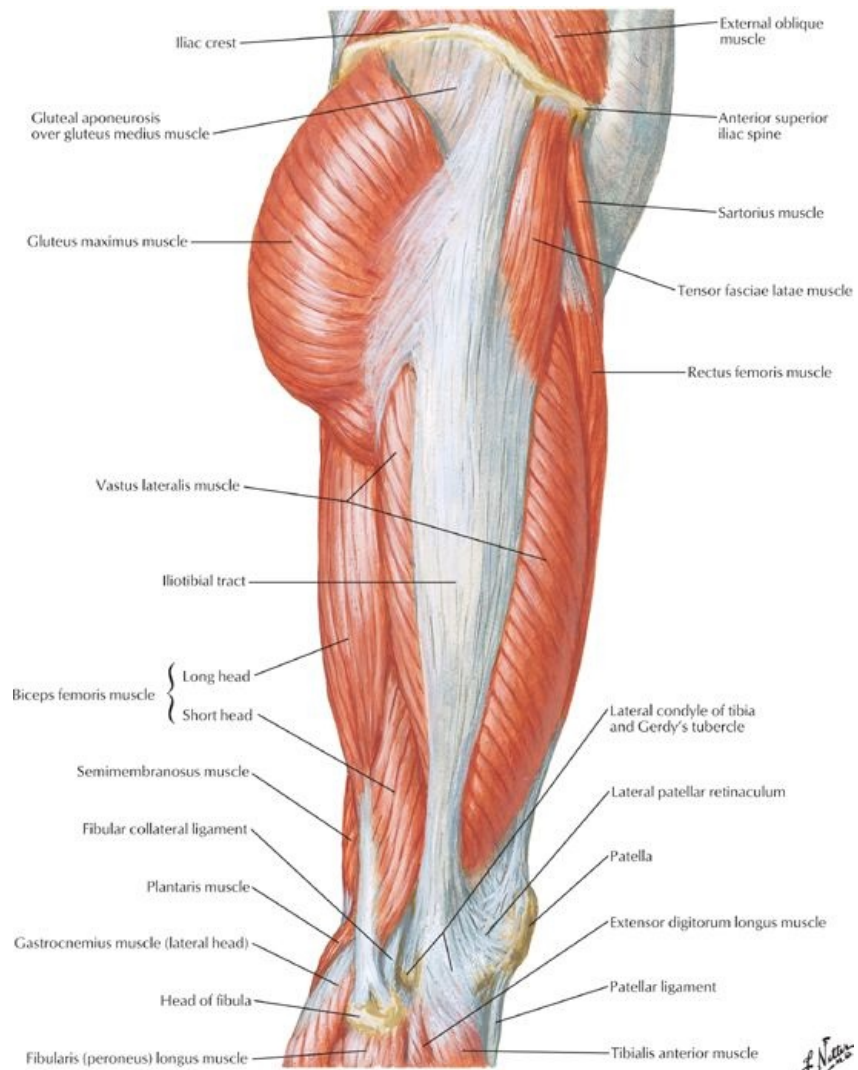
Muscle	Origin	Insertion	Innervation	Blood Supply	Action
Gluteus maximus	Ilium posterior to posterior gluteal line dorsal surface of sacrum and coccyx, sacrotuberous ligament	Most fibers end in Iliotibial tract that inserts into lateral condyle of tibia; some fibers insert gluteal tuberosity of femur	Inferior gluteal nerve (L5 - S2)	Superior and inferior gluteal arteries, first perforating branch of deep femoral artery	Extends thigh, assists lateral rotation
Gluteus medius	Lateral surface of ilium between anterior and posterior gluteal lines	Lateral surface of greater trochanter of femur	Superior gluteal nerve (L4 - S1)	Deep branch of superior gluteal artery	Abducts thigh, rotates thigh medially
Gluteus minimus	Lateral surface of ilium between anterior and inferior gluteal lines	Anterior border of greater trochanter of femur	Superior gluteal nerve (L4 - S1)	Deep branch of superior gluteal artery	Abducts thigh, rotates thigh medially
Piriformis	Anterior surface of sacrum and sacrotuberous ligament	Superior border of greater trochanter of femur	Ventral rami of S1 and S2	Superior and inferior gluteal arteries, internal pudendal artery	Laterally rotates thigh, abducts flexed thigh
Obturator internus	Pelvic surface of obturator membrane and margins of obturator foramen	Medial surface of greater trochanter of femur	Nerve to obturator internus (L5-S2)	Internal pudendal and superior gluteal arteries	Laterally rotates thigh, abducts flexed thigh
Gemellus superior	Outer surface of ischial spine	Medial surface of greater trochanter of femur	Nerve to obturator internus (L5-S2)	Inferior gluteal artery	Laterally rotates thigh
Gemellus inferior	Upper margin of ischial tuberosity	Medial surface of greater trochanter of femur	Nerve to quadratus femoris (L4-S1)	Inferior gluteal artery	Laterally rotates thigh
Quadratus femoris	Lateral margin of ischial tuberosity	Quadrate tubercle on intertrochanteric crest of femur	Nerve to quadratus femoris (L4-S1)	Medial circumflex femoral artery	Laterally rotates thigh

Muscles of the Thigh



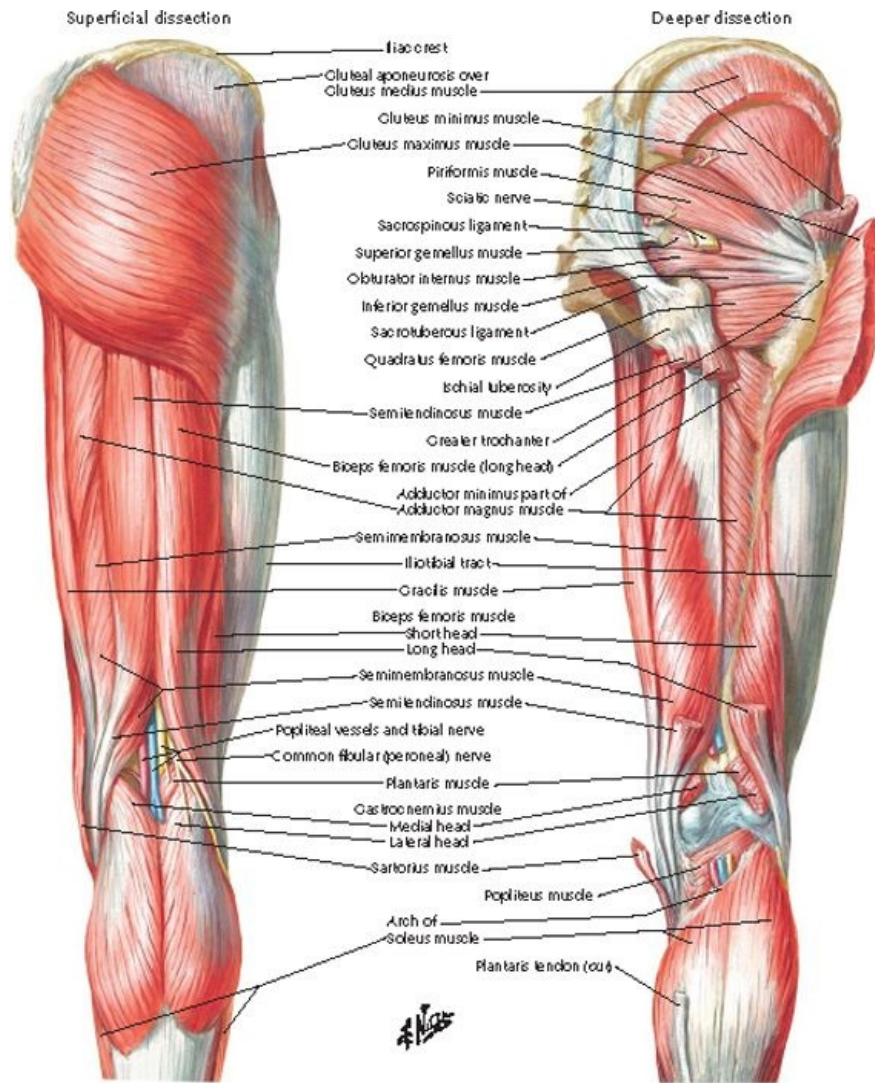
*Muscles of quadriceps femoris

[Plate 480, Muscles of Thigh: Anterior Views]



[Plate 482, Muscles of Hip and Thigh: Lateral View]

f. Nasser



[Plate 483, Muscles of Thigh: Posterior Views]

- Anterior (= extensor) compartment
 - Flexors of hip
 - Sartorius (also abducts and laterally rotates hip and flexes and medially rotates knee), Iliopsoas
 - Pectineus (also adducts hip)
 - Extensor of knee: quadriceps femoris, composed of
 - Rectus femoris (also flexes hip)
 - Vastus lateralis
 - Vastus intermedius
 - Vastus medialis (also stabilizes patella)

page 248
page 249

Anterior Thigh Muscles

Muscle	Origin	Insertion	Innervation	Blood Supply	Action
Iliopsoas/psoas major	Sides of vertebra T12 to L5 and transverse processes of L1-L5	Lesser trochanter of femur	Ventral rami of lumbar spinal nerves 1-3	Lumbar branches of iliolumbar artery	Flexes thigh at hip and stabilizes the hip
Iliacus	Iliac crest, iliac fossa, ala of scrum, and anterior sacroiliac ligaments	Tendon of psoas major and body of femur, inferior to lesser trochanter	Femoral nerve (L2-L3)	Iliac branches of iliolumbar artery	Flexes thigh at hip and stabilizes the hip
Tensor fasciae latae	Anterior superior iliac spine and anterior part of external lip of iliac crest	Iliotibial tract → lateral condyle of tibia	Superior gluteal nerve (L4-L5)	Superior gluteal arteries, lateral circumflex femoral artery	Abducts, medially rotates and flexes the thigh, stabilizes trunk on thigh
Sartorius	ASIS and superior part of notch below it	Superior part of medial surface of tibia	Femoral nerve (L2-L3)	Femoral artery	Abducts, laterally rotates and flexes the thigh
Quadratus femoris	Lateral margin of ischial tuberosity	Quadratus tubercle on intertrochanteric crest	Nerve to quadratus femoris	Medial circumflex femoral artery	Laterally rotates thigh

		of femur	(L4 to S1)		
Rectus femoris	Anterior inferior iliac spine and groove superior to acetabulum	Base of patella and to tibial tuberosity via patellar ligament	Femoral nerve (L2-L4)	Lateral circumflex femoral artery, deep femoral artery	Extends the leg at the knee joint and flexes the thigh at the hip joint
Vastus lateralis	Greater trochanter and lateral lip of linea aspera of femur	Base of patella and to tibial tuberosity via patellar ligament	Femoral nerve (L2-L4)	Lateral circumflex femoral artery, deep femoral artery	Extends the leg at the knee joint
Vastus medialis	Intertrochanteric line and medial lip of linea aspera of femur	Base of patella and to tibial tuberosity via patellar ligament	Femoral nerve (L2-L4)	Femoral artery, deep femoral artery	Extends the leg at the knee joint
Vastus intermedius	Anterior and lateral surfaces of body of femur	Base of patella and to tibial tuberosity via patellar ligament	Femoral nerve (L2-L4)	Lateral circumflex femoral artery, deep femoral artery	Extends the leg at the knee joint
Pectineus	Pecten pubis	Pectineal line of femur	Femoral nerve (L2-L3) and sometimes obturator nerve	Medial circumflex femoral artery, obturator artery	Adducts and flexes thigh

page 249
page 250

- Medial (= adductor) compartment
 - Adductors of hip
 - Adductors longus
 - Adductor brevis
 - Adductor magnus (also assist lateral rotation of knee)
 - Gracilis (also flexes knee)
 - Obturator externus-laterally rotates hip

Medial Thigh Muscles

Muscle	Origin	Insertion	Innervation	Blood Supply	Action
Adductor longus	Body of pubis, inferior to pubic crest	Middle third of linea aspera of femur	Obturator nerve (anterior division) (L2-L4)	Medial circumflex femoral artery, obturator artery	Adducts thigh
Adductor brevis	Body and inferior pubic ramus	Pectineal line and proximal part of linea aspera of femur	Obturator nerve (L2-L4)	Medial circumflex femoral artery, obturator artery	Adducts and flexes thigh
Adductor magnus	Inferior pubis ramus, ramus of ischium Hamstring part: ischial tuberosity	Gluteal tuberosity, linea aspera, supracondylar line Hamstring part: adductor tubercle	Adductor part: obturator nerve (L2-L4) Hamstring part: tibial nerve (L4)	Deep femoral artery, popliteal artery, obturator	Adducts and flexes thigh (adductor part) Extends thigh (hamstring part)
Gracilis	Body of pubis and inferior pubic ramus	Superior part of medial surface of tibia	Obturator nerve (L2-L3)	Deep femoral artery, medial circumflex femoral artery	Adducts thigh, flexes and medially rotates the leg
Obturator externus	Margins of obturator foramen and obturator membrane	Trochanteric fossa of femur	Obturator nerve (L2-L3)	Medial circumflex femoral artery, obturator artery	Laterally rotates the thigh and stabilizes head of femur in acetabulum

- Posterior (= flexor) compartment
 - Hamstrings
 - Biceps femoris-also lateral rotates knee
 - Semitendinosus-also medial rotates knee
 - Semimembranosus-also medial rotates knee
 - Together extend hip (except short head of biceps femoris) and flex knee
 - Hamstring part of adductor magnus-extends hip

Posterior Thigh Muscles

Muscle	Origin	Insertion	Innervation	Blood Supply	Action
Semitendinosus	Upper and medial ischial tuberosity	Superior part of medial surface of tibia	Tibial division of sciatic nerve (L5-S2)	Perforating branch of deep artery of thigh, superior muscular branches of popliteal artery	Flexes leg, extends thigh
Semimembranosus	Upper and lateral ischial tuberosity	Posterior part of medial condyle of tibia	Tibial division of sciatic nerve (L5-S2)	Perforating branch of deep artery of thigh, superior muscular branches of popliteal artery	Flexes leg, extends thigh
Biceps femoris	Long head-ischial tuberosity	Lateral side of head of fibula	Long head-tibial division of sciatic nerve (L5-S2)	Perforating branch of deep artery of thigh, superior muscular branches of	Flexes and laterally rotates leg, extends

393 / 425

	Short head-lateral lip of linea aspera, lateral supracondylar line of femur		Short head-common fibular division of sciatic nerve (L5-S2)	popliteal artery	thigh
--	---	--	---	------------------	-------

Femoral Triangle

- Boundaries
 - Superiorly: inguinal ligament
 - Medially: medial border of adductor longus
 - Laterally: medial border of sartorius
- Contents
 - Femoral nerve (descends outside of femoral sheath)
 - Femoral sheath
 - About 4 cm long, extending below inguinal ligament
 - Subdivided into three compartments
 - Lateral contains femoral artery
 - Intermediate contains femoral vein
 - Medial is femoral canal
 - Femoral canal
 - Potential space about 1.5 cm long
 - Contains loose connective tissue, lymphatic vessels, a deep inguinal lymph node (of Cloquet)
 - Femoral ring: abdominal entrance to femoral canal, closed by fatty tissue and parental peritoneum
 - Beyond extent of sheath
 - Femoral artery and branches
 - Femoral vein and tributaries

Adductor Canal (= subsartorial canal/Hunter's canal)

page 251
page 252

- Boundaries
 - Superiorly: commences at apex of femoral triangle
 - Posteriorly: adductors longus and magnus
 - Anteromedially: sartorius and fascia
 - Anterolaterally: vastus medialis
 - Inferiorly: terminates at adductor hiatus (in tendon of adductor magnus)
- Contents
 - Femoral artery and femoral vein
 - Pass through adductor hiatus
 - Become popliteal artery and vein when they enter popliteal fossa
 - Nerves
 - Saphenous nerve
 - Nerve to vastus medialis
 - Lymphatics

FACTS & HINTS

HIGH-YIELD FACTS

Anatomic Points

Hip Joint

The hip joint is a stable ball and socket joint that carries the whole body weight. Its stability results from the snug fit of the large femoral head and deep acetabulum, which is supported on all sides by powerful intrinsic ligaments and muscles. There is a tendency for the trunk to tilt backwards at the hip joints, because the line of gravity passes posteriorly; the powerful iliofemoral ligament resists this.

Clinical Points

Femoral Hernia

- Occur when part of an abdominal viscus or fat protrudes into the femoral canal through its opening, the femoral ring
- More common in women because of wider femoral ring
- Present as a mass (often tender) inferolateral to the pubic tubercle
- May enlarge by passing through the saphenous opening
- Are at a high risk of strangulation because of hard margins of femoral ring
- Surgical reduction and repair is usually necessary

Fractured Neck of Femur ("Broken hip")

- Common in the elderly, particularly women with osteoporotic bone
- Can occur as the result of high impact accident, such as head-on car collision
- May damage branches of medial circumflex femoral artery supplying the femoral head
- Results in bleeding into the hip joint and avascular necrosis of the head of the femur

page 252

page 253

MNEMONICS

Memory Aids

Femoral Triangle Boundaries:	So I May Always Love Sally
	Superiorly-Inguinal ligament, Medially
	Adductor longus, Laterally-Sartorius

Memory Aids

Contents entering the femoral triangle (lateral to medial) as they pass under the inguinal ligament):	NAVEL
	Nerve*
	Artery
	Vein
	Empty space**
	Lacunar ligament***

* Nerve = Femoral, but it does not descend with the femoral artery and vein in the femoral sheath. It travels on the surface of the iliopsoas muscle. The femoral branch of the genitofemoral nerve travels beneath the inguinal ligament just lateral to the femoral artery, within the femoral sheath.

** Empty space = Femoral canal, because it is a potential space filled with compressible tissue.

*** The lacunar ligament is the hard medial margin of the femoral ring; it is an expansion of the inguinal ligament. Filling the gap between the attachment of the inguinal ligament to the pubic tubercle and the pecten pubis, posteriorly.

51 Knee

STUDY AIMS

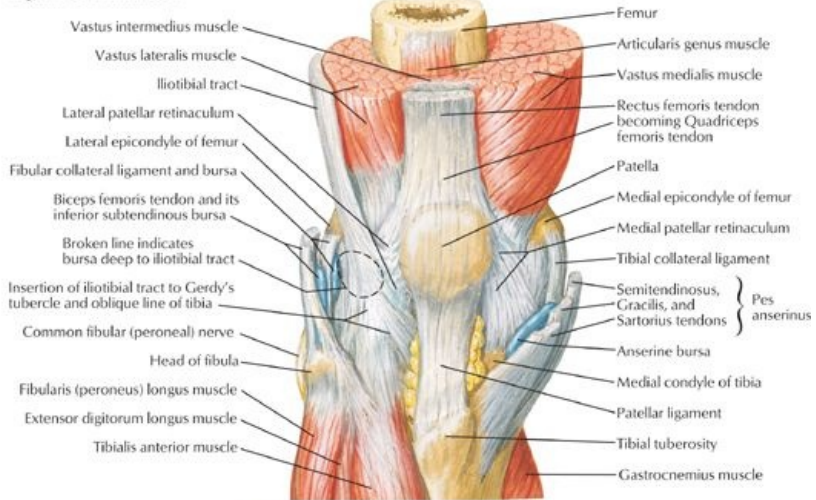
At the end of your study, you should be able to:

- Understand the movements of the knee joint
- Describe the attachments and functions of the ligaments strengthening the joint
- Identify the major bursae surrounding the knee and understand their function
- Identify the margins of the popliteal fossa and describe its contents

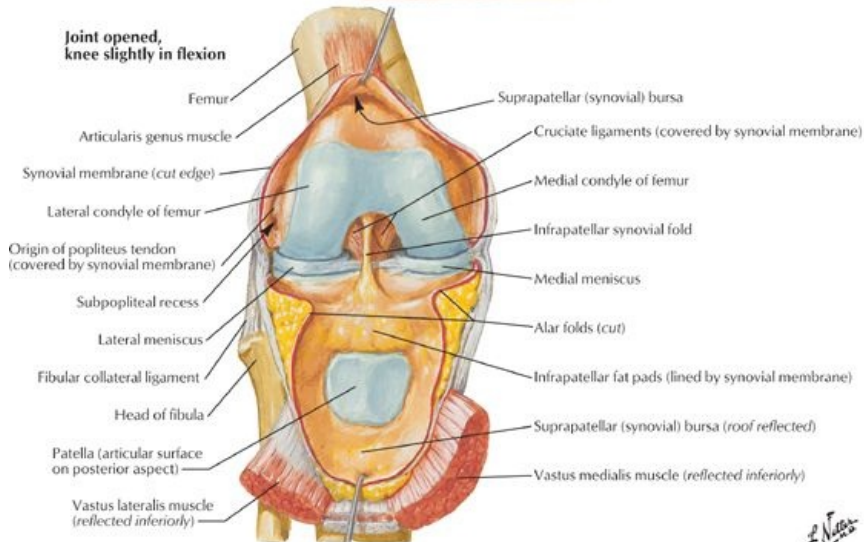
GUIDE

Lower Limb: Knee

Right knee in extension

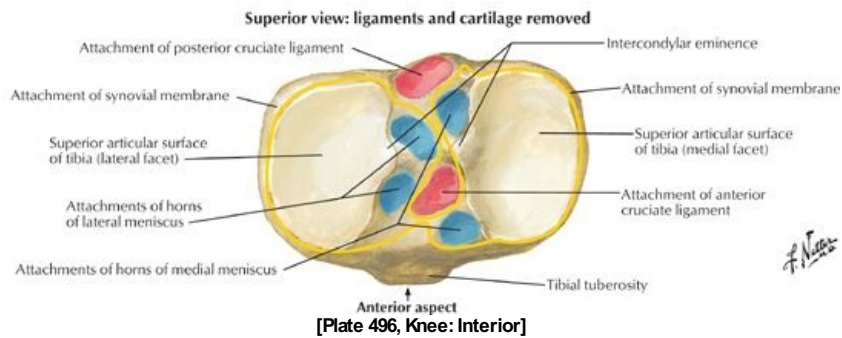
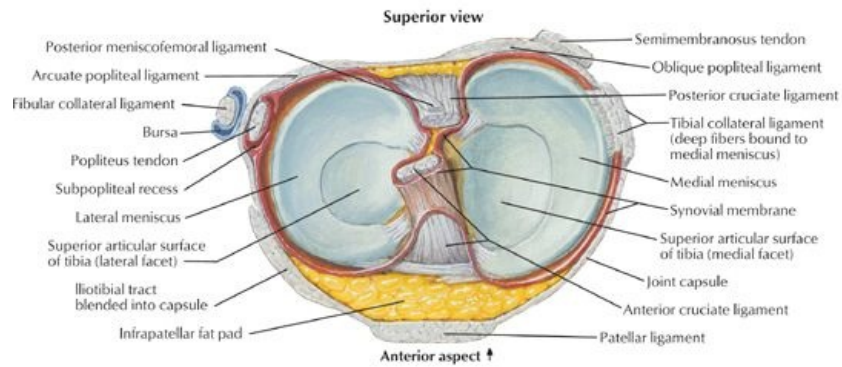
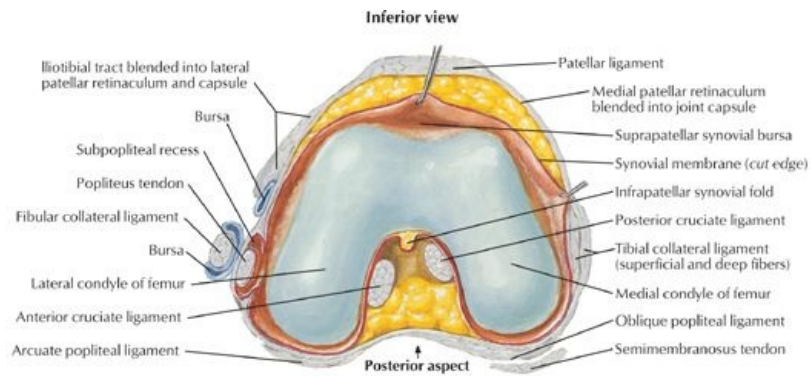


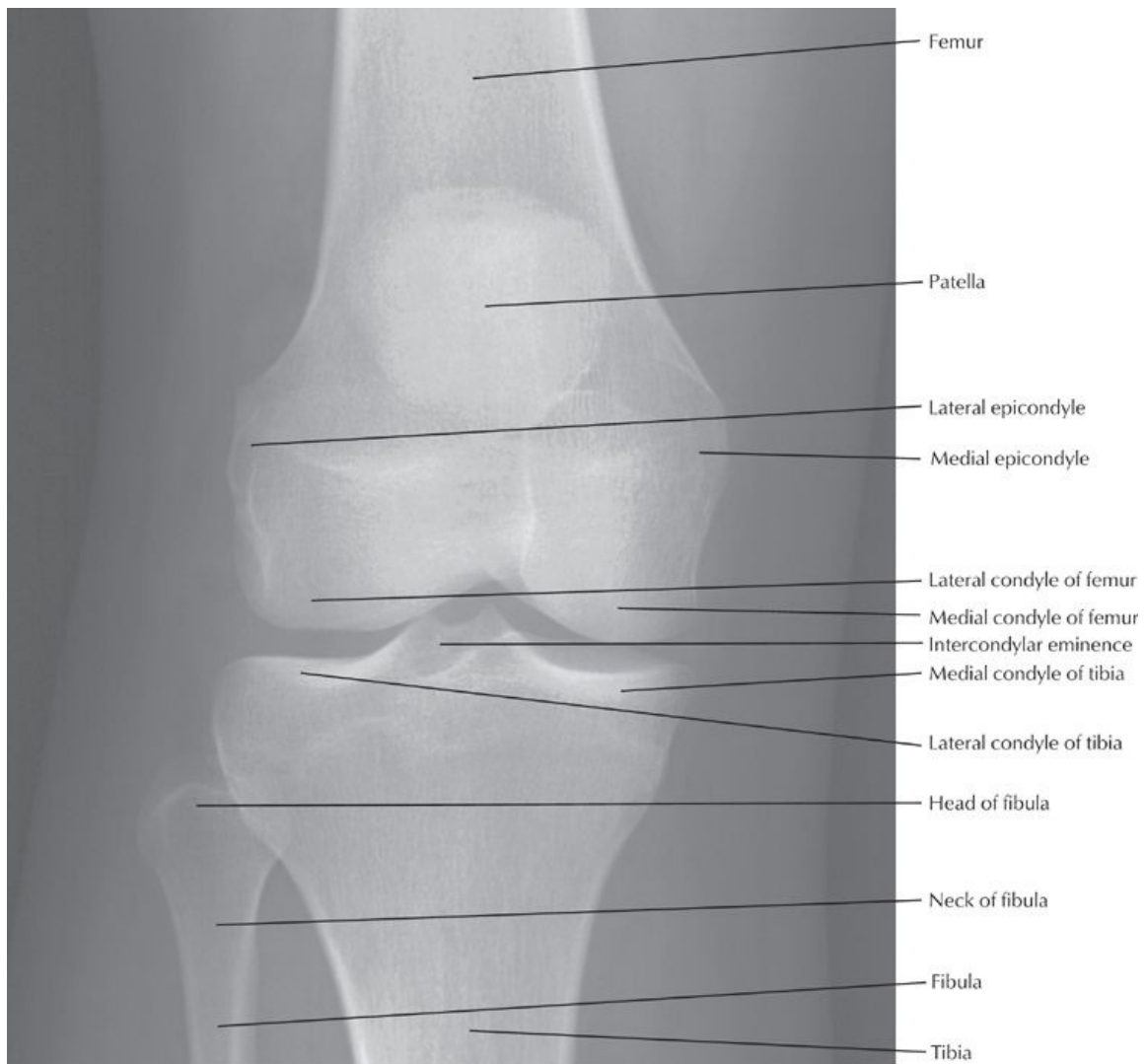
Joint opened, knee slightly in flexion



[Plate 495, Knee: Anterior Views]

F. Netter





[Plate 498, Knee: Anteroposterior Radiograph]

Knee Joint

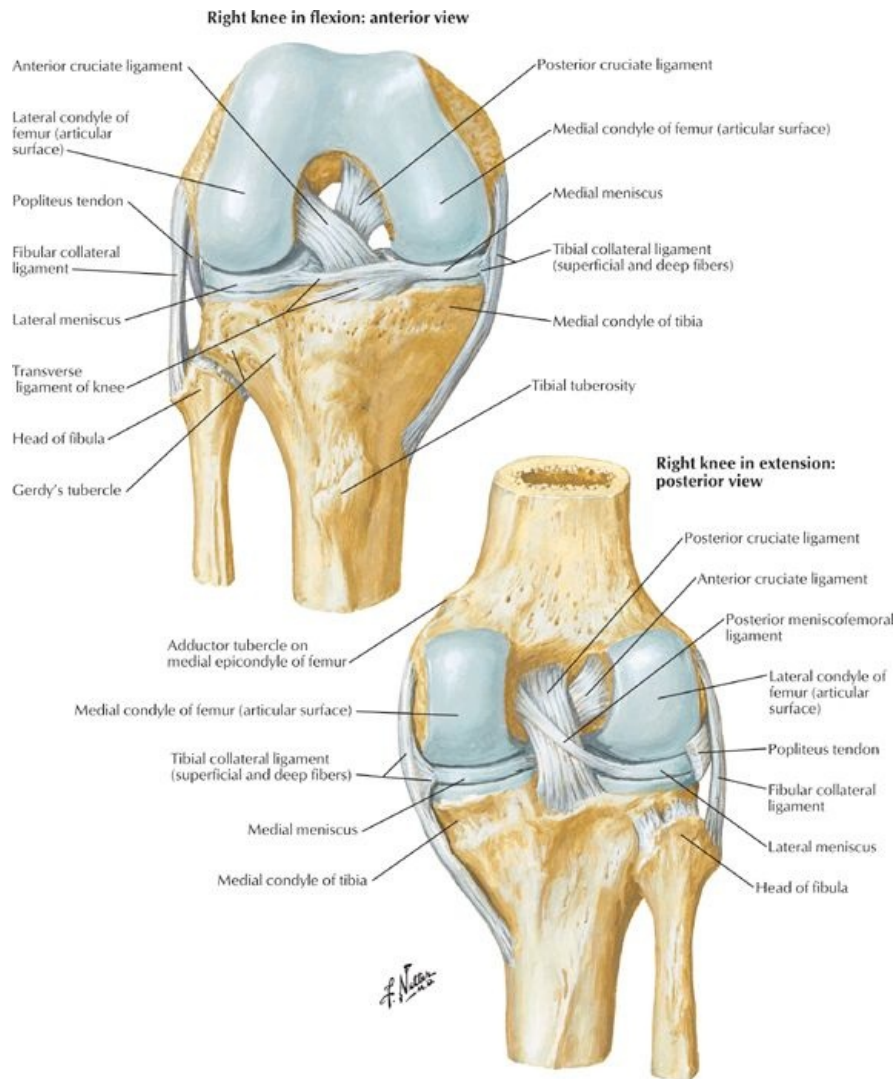
- Biaxial, hinge-type synovial joint
- Movements
 - Flexion and extension
 - Some gliding and rolling
 - Some medial and lateral rotation about vertical axis
- Articular capsule-thin and weak, offers little support in itself
- Fibrous capsule
 - Strong
 - Attaches to femur superior to condyles
 - Attaches to articular margin of tibia
 - Deficient superiorly on lateral tibial condyle, to allow passage of popliteus tendon
 - Deficient inferiorly where tendon of popliteus crosses
- Blood supply
 - Genicular branches of the femoral and popliteal arteries
 - Lateral and medial superior genicular
 - Middle genicular
 - Lateral and medial inferior genicular
 - Anterior tibial recurrent → anterior and posterior recurrent arteries
 - Circumflex fibular artery → anterior and posterior recurrent arteries
 - Arteries form genicular anastomosis around the knee
- Nerve supply (see Section 7-2: Lower Limb: Hip and Thigh)
 - Obturator
 - Articular branches of femoral, tibial, and common fibular nerves

Bones Articulating in the Knee Joint

- Lateral and medial articulations between femoral condyles and tibial condyles
- Smooth superior surface of tibia for articulation called tibial plateau

- Intermediate articulation between patella and femur
- Patella
 - Large sesamoid bone embedded in the quadriceps tendon
 - Articulation called patellofemoral joint

Ligaments Reinforcing Fibrous Capsule



[Plate 497, Knee: Cruciate and Collateral Ligaments]

- Extracapsular
 - Medial (tibial) collateral ligament
 - Flat and band-like
 - Attached to medial meniscus on deep surface
 - Lateral (fibular) collateral ligament
 - Strong and cord-like
 - Separated by lateral meniscus by tendon of popliteus muscle
 - Splits tendon of biceps prior to its insertion
 - Patellar ligament
 - Oblique popliteal ligament
 - Arcuate popliteal ligament
- Intracapsular ligaments
 - Anterior cruciate ligament
 - Extends from posterior medial side of lateral femoral condyle to anterior intercondylar area of tibia
 - Taut when knee is fully extended
 - Prevents posterior displacement of femur on tibia and hyperextension of joint
 - Intracapsular but extrasynovial
 - Posterior cruciate ligament
 - Stronger of two cruciate ligaments
 - Extends from lateral surface of medial condyle of femur to posterior intercondylar region of tibia
 - Taut during flexion
 - Prevents anterior displacement of femur on tibia
- Medial and lateral menisci
 - Crescentic plates of fibrocartilage
 - Wedge-shaped to deepen articulating surface of tibia

- o Function as "shock absorbers"
- o Transverse ligament of knee joins anterior surfaces of menisci
- o Medial meniscus
 - C-shaped
 - Adherent to tibial collateral ligament
- o Lateral meniscus
 - O-shaped
 - Joined to posterior cruciate ligament and medial femoral condyle by posterior menisiofemoral ligament

Ligaments of the Knee Joint

Ligament	Attachments	Function
Extracapsular Ligaments		
Patellar	Patella → tibial tuberosity	Continuation of quadriceps tendon
Tibial collateral	Medial femoral epicondyle → medial tibial condyle (and meniscus)	Limits extension Limits abduction
Fibular collateral	Lateral femoral epicondyle → fibular head	Limits extension Limits adduction
Arcuate popliteal	Fibular head → capsule	Limits medial rotation
Oblique popliteal	Lateral femur → posterior tibia	Limits hyperextension
Intracapsular Ligaments		
Anterior cruciate (extrasynovial)	Lateral femoral condyle → anterior intercondylar tibia	Prevents posterior slipping of femur on tibia (Torn in hyperextension)
Posterior cruciate (extrasynovial)	Medial femoral condyle → posterior intercondylar tibia	Prevents anterior slipping of femur on tibia
Transverse	Anterior edges of menisci	Stabilizes menisci
Posterior menisiofemoral	Posterior of lateral meniscus → medial femoral condyle	Stabilizes lateral meniscus

Bursae Around the Knee Joint

- Many (12+) bursae surround the knee
 - o Facilitate movement of the tendons and skin over the joint during flexion or extension
 - o Needed because most tendons pull vertically across joint
- Four bursae communicate with the synovial cavity of the knee
 - o Suprapatellar
 - o Popliteus
 - o Anserine
 - o Gastrocnemius bursae
- Suprapatellar bursa
 - o Particularly vulnerable to infection following penetrating trauma
 - o Allows spread of infection directly into the knee joint

Main Bursae of the Knee

Bursa	Location
Suprapatellar	Between femur and quadriceps tendon
Popliteus	Between lateral tibial condyle and popliteus tendon
Anserine	Between tibial collateral ligament and tendons of sartorius, gracilis, and semitendinosus
Gastrocnemius	Deep to proximal attachment of medial gastrocnemius head
Semimembranosus	Deep to tendon of semimembranosus
Semitendinosus	Deep to heads of gastrocnemius muscles
Prepatellar	Between skin and anterior surface of patella
Subcutaneous infrapatellar	Between skin and tibial tuberosity
Deep infrapatellar	Between tibia and patellar ligament

Popliteal Fossa

- Boundaries
 - o Superomedially: semitendinosus and semimembranosus
 - o Superolaterally: biceps femoris
 - o Inferomedially and laterally: medial and lateral heads of the gastrocnemius
 - o Floor: popliteal surface of femur, oblique popliteal ligament, fascia over popliteus muscle
 - o Roof: skin and fascia
- Contents
 - o Small saphenous vein
 - o Popliteal artery and veins (*deeper than the nerves*)
 - o Tibial nerve and common fibular nerve (from the sciatic)
 - o Posterior cutaneous nerve of thigh
 - o Lymphatic vessels and nodes
 - o *Order of structures (lateral to medial): tibial nerve, vein, artery*

page 256
page 257

FACTS & HINTS

HIGH-YIELD FACTS

Clinical Points

Baker's Cyst

- Posterior herniation of the synovial membrane through the joint capsule into the popliteal fossa
- Swelling appears below joint line and may extend as far as the midcalf
- Large swellings may interfere with knee movements but otherwise asymptomatic

Bursitis

- Inflammation of the bursa surrounding the knee because of repeated frictional forces
- In chronic inflammation, bursae become distended and filled with fluid
- Prepatellar bursitis (housemaid's knee) and infrapatellar bursitis (clergyman's knee) are most recognized variants

Knee Injury

- Knee injuries common, as the knee joint has little external supportive tissue
- Ligament sprains usually self-limiting, but may cause secondary damage to menisci
- Tearing of the ligaments often needs surgical correction
- Rupture of anterior cruciate ligament occurs when force is directed anteriorly to the semi-flexed knee, typically occurring in skiers and footballers
- Posterior cruciate ligament is more resilient to injury, but may rupture when force is applied to the tibial tuberosity while the knee is flexed
- Collateral ligaments are vulnerable to lateral stresses

MNEMONICS

Memory Aids

Knock-knee and Bowleg:	Genu valgum vs. Genu vargum
Knock-knee:	Genu valgum
	Genu val GUM -knees are GUM med together
Bowleg:	Genu vargum
	Genu VAR gum- VAR rhymes with far-knees are VAR (far) apart

52 Leg

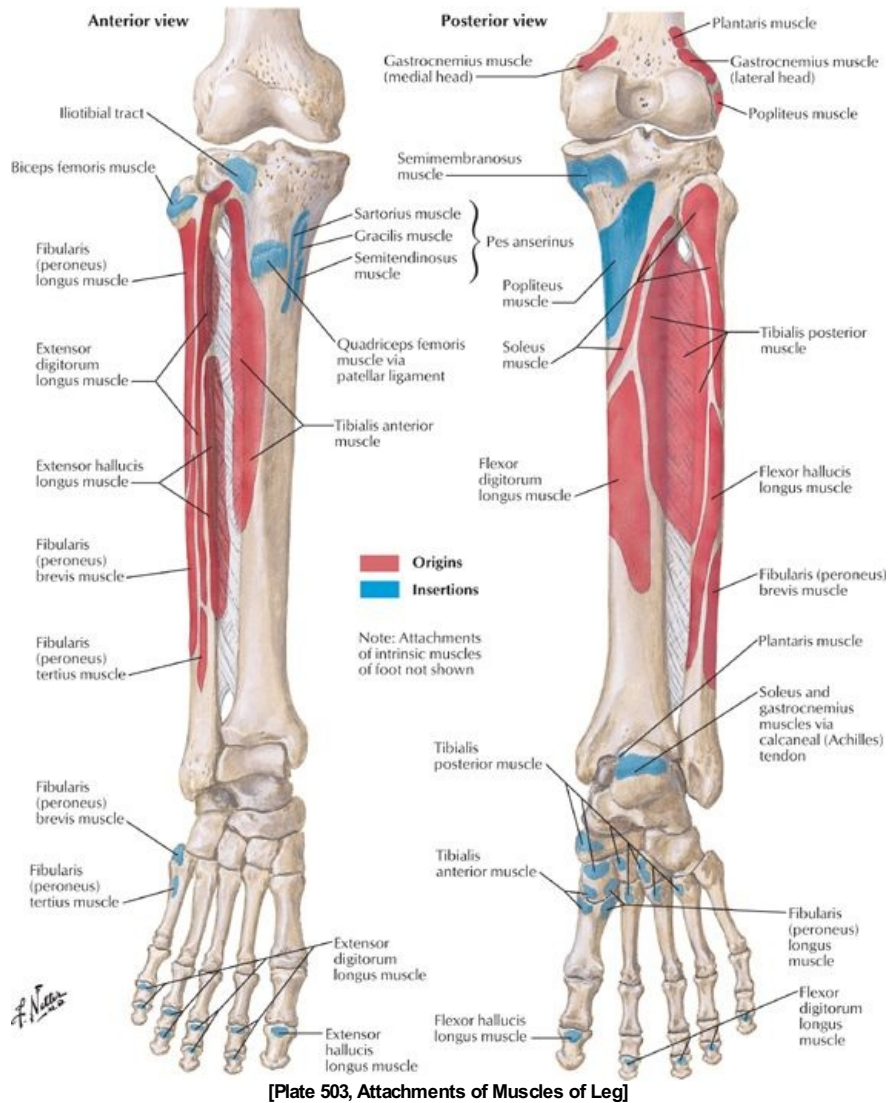
STUDY AIMS

At the end of your study, you should be able to:

- Describe the fascial compartments of the leg and understand their importance
- Identify the different parts and surface markings of the tibia and fibula
- Know the origins, insertions, and actions of the muscles of the leg

GUIDE

Lower Limb: Leg



Bones

- Tibia
 - Large, weightbearing
 - Osteological features
 - Medial and lateral condyles-medial and lateral protuberances at proximal end articulate with femur
 - Intercondylar eminence-together with condyles forms tibial plateau, fits into intercondylar fossa of femur
 - Tibial tuberosity-proximal end of anterior border, broad bump for attachment of patellar ligament
 - Gerdy's tubercle-Protrusion from lateral condyle to which iliotibial tract attaches
 - Shaft-or body, with rough diagonal ridge on posterior proximal end: soleal line
 - Medial malleolus-inferomedial projection at distal end, articulates with talus
- Fibula
 - Slender, nonweightbearing
 - Osteological features
 - Head-proximal end with pointed apex, articulates with tibia
 - Shaft-or body, has three borders (anterior, interosseous, and posterior) and surfaces (anterior, posterior and lateral) for muscle attachments
 - Lateral malleolus-distal enlargement, articulates with tibia, contributes to ankle joint
- Interosseous membrane uniting tibia and fibula

Fascial Compartments

- Crural fascia
 - Deep fascia surrounding leg
 - Distal continuation of fascia lata

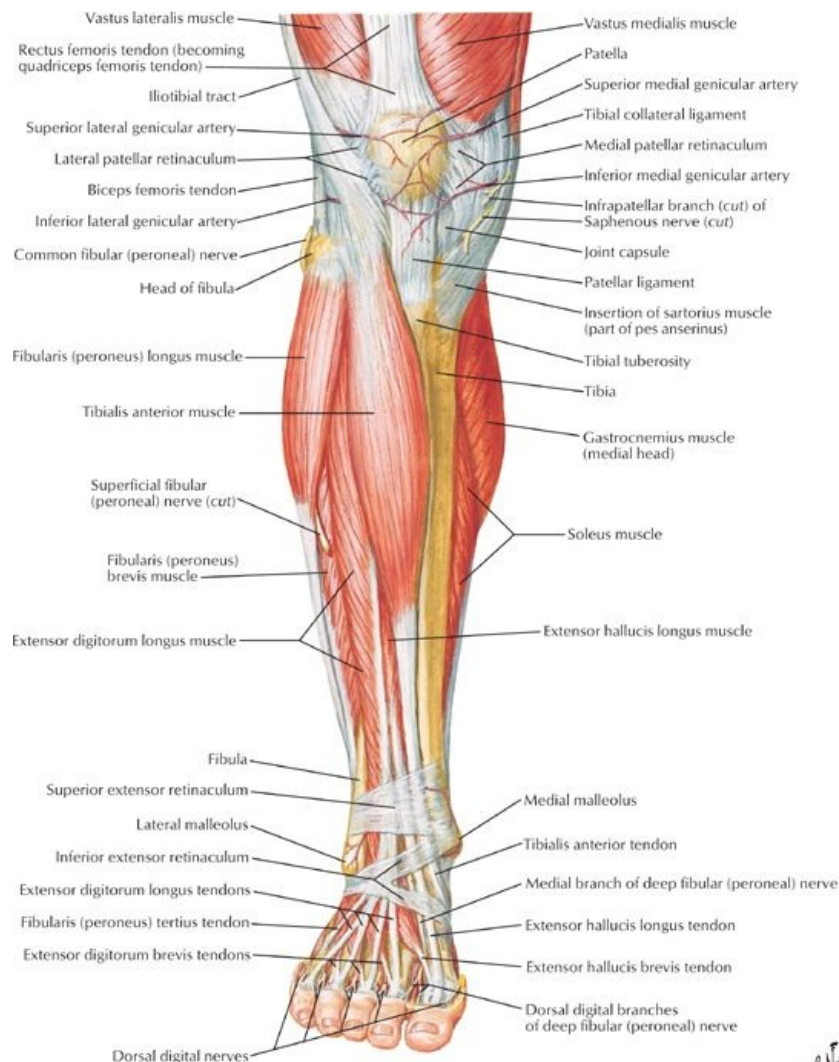
page 258
page 259

- Attaches to anterior and medial borders of tibia
- Thicker in proximal leg
- Continues as extensor retinaculum distally
- Extensions from deep surface-anterior and posterior intermuscular septa-attach to anterior and posterior margins of fibula
- Intermuscular septa and interosseous membrane divide leg into three fascial compartments: anterior, lateral, and posterior
- Muscles in posterior compartment are subdivided into superficial and deep compartments by transverse intermuscular septum

Joints

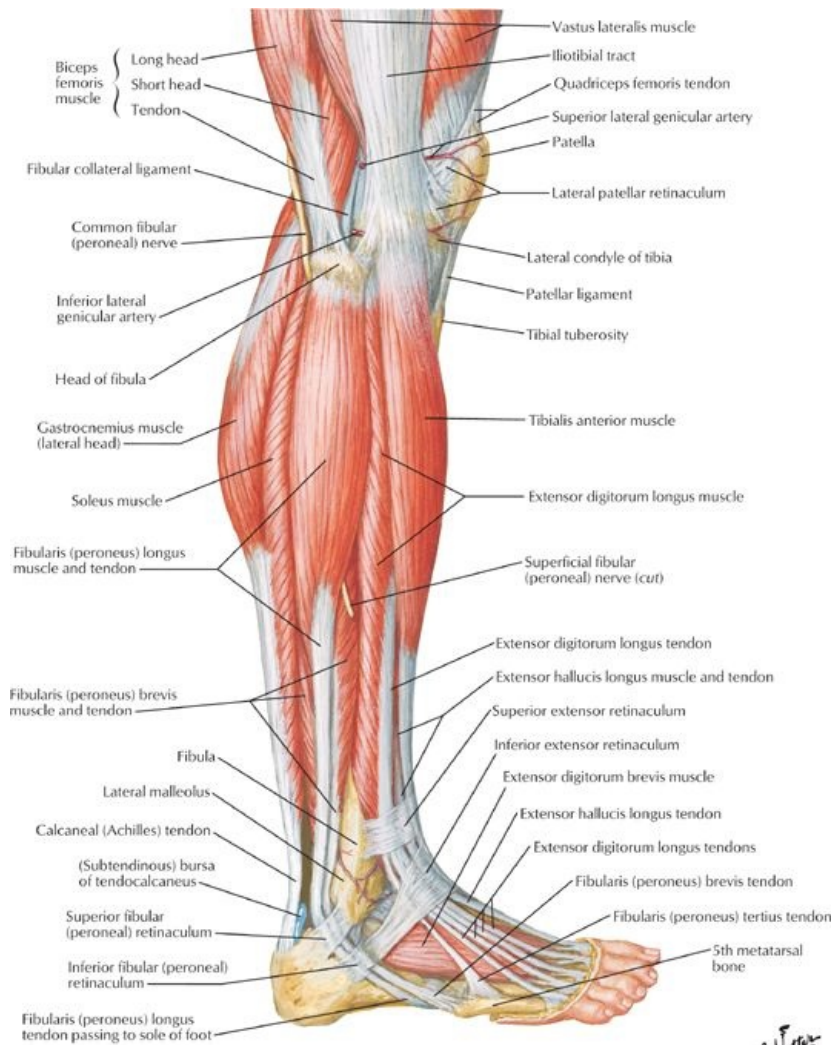
- Proximal tibiofibular joint
 - Plane-type synovial joint
 - Nonweightbearing
 - Between head of fibular and lateral condyle of tibia
 - Fibrous capsule reinforced by anterior and posterior ligaments of the head of the fibula
- Distal tibiofibular
 - Fibrous joint (syndesmosis)
 - Medial surface of distal fibula articulates with facet on inferior end of tibia
 - Reinforced by anterior and posterior tibiafibular ligaments and interosseous ligament (extension of interosseous membrane)

Muscles



[Plate 507, Muscles of Leg (Superficial Dissection): Anterior View]

F. Netter



[Plate 509, Muscles of Leg: Lateral View]

- Anterior (= extensor) compartment
 - Primarily dorsiflexors of ankle
 - Include
 - Tibialis anterior (also inverts foot and holds up medial longitudinal arch of foot)
 - Extensor hallucis longus (also dorsiflexes hallux and inverts foot)
 - Extensor digitorum longus (also dorsiflexes toes)
 - Peroneus tertius (also everts foot)

Muscles of the Anterior Leg

Muscle	Origin	Insertion	Innervation	Blood Supply	Action
Tibialis anterior	Lateral condyle and proximal half of lateral tibia, interosseous membrane	Medial plantar surfaces of medial cuneiform and base of first metatarsal	Deep fibular nerve (L4-L5)	Anterior tibial artery	Dorsiflexes ankle and inverts foot
Extensor hallucis longus	Middle part of anterior surface of fibula and interosseous membrane	Dorsal aspect of base of distal phalanx of great toe	Deep fibular nerve (L5-S1)	Anterior tibial artery	Extends great toe and dorsiflexes ankle
Extensor digitorum longus	Lateral condyle of tibia and proximal three quarters of anterior surface of interosseous membrane	Middle and distal phalanges of second through fifth toes	Deep fibular nerve (L5-S1)	Anterior tibial artery	Extends second through fifth toes and dorsiflexes ankle
Fibularis (peroneus) tertius	Distal third of anterior surface of fibula and interosseous membrane	Dorsum of base of fifth metatarsal	Deep fibular nerve (L5-S1)	Anterior tibial artery	Dorsiflexes ankle and aids in eversion of foot

page 259
page 260

- Lateral (= everter) compartment
 - Primarily everters of the foot
 - Include
 - Peroneus longus
 - Peroneus brevis
 - Both plantarflex ankle, evert foot, and hold up lateral longitudinal arch of foot

Muscles of the Lateral Leg

Muscle	Origin	Insertion	Innervation	Blood Supply	Action
Fibularis (peroneus) longus	Head and proximal two thirds of lateral fibula	Plantar base of first metatarsal and medial cuneiform	Superficial fibular nerve (L5 - S2)	Anterior tibial artery, fibular artery	Everts foot and weakly plantarflexes ankle
Fibularis (peroneus) brevis	Distal two thirds of lateral surface of fibula	Dorsal surface of tuberosity on base of fifth metatarsal	Superficial fibular nerve (L5 - S2)	Fibular artery	Everts foot and weakly plantarflexes ankle

- Posterior compartment
 - Comprised of superficial and deep groups
 - Separated by transverse intermuscular septum
 - Superficial group = plantar flexors of the foot
 - Gastrocnemius
 - Soleus
 - Plantaris
 - Gastrocnemius and plantaris cross the knee joint and thus also flex knee
 - All three contribute to calcaneal tendon
 - Deep group = plantar flexors of the foot
 - Tibialis posterior (also inverts foot and supports medial longitudinal arch of foot)
 - Flexor hallucis longus (also plantarflexes interphalangeal joint of hallux and supports medial longitudinal arch of foot)
 - Flexor digitorum longus (also plantarflexes DIP joints of lateral four toes and supports medial and lateral longitudinal arches of foot)
 - Popliteus
 - Forms inferior floor of popliteal fossa
 - Tendon lies between fibrous capsule and synovial membrane of knee joint
 - Flexes knee
 - Rotates femur five degrees laterally on tibial plateau to unlock knee so flexion can occur

Muscles of the Posterior Leg

page 260
page 261

Muscle	Origin	Insertion	Innervation	Blood Supply	Action
Superficial Muscles					
Gastrocnemius	Lateral head: lateral aspect of lateral condyle of femur. Medial head: popliteal surface above medial condyle of femur	Posterior aspect of calcaneus via the calcaneal tendon	Tibial nerve (S1-S2)	Popliteal artery	Plantarflexes the ankle joint, assists in flexion of the knee joint
Soleus	Posterior aspect of head of fibula, proximal fourth of posterior surface of fibula, soleal line of tibia	Posterior aspect of calcaneus via the calcaneal tendon	Tibial nerve (S1-S2)	Posterior tibial artery, fibular artery, popliteal artery	Plantarflexes the ankle and stabilizes the leg over the foot
Plantaris	Popliteal surface of femur	Calcaneal tendon	Tibial nerve (L5-S1)	Popliteal artery	Weakly assists gastrocnemius
Deep Muscles					
Popliteus	Lateral aspect of lateral condyle of femur and lateral meniscus	Posterior tibia above soleal line	Tibial nerve (L4 - S1)	Popliteal artery	Unlocks and weakly flexes knee joint
Flexor hallucis longus	Distal two-thirds of posterior fibula and inferior part of interosseous membrane	Base of distal phalanx of great toe (hallux)	Tibial nerve (L5 - S2)	Fibular artery	Flexes great toe, weakly plantarflexes the ankle
Flexor digitorum longus	Medial part of posterior tibia inferior to soleal line	Plantar bases of distal phalanges of lateral four toes	Tibial nerve (L5-S1)	Posterior tibial artery	Flexes lateral four toes, plantarflexes ankle
Tibialis posterior	Posterior tibia below soleal line, interosseous membrane, proximal half of posterior fibula	Tuberosity of navicular bone, all cuneiforms, cuboid and bases of second through fourth metatarsals	Tibial nerve (L4-L5)	Fibular artery	Plantarflexes foot at the ankle and inverts the foot

FACTS & HINTS

HIGH-YIELD FACTS

Clinical Points

page 261
page 262

Compartment Syndrome

- Abnormally high pressure within one of the leg's restricted compartments
- Caused by hemorrhage, edema, or inflammation of the muscles of the leg, often secondary to trauma or deep vein thrombosis
- Increased compartmental pressure causes ischemia and nerve damage
- May lead to permanent injury of distal structures supplied by affected arteries and veins
- Management is surgical: fasciotomy and debridement of any necrotic tissue

Shin Splints (tibialis anterior strain)

- Edema and pain over distal two thirds of the tibia
- Caused by repetitive microtrauma to the tibialis anterior muscle
- Common in athletic overexertion
- Often in persons who do not exercise, when they try a long distance walk
- A mild form of anterior compartment syndrome
- Chronic condition can cause periostitis and bone remodeling, or lead to stress fractures

Ruptured Achilles' Tendon

- Tendonitis of the calcaneal tendon
- A common running injury
- Rupture of the tendon usually occurs in untrained middle-aged individuals with a history of tendonitis
- Presents as sudden calf pain with an audible snap and subsequent inability to plantarflex the foot
- Gap is palpable in complete rupture

MNEMONICS

Memory Aids

Deep posterior leg muscles (medial to lateral):	Down The Hatch
	Flexor Digitorum longus
	Tibialis posterior
	Flexor Hallucis longus
<i>(structures behind medial malleolus-see Section 7-5: Ankle and Foot)</i>	
Symptoms of varicose veins:	AEIOU
	Aching
	Eczema
	Itching
	Oedema
	Ulceration/Ugly (varicosities)

53 Ankle and Foot

STUDY AIMS

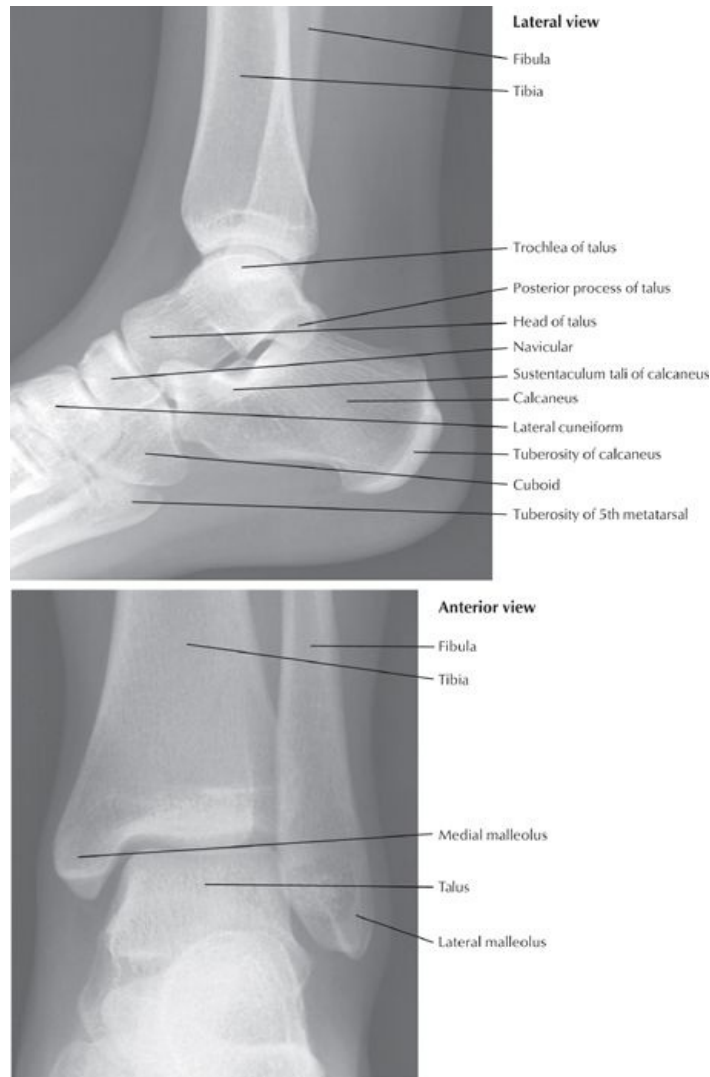
At the end of your study, you should be able to:

- Understand the structure of the ankle mortise and its supporting ligaments and appreciate its vulnerability to injury
- Know the bones of the foot and their organization
- Understand the functional importance of the ligaments and fascia of the foot
- Describe the arches of the foot
- Understand the arrangement of the intrinsic muscles of the foot
- Know the descriptive layers of the plantar surface of the foot

GUIDE

Lower Limb: Ankle and Foot

Ankle Joint (Talocrural Joint)

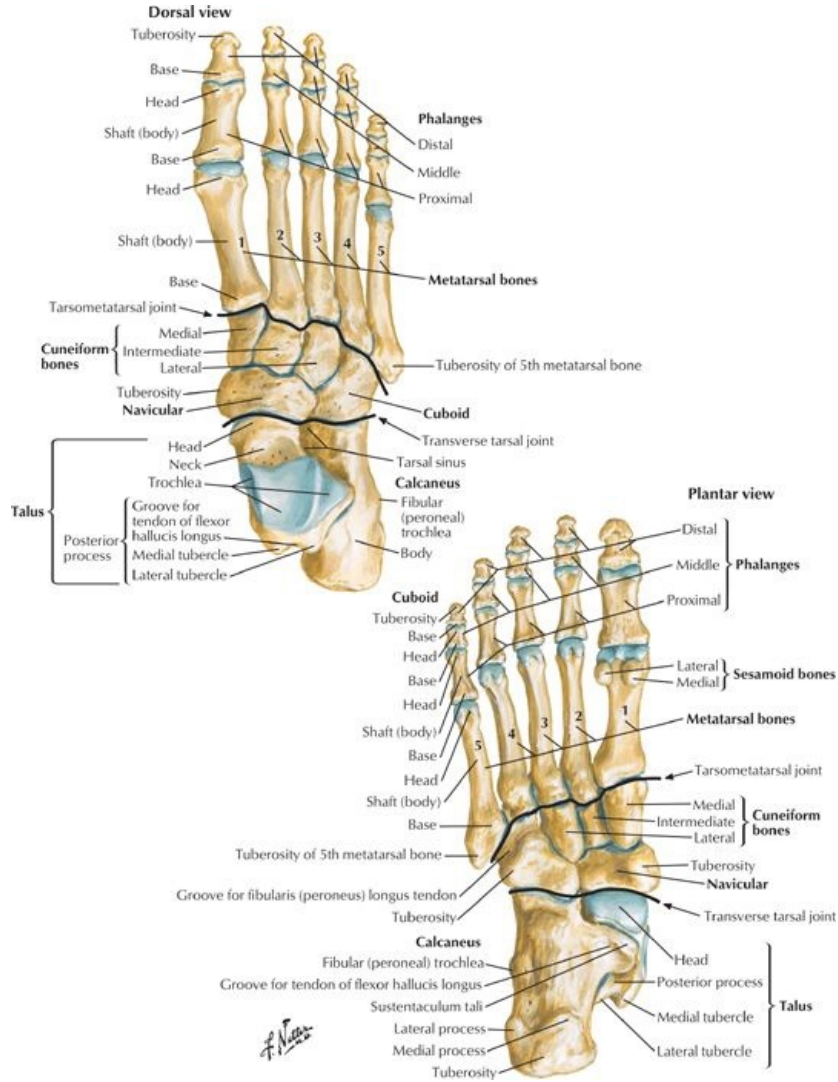


[Plate 514, Ankle: Radiographs]

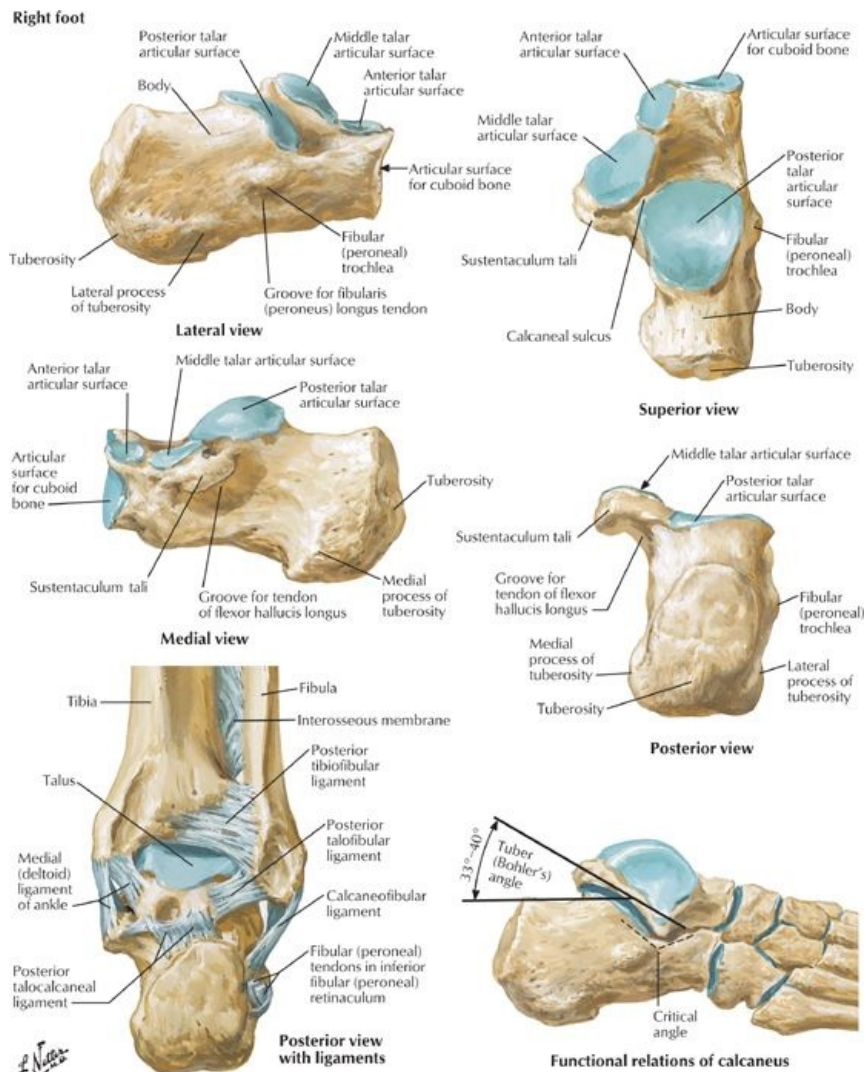
- Uniaxial, synovial, hinge type joint
- Articulation between tibia (medial malleolus), fibula (lateral malleolus), and talus
 - Distal ends of tibia and fibula form a mortise
 - Trochlea of talus fits into mortise
 - Malleoli grip talus
- Movements
 - Dorsiflexion
 - Produced by muscles of anterior compartment of leg
 - Limited by triceps surae
 - More stable when dorsiflexed
 - Plantarflexion-produced by muscles of posterior compartment of leg
 - Some rotation, abduction, and adduction of joint possible in plantar flexion
- Capsule
 - Thin
 - Supported by strong collateral ligament
 - Attached to tibia and malleoli superiorly and talus inferiorly
- Ligaments
 - Lateral consists of three parts
 - Anterior talofibular-from lateral malleolus to neck of talus
 - Posterior talofibular-from malleolar fossa to lateral tubercle of talus
 - Calcaneofibular-from tip of lateral malleolus to lateral calcaneus
 - Medial or deltoid
 - Strong ligament
 - Originates on medial malleolus
 - Fibers can be identified as

- Anterior and posterior tibiotalar
- Tibionavicular
- Tibiocalcaneal
- Blood supply: malleolar branches of fibular, and anterior and posterior tibial arteries
- Nerve supply: Tibial nerve and deep fibular nerve (a branch of the common fibular)

Foot



[Plate 511, Bones of Foot]



[Plate 513, Calcaneus]

Bones

- 26 in number
- Tarsal bones (7)
 - Talus
 - Has head, neck, body with trochlea, posterior, and lateral processes
 - Articulates with fibula, calcaneus, and navicular
 - Has no muscular attachments
 - Head rests on lateral projection of calcaneus-sustentaculum tali
 - Wider anteriorly making the ankle more stable in dorsiflexion
 - Calcaneus
 - Largest and strongest bone
 - Posterior prominence-calcaneal tuberosity-with medial, lateral, and anterior tubercles
 - Articulates with the talus and cuboid
 - Transmits body weight from talus to ground
 - Lateral projection-sustentaculum tali-supports talar head
 - Navicular
 - Flattened bone with inferomedial tuberosity
 - Located between talar head and three cuneiform bones
 - Cuboid
 - Inferolateral groove for tendon of peroneus longus
 - Most lateral bone in distal row of tarsals
 - Cuneiform (3)
 - Medial, intermediate and lateral
 - Each articulates with navicular posteriorly and base of related metatarsal anteriorly
 - Lateral articulates with cuboid
- Metatarsals (5)
 - Have base (proximal), body, and head (distal)
 - Bases articulate with cuneiform and cuboid bones
 - Head articulates with proximal phalanges
 - Medial and lateral sesamoid bones on plantar surface of first metatarsal in plantar ligament
- Phalanges (14)
 - Great toe (hallux) has two-proximal and distal

- Other toes have three-proximal, middle and distal
- Each consists of proximal base, body, and distal head

Joints

- Important intertarsal joints
 - Where inversion and eversion occur
 - Subtalar
 - Synovial joint with where talus rests on calcaneus
 - Fibrous capsule supported by talocalcaneal ligaments
 - Transverse tarsal, composed of
 - Calcaneocuboid joint
 - Talonavicular joint
- Other joints where slight movement occurs
 - Talocalcaneal
 - Tarsometatarsal
 - Metatarsophalangeal (MTP)
 - Interphalangeal: proximal and distal (PIP and DIP)

page 264

page 265

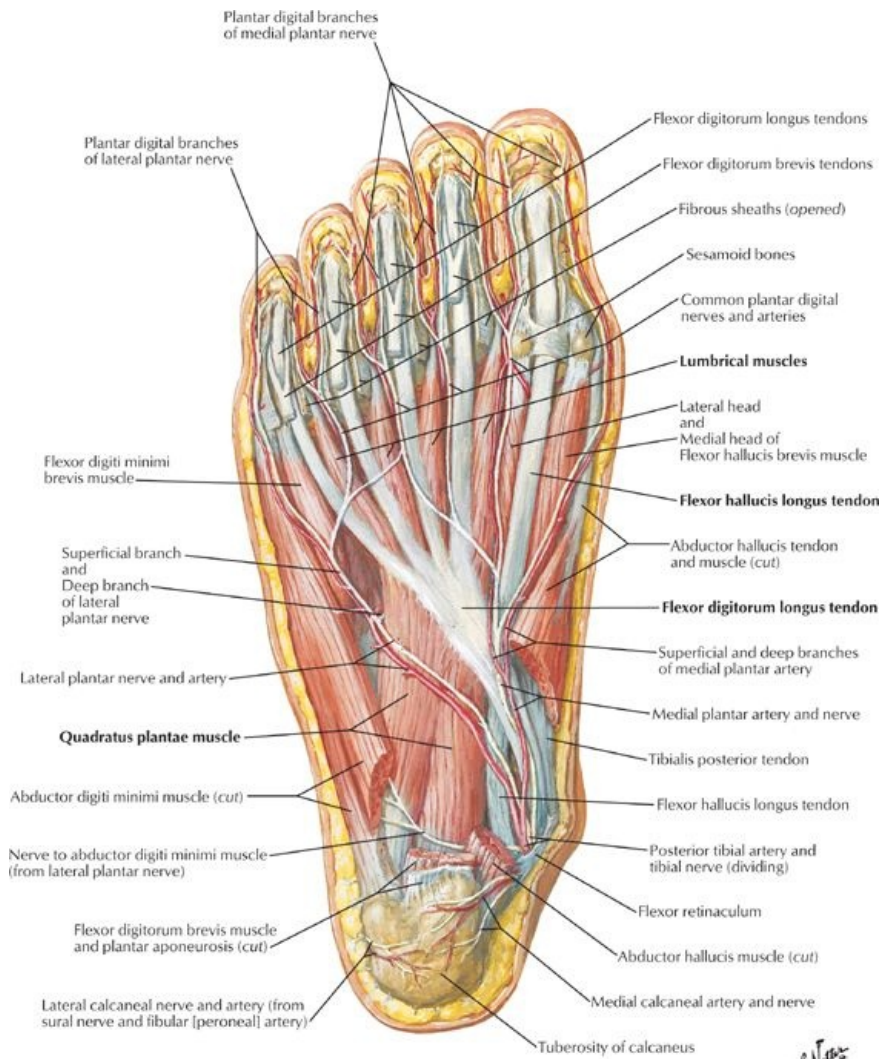
Arches

- Tarsal and metatarsal bones are arranged in longitudinal and transverse arches
- Bony arches maintained by
 - Interlocking bones
 - Plantar ligaments
 - Plantar aponeurosis
 - Action of plantar muscles
- Functions
 - Shock absorbers for body weight
 - Distribute body weight
 - Make foot adaptable to changes in surface
- Longitudinal arch composed of medial and lateral arches
- Medial longitudinal arch
 - Higher arch than lateral
 - Composed of calcaneus, talus, navicular, three cuneiforms, three medial metatarsals
 - Talar head is keystone
 - Strengthened by
 - Tibialis anterior tendon and attachments
 - Fibularis longus tendon
- Lateral longitudinal arch
 - Flatter than medial
 - Rests on the ground when standing
 - Composed of calcaneus, cuboid, and lateral two metatarsals
- Transverse arch
 - Formed by cuboid, cuneiforms, bases of metatarsals
 - Has pillars formed by lateral and medial longitudinal arches
 - Maintained by fibularis longus tendon

Ligaments (major ligaments listed)

- All foot bones are united by plantar and dorsal ligaments
- Plantar calcaneonavicular ligament
 - Also called spring ligament
 - From sustentaculum tali to navicular
 - Maintains longitudinal arch of foot
- Long plantar ligament
 - From plantar surface of calcaneus to cuboid
 - Maintains foot arches
- Plantar calcaneocuboid ligament
 - Also called short plantar ligament
 - Deep to the long plantar ligament
 - From inferior surface of calcaneus to inferior surface of cuboid

Plantar Muscles



[Plate 522, Muscles of Sole of Foot: Second Layer]

- Four layers in the sole of the foot
- Individual muscles of little importance as fine control of the toes is not required
- Aneurovascular plane exists between the first and second and third and fourth layers

page 265
page 266

Intrinsic Foot Muscles

Muscle	Proximal Attachment (Origin)	Distal Attachment (Insertion)	Layer of plantar foot	Innervation	Action
Abductor hallucis	Medial process of calcaneal tuberosity	Medial side, base of proximal phalanx of first toe	First Layer: deep to plantar aponeurosis	Medial plantar nerve (S2-S3)	Abducts and flexes first toe
Flexor digitorum brevis	Medial process of calcaneal tuberosity	Four tendons split to allow passage of long flexor tendons, insert on middle phalanges	First Layer: deep to plantar aponeurosis	Medial plantar nerve (S2-S3)	Flexes second through fifth toes
Abductor digiti minimi	Calcaneus	Lateral side, proximal phalanx of fifth toe	First Layer: deep to plantar aponeurosis	Lateral plantar nerve (S2-S3)	Abducts and flexes fifth toe
Quadratus plantae	Medial and lateral sides of plantar surface of calcaneus	Lateral edge of flexor digitorum longus tendon	Second Layer	Lateral plantar nerve (S1-S3)	Corrects for oblique pull of FDL tendon; thus assists in flexion of toes
Lumbricals	First: Medial side of tendon to second toe Second through fourth: Adjacent sides of contiguous tendons	Medial side of dorsal digital expansions	Second Layer	Medial one: Medial plantar nerve Lateral three: Lateral plantar nerve (S2-S3)	Flex proximal phalanges at MP joint, extend distal phalanges at PIP and DIP joints

Flexor hallucis brevis	Plantar surfaces of cuboid and lateral cuneiform	Divides in two, to each side of base of proximal phalanx of first toe	Third Layer	Medial plantar nerve (S1-S2)	Flexes proximal phalanx of first toe
Adductor hallucis	Oblique head: bases of second through fourth metatarsals Transverse head: Ligaments of metatarsophalangeal joints	Lateral side, base of proximal phalanx of first toe (both heads)	Third Layer	Deep branch of lateral plantar nerve (S2-S3)	Adducts first toe, maintains transverse arch
Flexor digiti minimi brevis	Base of fifth metatarsal	Base of proximal phalanx of fifth toe	Third Layer	Superficial branch, lateral plantar nerve (S2-S3)	Flexes proximal phalanx of fifth toe
Plantar interossei (3)	Bases and medial sides of third through fifth metatarsals	Medial sides of bases of proximal phalanges of third through fifth toes	Fourth Layer	Lateral plantar nerve (S2-S3)	Adduct second through fourth toes and flex MP joint
Dorsal interossei (4)	Adjacent sides of first through fifth metatarsals	First: medial side of proximal phalanx of second toe Second through fourth: lateral sides of second through fourth toes	Fourth Layer	Lateral plantar nerve (S2-S3)	Abduct second through fourth toes and flex MP joints

Dorsal Muscles of Foot

- Form bulge on dorsolateral surface of foot, anterior to lateral malleolus
- Two muscles blend together
- Extensor digitorum brevis
 - Proximal attachment: superior surface, anterolateral calcaneus
 - Splits into four muscles, each with a tendon that blends with that of long extensor
 - One tendon to great toe
 - Other tendons to second to fourth toes
- Extensor hallucis brevis
 - Largest and most medial belly of extensor digitorum brevis
 - Inserts on proximal phalanx of great toe
- Supplied by deep fibular nerve
- Assist extensor digitorum longus in extending toes

Fascia

- Deep fascia on dorsum of foot
 - Thin on dorsum
 - Continuous with inferior extensor retinaculum
 - Over lateral and posterior aspects it is continuous with plantar fascia
- Deep fascia of plantar surface of foot
 - Central condensation of plantar fascia forms plantar aponeurosis
 - Arises from calcaneus
 - Divides into five fibrous bands that split to enclose digital tendons
 - Vertical septa from deep surface divide the foot into medial, central, and lateral compartments
- Functions of plantar fascia
 - Holds foot together
 - Protects sole of foot from injury
 - Supports longitudinal arches

FACTS & HINTS

HIGH-YIELD FACTS

Clinical Points

Ankle Sprain

- As a result of tears in fibers of ligaments supporting the ankle
- Commonly the result of forced inversion of foot causing strain on weaker lateral ligaments
- Anterior talofibular ligament most likely to tear
- Result in instability of ankle joint
- Calcaneofibular ligament may also be torn

Ankle Fracture

- Severe ankle strain may fracture the medial, or more commonly, the lateral malleolus
- A Pott's fracture-dislocation occurs when foot is forcefully everted, shearing off the medial malleolus
- Lateral malleolus is then snapped as the talus moves laterally
- May also fracture fibula above distal tibiofibular joint and distal end of tibia

Plantar Fasciitis

- Microtrauma to proximal attachment of the plantar aponeurosis to the calcaneus, resulting in inflammation of plantar aponeurosis
- Caused by repetitive strain on the longitudinal plantar arch, such as during extensive running or high impact aerobics
- Pain felt over the proximal plantar surface of the foot
- Especially painful after sitting and first thing in the morning
- Treatment is conservative with rest and analgesia

MNEMONICS

Memory Aids

Structures traveling behind medial malleolus (anterior to posterior):	Tom, Dick ANd Harry
	Tibialis posterior flexor D igitorum longus flexor H allucis longus AN Posterior tibial A rtery and tibial N erve
	Interossei muscles: P lantar interossei A dduct the digits (PAD) D orsal interossei A bduct the digits (DAB)

page 268

page 269

Muscles that can potentially be absent in the body: 5 P's:	
P almaris longus	[Upper limb]
P lantar	[Lower limb]
P eroneus*	[Lower limb]
P yramidalis	[Anterior abdominal wall]
P soas minor	[Posterior abdominal wall]

* = peroneus (fibularis) tertius

54 Neurovasculature

STUDY AIMS

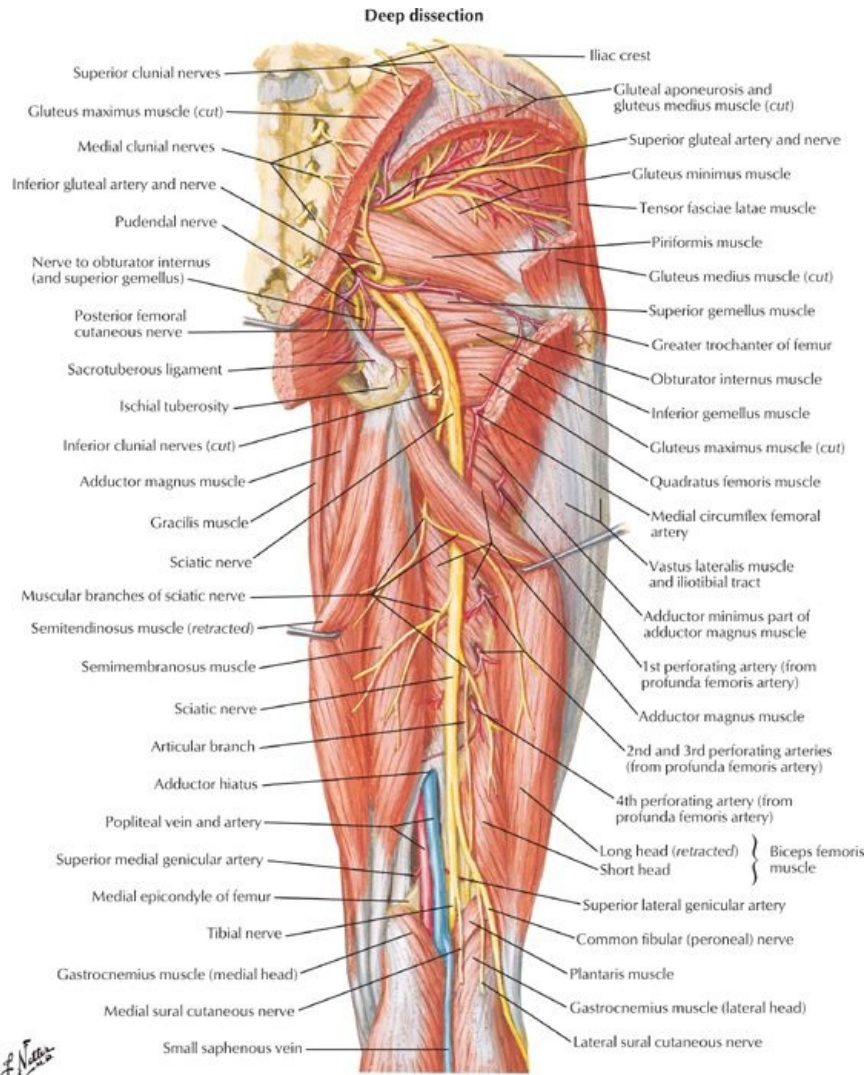
At the end of your study, you should be able to:

- Describe the arterial supply of the lower limb, distinguishing the arteries supplying each of the compartments of the thigh and leg
- Know the surface markings to locate the femoral artery and palpate the pulses of the popliteal, posterior tibial, and dorsalis pedis arteries
- Describe the venous drainage of the lower limb
- Describe the lymphatic drainage of the lower limb
- Know the nervous innervation to the compartments of the thigh and leg and recognize the course of the major nerves of the lower limb
- Understand the dermatome and myotome maps of the lower limb

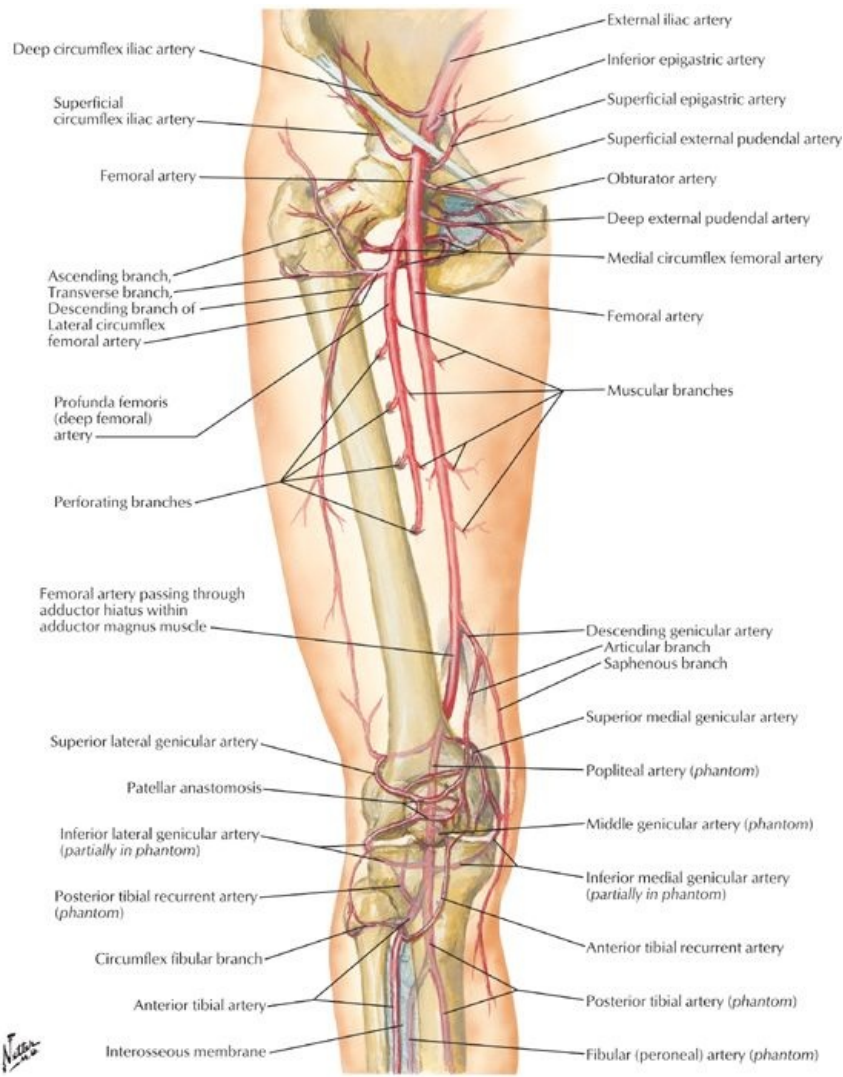
GUIDE

Lower Limb: Neurovasculature

Vascular Supply: Arteries



[Plate 490, Arteries and Nerves of Thigh: Posterior View]



[Plate 500, Arteries of Thigh and Knee: Schema]

page 270
page 271

- Femoral artery
 - Continuation of the external iliac artery
 - Main artery of lower limb
 - Palpable inferior to the midinguinal point, not at the midpoint of the inguinal ligament
 - Descends in femoral triangle on iliopsoas and pectineus, lateral to femoral vein
 - Enters adductor canal deep to sartorius and exits at adductor hiatus
- Profunda femoris (deep artery of thigh)
 - Main artery to the thigh
 - Largest branch of femoral
 - Arises from lateral aspect of femoral in femoral triangle
 - Supplies anterior and medial (adductor) compartments of the thigh
 - Supplies posterior compartment by perforating arteries
 - Gives off medial and lateral circumflex femoral arteries that supply the head of the femur and muscles of lateral thigh
- Obturator artery
 - Branch of the internal iliac artery (or may arise from the inferior epigastric)
 - Enters thigh through obturator foramen
 - Divides into anterior and posterior branches
 - Supplies adductor compartment of the thigh along with profunda femoris
- Popliteal artery
 - Continuation of the femoral artery (at adductor hiatus)
 - Palpable in the popliteal fossa (best felt when knee is flexed)
 - Gives off five genicular branches supplying articular capsule and ligaments of knee joint
 - Medial and lateral superior genicular
 - Middle genicular
 - Medial and lateral inferior genicular
 - Form anastomosis around knee joint
 - Bifurcates into anterior and posterior tibial arteries
- Anterior tibial artery
 - Smaller of two terminal branches of popliteal
 - Passes through gap in interosseous membrane

- Supplies muscles of anterior compartment of the leg
- Descends on interosseous membrane and becomes dorsalis pedis artery
- Posterior tibial artery
 - Larger of two terminal branches of popliteal
 - Supplies muscles of posterior compartment
 - Gives off fibular artery
 - Descends deep to soleus
 - Provides main blood supply to foot, after passing inferior to medial malleolus
 - Palpable behind the medial malleolus
 - Gives off nutrient artery to the tibia
- Circumflex fibular artery
 - Arises from origin of anterior or posterior tibial
 - Passes over neck of fibula to anastomosis around knee
- Fibular artery
 - Largest branch of posterior tibial
 - Supplies muscles of lateral compartment of the leg
 - Begins below tendinous arch of soleus
 - Gives off nutrient artery to the fibula
 - Pierces interosseous membrane to reach dorsum of foot
- Dorsalis pedis
 - Continuation of the anterior tibial artery
 - Palpable between the first and second metatarsal heads
 - Divides into plantar and arcuate arteries
 - Supplies muscles on dorsum of foot
 - Pierces first dorsal interosseous muscle as deep plantar artery of foot (plantar arterial arch)
- Medial plantar artery
 - Smaller of two terminal branches of posterior tibial artery
 - Supplies muscles of great toe, skin on medial side of sole
 - Gives off plantar digital arteries
- Lateral plantar artery
 - Larger than medial
 - Accompanies lateral plantar nerve
 - Arches medially across foot, beginning at base of fifth metatarsal as deep plantar arch
 - Gives off four plantar metatarsal arteries
 - Joins branches of medial plantar to form plantar digital arteries to toes

Vascular Supply: Veins

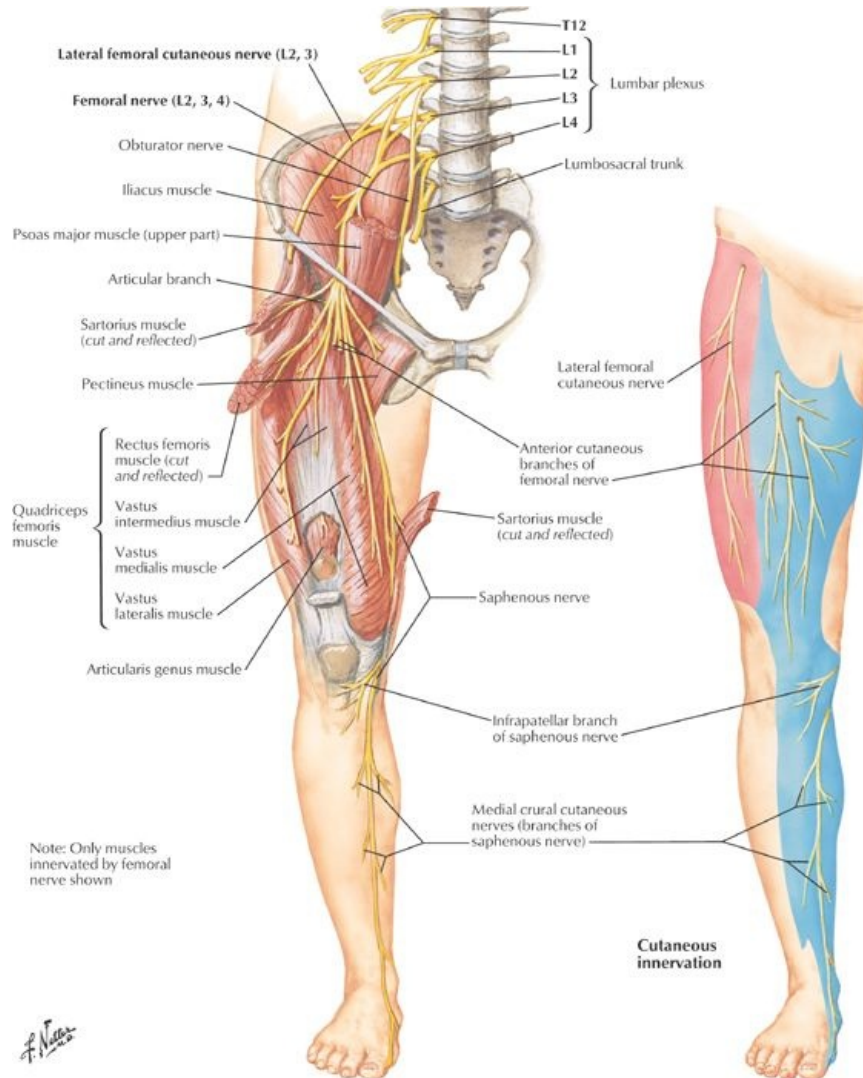
page 271
page 272

- Lower limb has superficial and deep venous systems with perforating veins communicating between them
- Veins have valves
- Veins of foot
 - Superficial
 - Metatarsal veins merge to form dorsal venous arch
 - Communicates with plantar arch
 - Both drain medially to great saphenous vein and laterally to small saphenous vein
 - Deep
 - Begin as dorsal digital and plantar digital veins
 - Merge to deep veins accompanying arteries in leg and thigh
- Superficial veins of leg and thigh
 - Great saphenous vein
 - Courses along medial side of dorsum of the foot
 - Passes in front of medial malleolus (*location for venous cut down for emergency IV access here*)
 - Anastomoses freely with small saphenous vein
 - Ascends medial side of leg, then posterior to the knee
 - Ascends along medial thigh to saphenous hiatus in fascia lata
 - Traverses hiatus to empty into femoral vein
 - Has many valves
 - Small saphenous vein
 - Runs behind the lateral malleolus
 - Ascends along lateral border of calcaneal tendon
 - Pierces the deep fascia
 - Ascends between heads of gastrocnemius
 - Empties into popliteal vein
 - Accompanied by the sural nerve
- Deep veins of leg and thigh
 - Accompany all major arteries (venae comitantes)
 - Are usually paired
 - Are variable and anastomose freely
 - Unite to form the popliteal vein and ascend as femoral vein
- Perforating veins
 - Penetrate deep fascia
 - Connect superficial and deep veins
 - Have valves

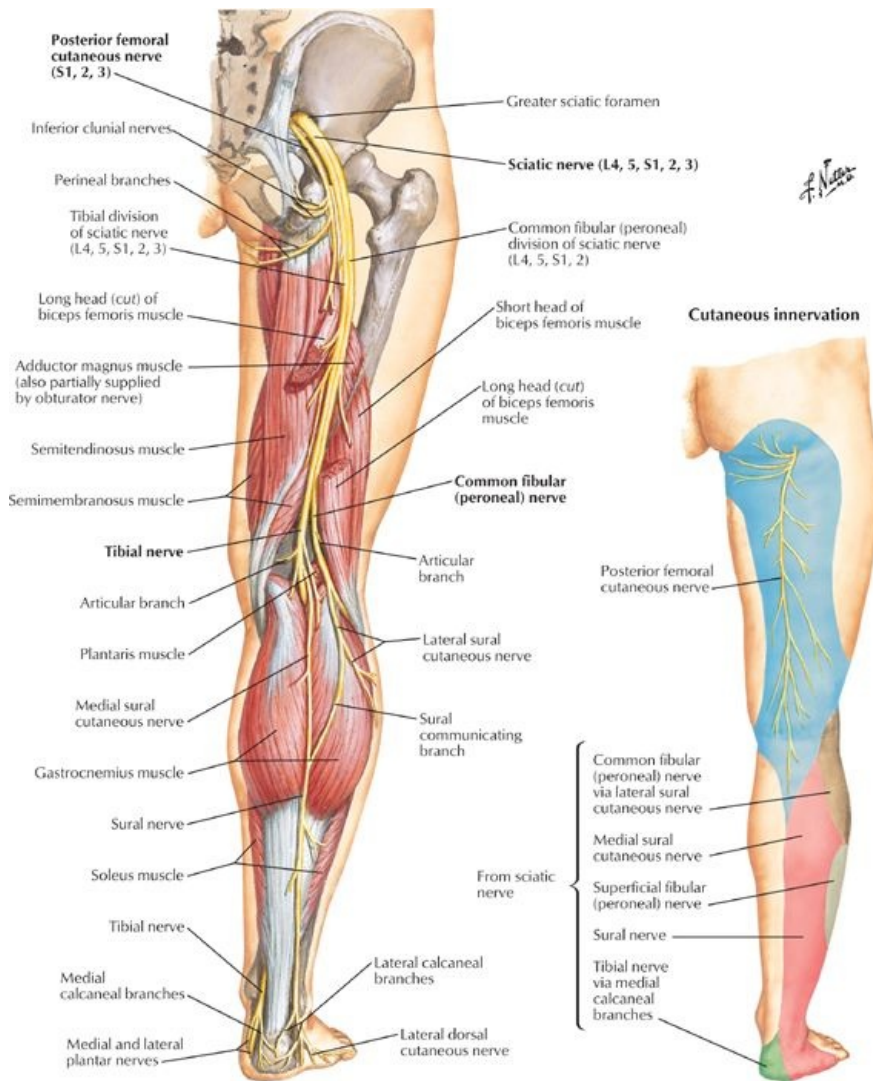
Lymphatics

- Superficial lymphatics follow the superficial veins
 - Lymphatics following the great saphenous drain into superficial inguinal nodes
 - Lymphatics following the small saphenous vein drain into popliteal nodes
- Deep lymphatics
 - Follow vasculature in the muscle compartments
 - Drain to deep inguinal nodes
- Popliteal nodes drain into the deep inguinal nodes

Nerves



[Plate 526, Femoral Nerve and Lateral Cutaneous Nerve of Thigh]



[Plate 528, Sciatic Nerve and Posterior Femoral Cutaneous Nerve]

page 272
page 273

- Cutaneous nerves
 - Subcostal nerve (T12) to skin anterior to greater trochanter
 - Iliohypogastric nerve (L1) to superior lateral buttock
 - Ilioinguinal (L1) to proximal and medial thigh
 - Genitofemoral nerve (L2-L3) to immediately inferior to middle inguinal ligament
 - Lateral femoral cutaneous ((L2-L3) to lateral and anterior thigh
 - Femoral nerve (L2-L4)
 - Via anterior femoral cutaneous branches to anterior and medial thigh
 - Via saphenous nerve to medial side of leg and foot
 - Obturator nerve-branch to anterior, medial and posterior proximal thigh
 - Posterior femoral cutaneous nerve-to posterior thigh and popliteal region
 - Sciatic nerve
 - Supplies foot and most of leg
 - Via sural, common, superficial, and deep fibular nerves
 - Cluneal nerves (superior middle and inferior)-buttock
- Nerves to muscles of lower limb from lumbosacral plexus
- Nerves in the gluteal region
 - Superior gluteal nerve (L4-S1)
 - Emerges superior to piriformis
 - Supplies gluteus medius, gluteus minimus and tensor fasciae latae
 - Inferior gluteal nerve (L5-S2)
 - Inferior to piriformis
 - Supplies gluteus maximus
 - Nerve to quadratus femoris (L4-S1): also supplies inferior gemellus
 - Pudendal nerve (S2-S4): supplies the perineum (*not structures in the gluteal region*)
 - Nerve to obturator internus (L5-S2)
- Nerves to anterior and lateral thigh
 - Femoral nerve (L2-L4)
 - Enters thigh lateral and deep to femoral artery
 - Supplies the anterior compartment of the thigh

- Obturator nerve (L2-L4)
 - Enters thigh through obturator foramen and divides into anterior and posterior branches
 - Supplies medial (adductor) compartment of thigh
- Nerves of posterior thigh
 - Sciatic nerve (L5-S2)
 - Enters gluteal region from pelvis through greater sciatic foramen
 - Emerges inferior to the piriformis muscle
 - Supplies no structures in the gluteal region
 - Supplies posterior thigh muscles
 - Bifurcates in lower third of thigh into tibial and common fibular nerves
 - Via tibial and common fibular nerves, supplies all leg and foot muscles
- Nerves of leg
 - Tibial nerve
 - Supplies the posterior compartment of leg
 - Ends by dividing into medial and lateral planter nerves
 - Common fibular nerve
 - Wraps around fibular head
 - Divides into deep and superficial peroneal nerves
 - Deep fibular nerve supplies anterior compartment of leg
 - Superficial fibular nerve supplies lateral compartment of leg
- Nerves of foot
 - Medial plantar to 3½ muscles of plantar foot
 - Lateral plantar to remaining muscle of plantar foot

Dermatomes

Myotomes

- A group of muscles supplied by fibers from a single spinal nerve or a discrete group of spinal nerves is called a myotome

Myotomes of the Lower Limb

		L2	L3	L4	L5	S1	S2
Hip	Flexion	X	X				
	Extension			X	X		
Knee	Extension		X	X			
	Flexion				X	X	
Ankle	Dorsiflexion			X	X		
	Plantarflexion					X	X
Foot	Inversion			X	X		
	Eversion				X	X	
	Intrinsic						X

FACTS & HINTS

HIGH-YIELD FACTS

Clinical Points

Chronic Arterial Occlusive Disease

- Caused by atherosclerosis
- In the lower limb, most commonly affects femoral artery as it passes through adductor canal
- Symptoms of intermittent claudication (pain in a muscle group because of poor blood supply) brought on by exertion in the early phase; may progress to pain at rest
- Ischemic ulcers can also develop
- Patients with advanced disease require vascular surgical intervention with bypass or endarterectomy

Foot Drop

- Injury to the common fibular nerve can result in loss of eversion and dorsiflexion of the foot
- Foot drops and toes drag on the ground when walking unless high-stepping gait is employed
- Variable amount of sensation also lost on the anterolateral aspect of the leg and dorsum of foot
- Nerve is vulnerable owing to superficial course as it wraps around fibular neck
- Nerve may be severed during fracture of fibula or dislocation of knee joint

Meralgia Paresthetica (Gunslinger's Neuralgia)

- Compression of the lateral cutaneous nerve of the thigh against the anterior superior iliac spine
- Causes a stinging or burning sensation in the anterolateral thigh
- Was caused by low-riding gun belt in the Old West

MNEMONICS

Memory Aids

Nerves of the leg and their functions:	
FED:	(Fibular nerve Everts and Dorsiflexes the foot)
TIP:	(Tibial nerve Inverts and Plantarflexes the foot)